

SCIENTIFIC WORKS
SERIES C. VETERINARY MEDICINE
VOLUME LXV (1), 2019

UNIVERSITY OF AGRONOMIC SCIENCES
AND VETERINARY MEDICINE OF BUCHAREST
FACULTY OF VETERINARY MEDICINE

SCIENTIFIC WORKS
SERIES C
VETERINARY MEDICINE

VOLUME LXV (1)

2019
BUCHAREST

SCIENTIFIC COMMITTEE

- Sarah BAILLIE - Bristol Veterinary School, University of Bristol, United Kingdom
- Stelian BĂRĂITĂREANU - University of Agronomic Sciences and Veterinary Medicine of Bucharest, Romania
- Florica BĂRBUCEANU - Institute for Diagnosis and Animal Health, University of Agronomic Sciences and Veterinary Medicine of Bucharest, Romania
- Laurențiu-George BENGA - Veterinary Laboratory of the Central Unit for Animal Research and Welfare Affairs at the University Hospital, Heinrich Heine University Dusseldorf, Germany
- Antonello BUFALARI - Department of Veterinary Medicine, University of Perugia, Italy
- Cristin COMAN - “Cantacuzino” National Medico-Military Institute for Research and Development
- Emilia CIOBOTARU-PÎRVU - Faculty of Veterinary Medicine, USAMV Bucharest, Romania
- Mario CODREANU - Faculty of Veterinary Medicine, USAMV Bucharest, Romania
- Romeo CRISTINA- Faculty of Veterinary Medicine, BUASVM Timisoara, Romania
- Aurel DAMIAN - Faculty of Veterinary Medicine, UASVM Cluj-Napoca, Romania
- Nicolae DOJANĂ - Faculty of Veterinary Medicine, USAMV Bucharest, Romania
- Florin FURNARIS - Faculty of Veterinary Medicine, USAMV Bucharest, Romania
- Ioan Ștefan GROZA - Faculty of Veterinary Medicine, UASVM Cluj-Napoca, Romania
- Viorel HERMAN - Faculty of Veterinary Medicine, BUASVM Timișoara, Romania
- Cornel IGNA- Faculty of Veterinary Medicine, BUASVM Timisoara, Romania
- Mariana IONIȚĂ - Faculty of Veterinary Medicine, USAMV Bucharest, Romania
- Anja KIPAR - Institute of Veterinary Pathology, Vetsuisse Faculty Zurich, University of Zurich
- Leonardo LEONARDI - University of Perugia, Italy
- Dumitru MILITARU - Academy of Agricultural and Forestry Sciences, „Gheorghe Ionescu-Șișești“, Bucharest, Romania
- Manuella MILITARU - Faculty of Veterinary Medicine, USAMV Bucharest, Romania
- Ioan Liviu MITREA - Faculty of Veterinary Medicine, USAMV Bucharest, Romania
- Liviu MIRON - Faculty of Veterinary Medicine, UASVM Iași, Romania
- Lucia Carmen TRINCĂ - Faculty of Veterinary Medicine, UASVM Iași, Romania
- Aurel MUSTE - Faculty of Veterinary Medicine, UASVM Cluj-Napoca, Romania
- Laurenț OGNAN - Faculty of Veterinary Medicine, UASVM Cluj-Napoca, Romania
- Ionel PAPUC - Faculty of Veterinary Medicine, UASVM Cluj-Napoca, Romania
- Aneta POP - Faculty of Veterinary Medicine, USAMV Bucharest, Romania
- Gabriel PREDOI - Faculty of Veterinary Medicine, USAMV Bucharest, Romania
- Ștefania Mariana RAITA - Faculty of Veterinary Medicine, USAMV Bucharest, Romania
- Marina SPÎNU - Faculty of Veterinary Medicine, UASVM Cluj-Napoca, Romania
- Gheorghe SOLCAN - Faculty of Veterinary Medicine, UASVM Iași, Romania
- Dana TĂPĂLOAGĂ - Faculty of Veterinary Medicine, USAMV Bucharest, Romania

EDITORIAL BOARD

General Editor: Prof. D.V.M. PhD. Gabriel PREDOI

Executive Editor: Prof. PhD. Aneta POP

Members: Sarah BAILLIE, Emilia CIOBOTARU-PÎRVU,
Nicolae DOJANĂ, Mariana IONIȚĂ, Horst Erich KÖNIG, Ioan Liviu MITREA,
Aneta POP, Dana TĂPĂLOAGĂ, Constantin VLĂGIOIU

Secretariat: Florin IORDACHE, Gheorghe Valentin GORAN

PUBLISHERS:

**University of Agronomic Sciences and Veterinary Medicine of Bucharest, Romania -
Faculty of Veterinary Medicine**

Address: 105 Splaiul Independentei, District 5, Zip code 050097, Bucharest, Romania

Phone: + 40 21 318 04 69,

E-mail: veterinarymedicinejournal@usamv.ro, Webpage: www.fmvb.ro

CERES Publishing House

Address: 29 Oastei Street, District 1, Bucharest, Romania

Phone: + 40 21 317 90 23, E-mail: edituraceres@yahoo.com, Webpage: www.editura-ceres.ro

Copyright 2019

To be cited: Scientific Works. Series C. Veterinary Medicine, Vol. LXV (1), 2019

*The publishers are not responsible for the opinions published in the Volume.
They represent the authors' point of view.*

ISSN 2065-1295, ISSN 2343-9394 (CD-ROM), ISSN 2067-3663 (Online), ISSN-L 2065-1295

International Database Indexing:

Index Copernicus; CABI; Google Scholar; Scipio; OCLC; PNB (Polish Scholarly Bibliography);
Cite Factor; Research Bible; Universal Impact Factor

SUMMARY

FUNDAMENTAL SCIENCES

THE INFLUENCE OF THE BIOCHEMICAL COMPOSITION OF THE BACTERIAL CELL WALL ON THE ANTIBACTERIAL PROPERTY OF MONOLAYER GRAPHENE - Gabriel GAJAILA, Iuliana GAJAILA	11
MORPHOTOPOGRAPHIC ASPECTS OF CERTAIN PELVIC LIMB LYMPH NODES IN FERRETS - Anca ȘEICARU	14

CLINICAL SCIENCES

ALUMINUM LEVELS IN CATS AND DOGS - Emanuela BADEA, Gheorghe Valentin GORAN, Victor CRIVINEANU	21
PRELIMINARY CLINICAL EVALUATION OF MESENCHYMAL STROMAL CELL TREATMENTS FOR UNUNITED ANCORNEAL PROCESS AND LEGG-CALVE'-PERTHES DISEASE IN DOGS - Antonello BUFALARI, Alberto CROVACE, Antonio DI MEO, Vasilica-Flory PETRESCU, Alexandra PETEOACA, Luisa PASCUCCI, Gabriele SCATTINI, Beatrice DEL SAL, Giulia MORETTI	24
PRELIMINARY RESEARCH REGARDING CLINICAL AND MORFOLOGICAL FINDINGS IN NEGLECTED DOGS - Elena CÂRCIUMARU, Emilia CIOBOTARU-PÎRVU	31
STUDY ON CHANGES IN HAEMATOLOGICAL PARAMETERS FOLLOWING ADMINISTRATION OF NSAIDs IN DOGS - Ionuț Răzvan DOBRE, Diana Mihaela ALEXANDRU, Maria CRIVINEANU	37
INVESTIGATIONS REGARDING THE PARTICULARITIES OF NON-SPECIFIC RESISTANCE AT NEONATAL CALVES - Rita GOLBAN	42
DORSAL DISPLACEMENT OF THE SCAPULA IN A CAT – CASE REPORT - Cornel IGNA, Roxana DASCALU, Bogdan SICOE, Cristian ZAHA, Larisa SCHUSZLER	46
CLINICAL AND THERAPEUTICAL APPROACH TO PROTEIN-LOSING NEPHROPATHY IN DOGS - A REVIEW - Roxana-Mariana IGNĂTESCU (ȚÎMPĂU), Ana-Maria GOANȚĂ, Ana-Maria BĂDULESCU, Daniela BRĂSLAȘU, Lucian IONIȚĂ	51
RADIOGRAPHIC AND COMPUTED TOMOGRAPHY FINDINGS IN DOGS WITH FRAGMENTED MEDIAL CORONOID PROCESS - Andreea ISTRATE, Alexandra PETEOACA, Radu CONSTANTINESCU, Giovanni ANGELI, Andrei TANASE	60
RADIOGRAPHIC RETROSPECTIVE STUDY OF THORACIC CAVITY ALTERATIONS IN DOGS AND CATS WITH RESPIRATORY DISEASES - Alexandru Gabriel NEAGU, Mihai SĂVESCU, Giovanni ANGELI, Niculae TUDOR, Constantin VLĂGIOIU	66
THERAPEUTIC APPROACH IN MANAGING DEGLOVING INJURIES OF THE FRONT LIMBS IN A DOG - A CASE REPORT - Alexandra PETEOACA, Andreea ISTRATE, Ana GOANTA, Gina GIRDAN, Alina STEFANESCU, Andrei TANASE	70

REVERSAL OF CARDIAC PATHOLOGY BY ECHOCARDIOGRAPHY IN A DOG WITH SEVERE PULMONARY HYPERTENSION SECONDARY TO HEARTWORM DISEASE - CASE REPORT - Alice RADULESCU, Beatrice CRISTESCU, Pamela HARRIGAN, Lucian IONITA	79
SURGICAL TREATMENT OF A TRAUMATIC DIAPHRAGMATIC HERNIA IN A CAT USING STRATAFIX™ BARBED SUTURE: CASE REPORT - Bogdan SICOE, Roxana DASCĂLU, Larisa SCHÜSZLER, Daniel BUMB, Cristian ZAHA, Cornel IGNA	89
HEMILAMINECTOMY FOR T11-T12 MEDULLAR COMPRESSION - PERIANAESTHETIC MANAGEMENT OF A GERIATRIC DOG - Ruxandra TUDOR, Andra DEGAN, Alexandru Gabriel NEAGU, Luigi CARSTINOIU, Gabriel PREDOI	94
ENCEPHALITIS: CLINICAL APPROACH TO DIAGNOSIS AND A CASE SERIES REPORT - Raluca Mihaela TURBATU, Cristina FERNOAGĂ, Nicolae TUDOR, Constantin VLĂGIOIU	96
TREATMENT OF THE EXUBERANT GRANULATION TISSUE IN HORSE USING ELASTIC LIGATURE: CASE REPORT - Cristian ZAHA, Raluca DASCALU, Larisa SCHUSZLER, Bogdan SICOE, Daniel BUMB, Cornel IGNA	101

ANIMAL PRODUCTION, PUBLIC HEALTH AND FOOD QUALITY CONTROL

FUNCTIONAL SET UP STAGES OF AQUAPONIC EXPERIMENTAL MODEL - Elena Camelia GAVRILĂ, Neculai PATRICHE, Marian BOGOESCU, Dorin SORA, Mădălina DOLTU, Maria CRIVINEANU	109
OBSERVATIONS ON GROWTH PERFORMANCES OF RAINBOW CONSUMPTION TROUT - Andrei MARMANDIU, Andreea TRONARU, Ion CUSTURĂ, Ion RĂDUCUȚĂ, Ileana PĂUNESCU	115
A STUDY CONCERNING QUALITY ASSESSMENT AND PROCESSING PARTICULARITIES IN CERTAIN DAIRY PRODUCTS - Diana Oana OPREA, Carmen Daniela PETCU, Emilia CIOBOTARU-PÎRVU	121
A STUDY ON SENSORIAL ANALYSIS AND THE ASSESSMENT OF THE NUTRITIVE VALUES OF BREAD ASSORTMENTS - Carmen Daniela PETCU, Oana Diana OPREA, Laura STANCIU, Oana Mărgărita GHIMPEȚEANU	127

EXPERIMENTAL MEDICINE

EVALUATION OF ALTERNATIVE ROUTES OF INTRAVENOUS ADMINISTRATION TO THE METHOD OF ADMINISTRATION SUBSTANCES BY PENILE VEIN IN THE <i>IN VIVO</i> ANTIGENICITY TEST IN GUINEA PIGS - Cristin COMAN, Teodoru SOARE, Diana ISTRATE, Andrei STOIAN, Diana ANCUȚA, Jasmina MANOLESCU	137
ANESTHESIA COMPLICATIONS RELATED TO SWINE EXPERIMENTAL INVASIVE SURGICAL PROCEDURES – Ruxandra COSTEA, Ruxandra TUDOR, Andra DEGAN, Gina GÎRDAN	145
RESEARCH REGARDING THE EFFECT OF SOME SYNTHETIC GLUCOCORTICOID HORMONES ON LEUKOCYTES, IN RATS - Gavrilă ZAGRAI, Cristian BELU, Cerasela VASILESCU, Diana LICSandRU, Aurel DAMIAN, Ana Maria ZAGRAI (MAIEREAN), Livia PĂUN	149

FUNDAMENTAL SCIENCES

THE INFLUENCE OF THE BIOCHEMICAL COMPOSITION OF THE BACTERIAL CELL WALL ON THE ANTIBACTERIAL PROPERTY OF MONOLAYER GRAPHENE

Gabriel GAJAILA, Iuliana GAJAILA

University of Agronomic Sciences and Veterinary Medicine of Bucharest,
Faculty of Veterinary Medicine, 105 Splaiul Independentei, District 5, Bucharest, Romania

Corresponding author email: imunogg@gmail.com

Abstract

Graphene is an allotrope of carbon consisting of a single tightly packed layer of sp^2 carbon atoms arranged in a hexagonal lattice. Graphene has unique properties that could revolutionize different areas, including biology, biomedical science, environmental agriculture and biotechnology. Many studies are aimed mainly at antibacterial effect of graphene. Antibacterial properties of graphene are manifested by directly interacting with the cell membrane. In this study we aim to investigate the aspects of the role of the biochemical composition of the bacterial cell wall in the manifestation of the antibacterial activity of the monolayer graphene on metallic and non-metallic substrates. Antibacterial activity was tested on Gram-positive and Gram-negative bacteria via cell-viability test. The differences in structure and composition of the Gram-positive and Gram-negative cell wall induce different interactions with monolayer graphene. At the same time, the different substrate for the graphene film significantly influences its antibacterial properties. Our observations from this study provide new insights for future studies.

Key words: antimicrobial activity, bacterial cell wall, graphene.

INTRODUCTION

A relatively recent area of research focuses on the study of the interactions between nanomaterials and cells. Over the past decade research into the properties and uses of graphene has rapidly expanded. Graphene is a two-dimensional ultra-thin nanomaterial composed only of hybridized- sp^2 carbon atoms, arranged in a hexagonal structure, similar to that of a honeycomb. Graphene displays specific and unique physico-chemical properties which vary significantly to the material graphite, particularly in terms of electron mobility. These particular properties determine complex interactions with cells (Wolf, 2014). Many researches are aimed mainly at antibacterial effect of graphene, its ability to inhibit bacterial proliferation on its surface, even when the bacteria have all the conditions for optimal growth (Li Jinhua *et al.*, 2014; Kurantowicz *et al.*, 2015; Hegab *et al.*, 2016). The factors influencing antibacterial effect of graphene are still not fully understood. The biochemical composition of bacterial cell wall, surface charge and hydrophobicity of non-polar molecules are factors that lead the

occurrence specific and non-specific interaction between the bacterial cell and graphene (Y. Luan, 2018).

The bacterial cell wall contains numerous complex biological molecules. The distinction between Gram-positive and Gram-negative bacteria is given by their cell walls chemical composition. In both Gram-negative and Gram-positive bacteria the major components of the cell wall are peptidoglycans, macromolecules composed of sugars and amino acids that provide structural strength and confer the characteristic cell shape (Hogan *et al.*, 2010). The cell wall peptidoglycans of Gram-positive bacteria contain polysaccharide chains highly cross-linked with peptides, while the cell wall peptidoglycans of Gram-negative bacteria have polysaccharide chains partially cross-linked with peptides.

The peptidoglycan layer is thicker in Gram-positive bacteria (20 to 80 nm) and help to support the cell membrane. The cell walls of Gram positive bacteria also contain chains of teichoic and lipoteichoic acids, polysaccharides peptidoglycolipids, covalently attached to the peptidoglycan (Brown *et al.*, 2013). Wall teichoic acids are anionic glycopolymers that

can account for as much as 60 % of the total cell wall mass in Gram-positive bacteria. They assist in cellular integrity and play a role in cell division and Gram-positive bacterial physiology (Swoboda *et al.*, 2009). The peptidoglycan layer of Gram-negative cells is thinner (1 to 10 nm). But unlike in Gram-positive bacteria, Gram-negative bacteria have an outer membrane layer that is external to the peptidoglycan cell wall. The outer membrane contains a lipopolysaccharide component, a large glycolipid complex that protects bacteria. The lipopolysaccharide molecules are characteristic of Gram-negative bacteria and are not found in Gram-positive bacteria (Coleman *et al.*, 2014).

In this context, we have been following the link between the biochemical composition of the bacterial cell wall and the antibacterial activity of monolayer graphene. The antibacterial activity of graphene against both Gram-positive (*Staphylococcus aureus*) and Gram-negative (*Escherichia coli*) bacterial strains was compared.

MATERIALS AND METHODS

Two types of monolayer graphene films on different substrates were synthesized by chemical vapor deposition (CVD): graphene on copper (G-Cu) and graphene on silicon (G-Si), foils with a surface area of 2 cm² and thickness of 35 μm. We used these monolayer graphene films to evaluate their antibacterial activity against both Gram-negative (*Escherichia coli*) and Gram-positive (*Staphylococcus aureus*) bacteria.

The antibacterial activity was done by cell-viability test. In brief, the pure cultures of organisms were subcultured in nutrient agar substrate, incubated for 24 hours at 35°C ± 2°C and brought up by dilution according to the 0.5 McFarland standards to approximately 10⁸ colony-forming units (CFU)/ml.

Each bacterial suspension was placed upon graphene sheets. After overnight incubation at 35°C ± 2°C each bacterial suspension previously overlaid with graphene is removed from the graphene surface, recultivated in solid growth media and evaluation of bacterial survivability immediately. Viable bacterial colonies were counted and recorded by the

naked eye by cell-viability test (CFU plate counting). The experiments were carried out in triplicate, and averages were reported.

RESULTS AND DISCUSSIONS

The observed antibacterial activity was found to be bacterial cell wall dependent (his biochemical composition) and types of monolayer graphene. Colony forming units (CFU) counting was used to assess the bactericidal effect of both types of monolayer graphene. It was demonstrated that both graphene matrices effectively inhibit *S. aureus* and *E. coli* cell growth with viability loss. Antibacterial effects of the graphene sheets on copper (G-Cu) and silicon (G-Si) are significantly different for the Gram-positive (*S. aureus*) and Gram-negative (*E. coli*) bacteria. To explain the antibacterial mode of action of graphene on different substrates we suggest production of reactive oxygen species, oxidative stress and damage to bacterial cell wall integrity. The cell membranes are severely damaged and even are missing their cytoplasm entirely. The *Staphylococcus aureus* strain exhibited significant reduction ratio of bacterial CFU, compared to viability of *Escherichia coli* strain (Figure 1).

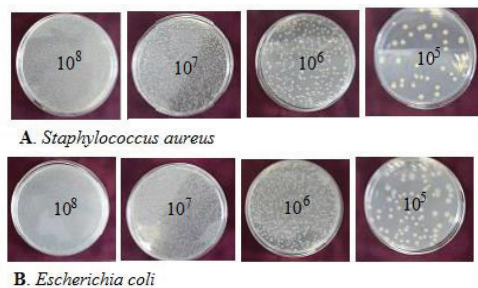


Figure 1 Viable bacterial cell of *Staphylococcus aureus* (A) and *Escherichia coli* (B) on graphene (G-Si) for various concentrations of bacterial suspension

The outer membrane of Gram-negative bacteria acts as a permeability barrier and is partly responsible for this differential antibacterial activity. The destructive effect of graphene on the bacterial cell wall is induced by a lower surface phospholipid density which results in a loss of cell membrane integrity. Furthermore, the destructive effect of graphene coated surfaces is related and to the electronic

properties of the substrate. The monolayer graphene on copper substrate has been found to

be a much more efficient as inhibitor of the bacterial multiplication. (Table 1).

Table 1. Bacterial response (CFU) for *Staphylococcus aureus* and *Escherichia coli* strains after being incubated on the different monolayer graphene

Monolayer graphene	<i>Staphylococcus aureus</i>			<i>Escherichia coli</i>		
	10 ⁷ CFU/mL	10 ⁶ CFU/mL	10 ⁵ CFU/mL	10 ⁷ CFU/mL	10 ⁶ CFU/mL	10 ⁵ CFU/mL
G-Cu	56 ± 3 CFU	21 ± 4 CFU	2 ± 1 CFU	82 ± 2 CFU	46 ± 2 CFU	12 ± 2 CFU
G-Si	110 ± 4 CFU	47 ± 2 CFU	18 ± 3 CFU	202 ± 2 CFU	61 ± 3 CFU	22 ± 2 CFU

Graphene-on-substrate junctions can act as electrons pump that by interfering with membrane receptors and with bacterial electron transport away from the microbial membrane, thus producing oxidative stress in the membrane. For *Staphylococcus aureus* strain the teichoic acids in the bacterial cell wall composition form a dense network of negative charges on Gram-positive cell surfaces, a gradient of ions which amplifies and accelerates the osmotic pressure change between the inside and outside of the cell, oxidative stress induced by graphene.

For *Escherichia coli* strain (Gram-negative bacteria) the outer membrane and the thin layer of peptidoglycan stabilizes the inner membrane such that withstand the high osmotic pressures within the cell and oxidative stress induced by graphene.

CONCLUSIONS

The graphene sheet on copper substrate may have antibacterial effect by reducing or inhibiting the viability of certain bacteria that are in direct contact with it, depending on the specific biochemical composition of the bacterial cell wall. Losing viability may be an effect of an oxidative stress generated by conductive character of graphene. The antibacterial properties of monolayer graphene have been shown to be lower for *Escherichia*

coli strain (Gram-negative), due to cell wall biochemical composition and structure, more complex than that of the *Staphylococcus aureus* strain (Gram-positive).

REFERENCES

- Brown, S., Santa Maria, J., Walker, S. (2013). Wall Teichoic Acids of Gram-Positive Bacteria. *Annual Review of Microbiology*, 67:313-336
- Coleman, J.P., Smith, C. J. (2014). Structure and Composition of Microbes. *Reference Module in Biomedical Sciences*
- Hegab, H.M., El-Mekawy, A., Mulcahy, D., Saint, C.P. (2016). The controversial antibacterial activity of graphene-based materials. *Carbon*, 105: 362-376.
- Hogan, M.C. (2010). Bacteria. *Encyclopedia of Earth*. Eds. Sidney Draggan and C.J.Cleveland, National Council for Science and the Environment, Washington
- Kurantowicz N, Sawosz E, Jaworski S, Kutwin M, Strojny B. (2015). Interaction of graphene family materials with *Listeria monocytogenes* and *Salmonella enterica*. *Nanoscale Res Lett*, 10: 23.
- Li J, Wang G, Zhu H, Zhang M, Zheng X. (2014). Antibacterial activity of large-area monolayer film manipulated by charge transfer. *Scientific Reports*, 4: 4359.
- Luan, Y., Liu, S., Busscher, H.J. (2018). Bacterial interactions with nanostructured surfaces. *Current Opinion in Colloid & Interface Science*. 38:170-189
- Swoboda, J. G., Campbell, J, Meredith, T.C., Walker, S. (2009). Wall Teichoic Acid Function, Biosynthesis, and Inhibition. *ChemBioChem*, 11(1): 35–45
- Wolf, E. L. (2014). Applications of Graphene: An Overview. *Springer Briefs in Materials*

MORPHOTOPOGRAPHIC ASPECTS OF CERTAIN PELVIC LIMB LYMPH NODES IN FERRETS

Anca ȘEICARU

University of Agronomic Sciences and Veterinary Medicine of Bucharest, Faculty of Veterinary Medicine, 105 Splaiul Independenței, District 5, Bucharest, Romania

Corresponding author email: ancaseicaru@gmail.com

Abstract

Data regarding the pelvic limb lymph centres in ferrets is quite scarce in the literature, so the aim of this paper is to present the morphotopographic relationship between the lymph nodes and the muscles of the pelvic limb, given their adjacent position. The muscles of the pelvic limb are well developed. The medium gluteus is very powerful, though it lacks its lumbar portion, and it clings to the accessory gluteus muscle. The long digital extensor muscle is covered by the cranial tibial muscle. The fat in the inguinal region forms an adipose pedicle that embeds superficial inguinal lymph nodes. The superficial inguinal lymph nodes are represented by two structures located along the epigastric caudal artery. In literature, inguinal lymph nodes are described as inconstant, but we were able to identify them in all three examined bodies. The popliteal lymph centre is represented by a single lymph node with a globular appearance lying in the popliteal fossa. In the ferret, the lymph nodes have considerable dimensions.

Key words: ferret, pelvic limb, lymph centers.

INTRODUCTION

The ferret (*Mustela putorius*) is used for its fur, for research purposes, as a pet, as well a game animal (Hrițcu et al., 2000).

This carnivorous mammal belongs to the *Mustelidae* Family, *Mammalia* Class, *Carnivora* Order, *Mustela* Genus, *putorius* species.

It is generally assumed that the domesticated ferret is an albino breed derived from the wild polecat (*Putorius foetidus*), but it differs from the latter principally in the yellowish-white colour of its fur and the pink-red colour of its eyes.

This is commonly known as the “English” ferret.

During the past 12 - 13 years, the ferret has become increasingly important as a laboratory animal, particularly for virus research. Since it was first shown by Dunkin and Laidlaw to be susceptible to canine distemper, it has been used to great advantage in the study of several other virus infections (Dunkin et al., 1926).

Ferrets are also subject to abscesses, which occur in the neck region and often involve the salivary glands.

A variety of organisms have been isolated from these, the most common being *Staphylococcus*

aureus. Some researches presumed that it originates from the feed.

Several species of internal parasites may find the ferret a suitable host.

As parasitic infections in this animal are rather uncommon, and even rare, space and time will not be given to their description (Mönning, 1934).

Scabies sometimes appears on the tail and over the back.

Studying the lymph centers of this species is important, in order to guide practicing veterinarians, laboratory researchers as well as those who wish to specialise in the pathology of this species (Paștea, 1979; Predoi, 1999).

The comparative newness of the species as a laboratory animal, and its limited use in this respect, explain, perhaps, why there exists a paucity of data with regard to its anatomy, physiology, endocrinology, and nutritive requirements.

It is hoped that this report will stimulate further investigations along these lines (Coțofan et al., 2003; Paștea, 1978; Predoi et al., 2001).

These animals are used in long-line cable transport by NASA in the Propulsion Laboratory, but also for testing in research laboratories for pharmaceutical products in medical investigations

MATERIALS AND METHODS

Three adult corpses from animals with no anatomico-pathological changes and without any sign of any disease were used.

Used materials:

- sanitary alcohol
- 2 ml sterile syringes
- ink substance 40%
- curved scissors
- scalpel

The method for identifying the lymphatic structures was the injection of a coloured substance - China ink dye 40%.

The dye was filtered through filter paper.

The filtrate was diluted 1/1 with physiological saline solution.

The areas of choice for injecting the colouring substance were in the plantar regions. The colorant dose used for injection was 0.3 ml.

Stratigraphic and regional dissections were performed up to the limit of visibility, while for more detailed investigations and photographs SMZ-Nikon stereomicroscope was used.

After removing the skin, the muscles, arteries and veins were dissected, revealing the lymph centres and the lymphatic vessels, preserving their relations with the adjacent formations.

The homologation of the formations was made according to *Nomina Anatomica Veterinaria* 2017.

RESULTS AND DISCUSSIONS

Due to the close relationship between lymph centers and muscles, a brief presentation of the pelvic limb muscles which form the elongated muscle mass of the hips and thigh region in ferret is considered necessary.

The superficial gluteus muscle is small, inserts on the sacrum and consists of a single muscular tummy. Medium gluteus muscle is very well developed. It does not have a lumbar portion, is attached to the accessory gluteus muscle, and their separation can only be done at the tendons level. The accessory gluteus muscle originates on the ventral edge of the iliac palate and is inserted onto the trochanteric crest. The deep gluteus muscle has a triangular pyramid shape.

The deep muscles of the basin include the outer obturator muscle that is well developed.

The femoral quadriceps muscle is well developed and merges with the large round muscle that is joined to the articular capsule.

The cranial abductor muscle of the shank is placed between the superficial gluteus muscle and the femoral biceps muscle.

The femoral biceps muscle consists of a cranial portion, that originates from the ischial tuberosity, and a caudal portion that is longer than the previous one and originates from the sacrotuberous ligament, the ischial tuberosity and the base of the tail (Fig. 1).

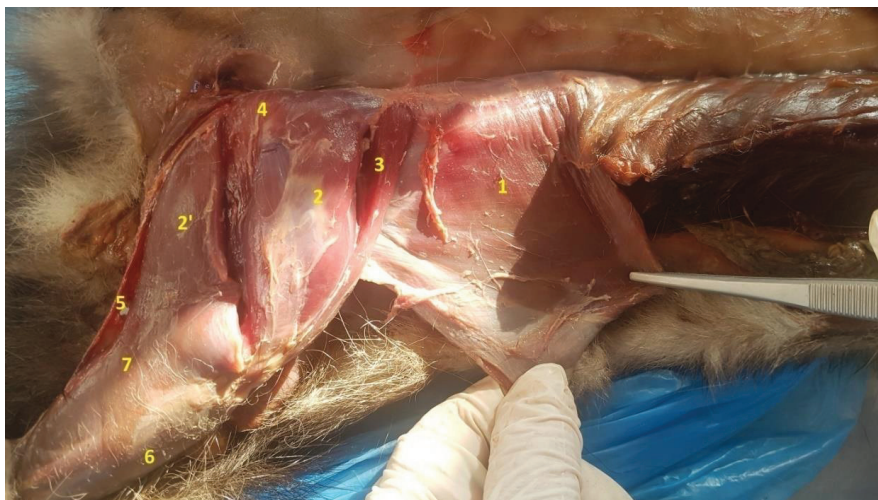


Fig. 1. Pelvic limb muscles (original):

- 1 - External oblique muscle of the abdomen; 2, 2' -Femoral biceps muscle; 3 - Fascia lata tensor muscle; 4 - Medium gluteus muscle; 5 - Semitendinosus muscle; 6 - Long fibular muscle; 7 - Gastrocnemius lateral muscle

Semitendinosum muscle is inserted on the medial face of the tibia. It originates on the coccygian fascia, the sacro-tuberous ligament and the ischial tuberosity.

The semimembranosus muscle consists of a cranial well developed portion having the insertion on the femur and a smaller caudal portion with insertion on the medial condyle of the tibia.

The gracilis muscle is small.

The sartorius muscle participates in the formation of the cranial form of the thigh due to its massive muscular development. Its origin is on both the ventro-caudal and the ventro-cranial iliac spine, medial to the insertion of the tensor muscle of the fascia lata. A portion of its fibers merge with the gracilis muscle and inserts onto the tibia, and another small portion of the fibers stop on the patella. The pectineus muscle is inserted halfway to the caudal face of the femur and has a fusiform shape

The short adductor muscle is specifically outlined, while the long adductor and large adductor muscles form a common muscle mass.

The tibialis cranial muscle is highly developed, has a superficial position and its distal tendon is inserted onto the metatarses I and II and on the small cuneiform.

The long digital extensor muscle is almost entirely covered by the tibialis cranial muscle. The long extensor muscle of the thumb is thin. It is inserted at the metatarso-phalangienn joint level and is distributed to fingers I and II

The short fibular muscle has a thin tendon which inserts onto the fifth metatarsal bone.

The long fibular muscle almost completely covers the origin of the short fibular muscle, and its tendon crosses the plantar face of the tarsus and inserts onto the proximal end of the first metatarsal bone.

The lateral extensor muscle of the foot is assigned to the phalange V. The triceps surae muscle consists of a well developed soleus muscle and of the gastrocnemius muscles that show very prominent bellies.

The superficial flexor muscle of the foot is well developed, and its tendon splits into four branches that are assigned to the fingers II-V.

The popliteus muscle is a powerful, but small muscle.

Since lymph centers are located along the arterial paths, it is necessary to point out some elements specific to the vascular structures of the pelvic limb in ferrets (Fig. 2).

The lymph nodes of the ferret are characterized by their considerable dimensions in relation to the animal's size. Their topography is particular because they drain the lymph from a large area. During the dissection, the lymph nodes and lymphatic vessels from the femoral trigon and popliteal space were identified.

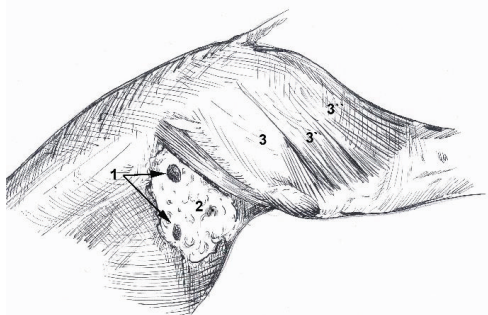
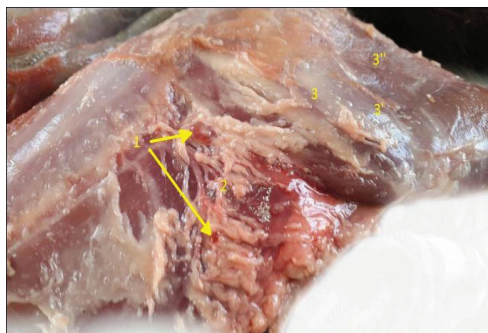


Fig. 2. Subiliac lymph nodes and superficial inguinal lymph node (original):

- 1 - subiliac lymph nodes, 2 - superficial inguinal lymph node, 3 - biceps muscle, 3' - biceps muscle, cranial portion, 3'' - biceps muscle, caudal portion

In all investigated corpses the inguinal superficial lymph nodes and the internal iliac lymph nodes were shown. The popliteal lymph node has also been identified.

The superficial inguinal lymph centre appears situated on the epigastric caudal artery in all three corpses investigated, being represented by a single 2 mm lymph node. The afferent

lymphatic vessels come from the ventro-caudal abdominal region, from the mammary region, the medial face of the thigh, vulva, foreskin, penis and anus. The efferent lymphatic vessels are tributary to the medial iliac lymph nodes (Fig. 3).

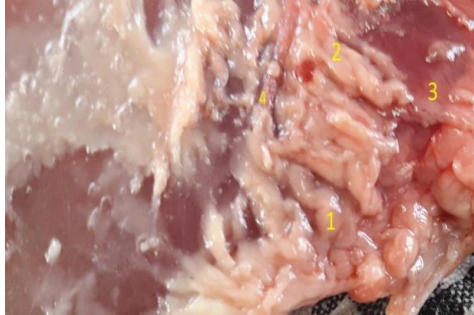

Fig. 3. Subiliac lymph node (original):
1 - inguino abdominal fat pedicle; 2 - subiliac lymph node; 3 - tensor fasciae latae muscle; 4 - circumflex iliac profound artery, vein

In the inguinal region there is a large amount of adipose tissue that surrounds the superficial inguinal lymph nodes. The adipose tissue forms the inguino-abdominal adipose pedicle. The external iliac artery emits as a collateral the deep iliac circumflex artery. The pudendoepigastric trunk detaches at a sharp angle and directs itself, dorsally of the femoral ring, to the caudal edge of the deep inguinal ring, where it ends through the caudal epigastric artery and the external pudendal artery. The caudal epigastric artery follows, along the floor of the abdominal cavity, the medial border of the deep inguinal ring, and then, along the lateral edge of the right abdominal muscle, anastomoses with the cranial epigastric artery.

The subiliac lymphnodes, although described as inconstant in the literature, were identified in all dissected corpses (Fig. 3). These lymph nodes have a globular aspect, approximately 3.5 mm in size, and are located on the deep iliac circumflex artery. The associated afferent lymphatic vessels come from the lumbar and gluteal region, the lateral face of the thigh and calf. Efferent lymphatic vessels are tributary to the medium iliac lymph nodes. The popliteal lymph center is represented by a lymph node disposed in the conjunctival space bounded by the femoral biceps and the

semitendinosus muscle on the tract of the caudal femoral artery (Fig. 4).

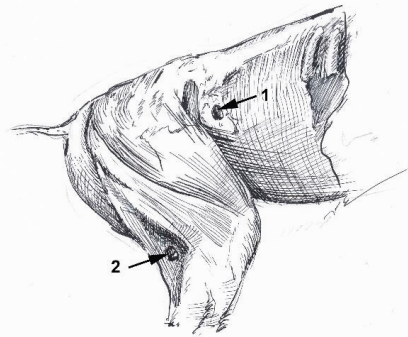
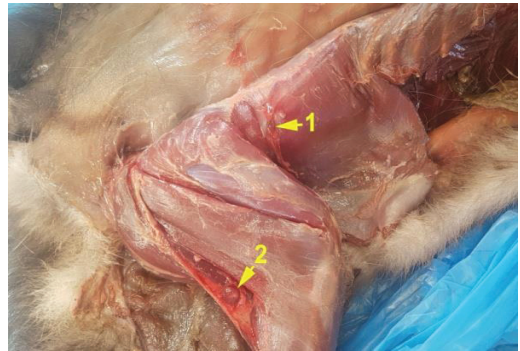


Fig. 4. The popliteal lymph center (original):
1 - popliteal lymph nodes; 2 - subiliac lymph nodes

The femoral artery is the direct continuation of the external iliac artery in the femoral region; it passes through the space between the femoral ring and the large adductor ring, from where it continues with the popliteal artery. In the femoral triangle, the femoral artery is covered by the deep inguinal lymph center and covers, in turn, the femoral vein. In its path, it emits the following collaterals: lateral femoral circumflex artery, saphenous artery, descending genicular artery and caudal femoral artery.

The lateral circumflex femoral artery originates under the femoral ring at a sharp angle. It heads cranially between the sartorius muscle and the psoas major muscle, and then between the vastus medialis muscle and the right femoral muscle, contributing to their irrigation.

The saphenous artery detaches itself in the distal segment of the femoral triangle, leaving it, along the inner face of the gracilis muscle, accompanied by the saphenous vein and nerve (n, a, v); on the medial face of the shank, it

divides into a cranial and a caudal branch. The caudal branch is more developed and joins the caudal root of the saphenous till above the tarsus, where it anastomoses with the caudal tibial artery. After the completion of this anastomosis it ends in the post-tarsal sheath through the plantar arteries (lateral and medial).

Here, the plantar arteries cross the lateral edges of the deep flexor tendon. These are satellites to the plantar nerves, till below tarsus, where the deep branches of these arteries anastomose between them, generating the "deep plantar arch", together with the perforating tarsal artery. The very fine superficial branches of the plantar arteries continue with the common plantar digital arteries II and III respectively, which are located medial and lateral to the tendons of the flexors, down to the distal end of the metatarsus, where they anastomose with the proper plantar digital arteries. From the deep plantar arch, the plantar metatarsal arteries II and III come off distally, which are more developed than the common digital arteries. All these mentioned branches anastomose distally in a collector trunk to the distal perforating branch of the dorsal metatarsal artery.

The descending genicular artery heads ventro-cranial, between the sartorius and the gracilis muscles, to the medial face of the knee joint, where it spreads arboriformly.

The caudal femoral artery is the last collateral femoral artery. It detaches at the level of the large adductor muscle ring and is located between the femoral biceps muscle and the semitendinous muscle (popliteal space), where it ends through ascending and descending branches. The ascending branch irrigates the propulsor muscles, in which it anastomoses with the medial femoral circumflex artery. The descending branch contributes to the irrigation of popliteal lymph nodes and gastrocnemius muscles. A long branch accompanies the tibial nerve and anastomoses, proximal to the calcaneus, to the saphenous artery.

This lymph node has a globular appearance and a size of about 2.5 mm. The afferent lymphatic vessels come from the thigh region, the leg, and the autopodium regions. The

efferent vessels are tributaries of the sacral lymph nodes and sometimes to the medium iliac lymph nodes.

CONCLUSIONS

The medius gluteus muscle was found to be very well developed, but we noticed the absence of its lumbar portion and the merging with the accessory gluteus muscle

The long digital extensor muscle in ferret is almost completely covered by the cranial tibial muscle.

Unlike other carnivores, in ferrets, the lymph nodes have considerable dimensions as compared to the animal size.

The lymph nodes topography is particular because they are able to drain lymph from a large area.

The adipose tissue from the inguinal region is very abundant; it forms the fatty pedicle which surrounds the superficial inguinal lymph nodes.

The superficial inguinal lymph nodes were observed to be located on the epigastric caudal artery.

Although the literature describes the subiliac lymph nodes as being inconstant, we have found them in all corpses.

The popliteal lymph node is represented in the ferret by a single structure with a globular appearance located in the popliteal conjunctive space.

REFERENCES

- Cotofan, V., Predoi, G. (2003). Anatomia topografică a animalelor domestice, Ed. Bic All, Bucuresti.
- Dunkin G.W., Laidlaw P.P. (1926). Studies in Di\og-Distemper. I. Dog-Distemper in the Ferret. J. Comp. Path & Therap., 39:201-240.
- Hritcu Valentina, Cotofan V. (2000). Anatomia animalelor de blana, Nutria, Dihorul, Ed. "Ion Ionescu de la Brad", Iași.
- Mönning H.O. (1934). Veterinary Helminthology and Entomology. Wood.
- Pașteu E. ș.a., (1978). Caiet de lucrări practice în Anatomia comparativă și topografică a animalelor domestice, Vol I, Lito. A.M.D.- I.A.N.B., București.
- Pastea,E. (1979). Atlas de Anatomie Veterinara, Ed.Ceres, Bucuresti.
- Predoi, G., Belu, C. (2001). Anatomie clinică, Ed. ALL, București.
- Predoi, G. (1999). Anatomia comparată a animalelor domestice (Anatomia topografică), Ed. Casa Cărții de Științe.

*** Nomina Anatomica Veterinaria 2017

CLINICAL SCIENCES

ALUMINUM LEVELS IN CATS AND DOGS

Emanuela BADEA, Gheorghe Valentin GORAN, Victor CRIVINEANU

Faculty of Veterinary Medicine, USAMV Bucharest, 105 Splaiul Independentei, 050097,
District 5, Romania, EU

Corresponding author email: emanuela.badea@gmail.com

Abstract

Aluminum is the third most abundant element in the Earth's crust and makes for durable, light and corrosion resistant objects. Aluminum is also an excellent conductor of electricity. It has thus made its way into items all around us. Its bioavailability grew as its uses increased, being utilized as an additive in processed food, cosmetics and pharmaceutical products. Aluminum may contribute to several neurological and haematological disorders. This study aimed to study the aluminum levels in hair samples taken from cats and dogs. The study took into consideration the animals' habitat, gender and age. Hair samples were analyzed via ICP-MS. Mean aluminum levels were higher in dogs (136.66 mg•kg⁻¹) compared to cats (94.31 mg•kg⁻¹). Both cats and dogs that lived outdoors registered higher Al levels than animals living indoors, but no statistical significance was found.

Key words: aluminum, cats, dogs, habitat, hair.

INTRODUCTION

Aluminum is a nonessential, toxic element. It is the third most abundant element in the Earth's crust, comprising about 8%. (Alfrey, 1983; Greger, 1993; Greger & Sutherland, 1997; Shakhshiri, 2008) Because of its ubiquitousness, exposure is high. (Alfrey, Hegg, & Craswell, 1980) Its bioavailability grew as its uses increased. Oral exposure is most frequent, from aluminum cans, containers, cooking utensils, and food additives. (Alfrey, 1983; Nayak, 2002; Reilly, 2002) Antiperspirants, antacids, and vaccines also represent exposure sources, as well as aluminum made electrical devices, airplanes, boats, cars. (Sorenson, Campbell, Tepper, & Lingg, 1974; Greger & Sutherland, 1997; Reilly, 2002; Shaw & Tomljenovic, 2013)

Aluminum may contribute to neurological, haematological, and respiratory disorders. (Ganrot, 1986; al-Masalkhi & Walton, 1994; Mahieu, del Carmen Contini, Gonzalez, Millen, & Elias, 2000; Yokel, 2000; Shaw & Tomljenovic, 2013)

Hair samples have been used to assess environmental exposure to toxic elements (Ashraf, Jaffar, Khurshid, & Ehsan, 1995; Morton, Carolan, & Gardiner, 2002; Pereira, Ribeiro, & Gonçalves, 2004), as they are non-invasive to collect and non-perishable (Esteban

& Castano, 2009; Khaliq, et al., 2005; Dunicz-Sokolowska, Graczyk, Radomska, Długoszek, Wlazak, & Surkont, 2006) Wilhelm et al. (1989), after performing a study, concluded that hair analysis is of limited value for the diagnosis of aluminium exposure, and bone analysis is more suitable for the assessment of the individual body burden. In a 2013 review, Wolowiec et al. concluded that hair mineral analysis is a good method to investigate the organism's mineral status; however, they observed a need to standardize sample preparation procedures. This study aimed to assess the levels of aluminum in hair samples taken from cats and dogs living both indoors and outdoors.

MATERIALS AND METHODS

The study was conducted on clinically healthy animals. For analysis, hair samples were taken from 23 dogs and 17 cats. The animals' habitat, gender and age were taken into account, as shown in Table 1. Thus, of the 17 cats, 9 lived indoors and 8 lived outdoors, 8 were males and 9 were females, 9 were below the age of five and 8 were above the age of five. Of the 23 dogs, 11 lived indoors and 12 lived outdoors, 9 were males and 14 were females, and 7 were below the age of five and 16 were above the age of five.

Hair samples were collected from the flank region and stored in paper envelopes.

The samples were then washed, dried and weighed at 0.5 g. 5 ml HNO₃ and 1 ml HCl were added in the digestion process.

Samples were lastly diluted to 10 ml with ultrapure water before being analyzed *via* ICP-MS for aluminum levels.

Statistical analysis was performed using the VassarStats: Website for Statistical Computation (<http://vassarstats.net>).

Table 1. Studied animals broken down into categories

Specie	Cats	Dogs
Habitat	Indoor	9
	Outdoor	8
Gender	Males	9
	Females	9
Age	Below 5 years	7
	Above 5 years	16
Total	17	23

RESULTS AND DISCUSSIONS

Mean aluminum levels for cats are shown in Figure 1.

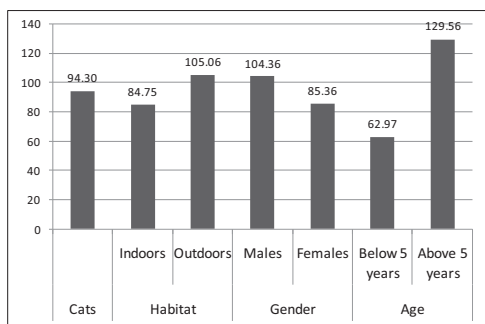


Figure 1. Mean aluminum cat levels (mg•kg⁻¹)

The cat hair samples reached an overall mean level of 94.30 mg•kg⁻¹. When broken down into categories, no statistical significance was found between either of the studied categories.

Even so, cats that lived outdoors registered a higher aluminum concentration when compared to indoor cats (105.06 vs. 84.75 mg•kg⁻¹). Male cats (104.36 mg•kg⁻¹) had higher levels compared to females (85.36 mg•kg⁻¹).

Cats below the age of five (62.97 mg•kg⁻¹) registered lower levels of aluminum compared to cats above the age of five (129.56 mg•kg⁻¹).

Mean aluminum levels for dogs are shown in Figure 2.

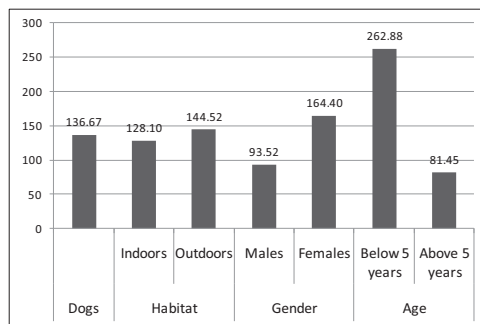


Figure 2. Mean aluminum dog levels (mg•kg⁻¹)

Dogs registered an overall level of aluminum of 136.67 mg•kg⁻¹.

No statistical significance was either found when comparing different dog categories.

However, dogs that lived indoors (128.10 mg•kg⁻¹) registered lower concentration than dogs that lived outdoors (144.52 mg•kg⁻¹).

Males (93.52 mg•kg⁻¹) registered lower concentrations compared to females (164.40 mg•kg⁻¹).

Dogs below the age of five (262.88 mg•kg⁻¹) registered higher concentrations compared to dogs above the age of five (81.45 mg•kg⁻¹).

When comparing dogs vs. cats, dogs below the age of five registered statistically significant higher levels of aluminum ($p < 0.05$) compared to cats below the age of five (262.88 mg•kg⁻¹ vs. 62.97 mg•kg⁻¹).

Other comparisons between the two species rendered no statistical significance. However, cats registered a lower overall level compared to dogs (94.30 vs. 136.67 mg•kg⁻¹).

Indoor cats (84.75 mg•kg⁻¹) registered a lower level compared to indoor dogs (128.10 mg•kg⁻¹).

Outdoor cats (105.06 mg•kg⁻¹) registered a lower level compared to outdoor dogs (144.52 mg•kg⁻¹).

Male cats (104.36 mg•kg⁻¹) registered higher levels compared to male dogs (93.52 mg•kg⁻¹).

Female cats (85.36 mg•kg⁻¹) registered lower levels compared to female dogs (164.40 mg•kg⁻¹).

Cats above the age of five (129.56 mg•kg⁻¹) registered higher levels compared to dogs above the age of five (81.45 mg•kg⁻¹).

Kosla & Skibniewska (2010) studied the aluminum hair concentrations in dogs from Warsaw and observed a level of 93.80 ± 72.81 mg•kg⁻¹ in the investigated population. They

noticed significant higher levels in dogs from the city environment compared to dogs from the breeding kennel and dogs kept at home, and also a positive dependence of age and aluminum content in the hair.

Tomza-Marciniak et al. (2012) found a level of $1.649 \text{ mg}\cdot\text{kg}^{-1}$ aluminum in the serum of pet dogs.

CONCLUSIONS

A statistical significance was found ($p < 0.05$) when comparing dogs below the age of five to cats below the age of five, the former registering higher levels.

Although no significant correlation was found, the higher levels of aluminum registered in both cats and dogs that were living outdoors, compared to those living indoors, indicate that environmental pollution may be a cause for aluminum bioaccumulation.

REFERENCES

- Alfrey, A. C. (1983). Aluminum. *Adv Clin Chem*, 23, 69-91.
- Alfrey, A. C., Hegg, A., & Craswell, P. (1980). Metabolism and toxicity of aluminum in renal failure. *Am J Clin Nutr*, 33 (7), 1509-16.
- al-Masalkhi, A., & Walton, S. P. (1994). Pulmonary fibrosis and occupational exposure to aluminum. *J Ky Med Assoc*, 92 (2), 59-61.
- Ashraf, W., Jaffar, M., Khurshid, A., & Ehsan, U. (1995). Age- and sex-based comparative distribution of selected metals in the scalp hair of an urban population from two cities in Pakistan. *Environ Pollut*, 87, 61-4.
- Dunicz-Sokolowska, A., Graczyk, A., Radomska, K., Długoszek, M., Wlazak, E., & Surkont, G. (2006). Contents of bioelements and toxic metals in a Polish population determined by hair analysis. Part 2. Young persons aged 10-20 years. *Magnes Res*, 19 (3), 167-79.
- Esteban, M., & Castano, A. (2009). Non-invasive matrices in human biomonitoring: a review. *Environ Int*, 35, 438-49.
- Ganrot, P. O. (1986). Metabolism and possible health effects of aluminum. *Environ Health Perspect*, 65, 363-441.
- Greger, J. L. (1993). Aluminum metabolism. *Annu Rev Nutr*, 13, 43-63.
- Greger, J. L., & Sutherland, J. E. (1997). Aluminum exposure and metabolism. *Crit Rev Clin Lab Sci*, 34 (5), 439-74.
- Khalique, A., Ahmad, S., Anjum, T., Jaffar, M., Shah, M. H., Shaheen, N., et al. (2005). A comparative study based on gender and age dependence of selected metals in scalp hair. *Environ Monit Assess*, 104, 45-57.
- Kosla, T., & Skibniewska, E. M. (2010). The content of aluminum in the hair of Yorkshire terrier dogs from the Warsaw area depending on sex, age and keeping conditions. *Trace Elements & Electrolytes*, 27 (4), 209-213.
- Mahieu, S., del Carmen Contini, M., Gonzalez, M., Millen, N., & Elias, M. M. (2000). Aluminum toxicity. Hematological effects. *Toxicol Lett*, 111 (3), 235-42.
- Morton, J., Carolan, V. A., & Gardiner, P. H. (2002). Removal of exogenously bound elements from human hair by various washing procedures and determination by inductively coupled plasma mass spectrometry. *Anal Chim Acta*, 455, 23-34.
- Nayak, P. (2002). Aluminum: impacts and disease. *Environ Res*, 89 (2), 101-15.
- Pereira, R., Ribeiro, R., & Gonçalves, F. (2004). Calp hair analysis as a tool in assessing human exposure to heavy metals (S. Domingos mine, Portugal). *Sci Total Environ*, 327 (1-3), 81-92.
- Reilly, C. (2002). *The packaging metals: aluminum and tin*. In *Metal contaminants in food* (3rd ed.). Malden, MA, USA: Blackwell Science.
- Shakhashiri, B. Z. (2008). *Chemical of the Week: Aluminum*. University of Wisconsin.
- Shaw, C. A., & Tomljenovic, L. (2013). Aluminum in the central nervous system (CNS): toxicity in humans and animals, vaccine adjuvants, and autoimmunity. *Immunol Res*, 56 (2-3), 304-16.
- Sorenson, J. R., Campbell, I. R., Tepper, L. B., & Lingg, R. D. (1974). Aluminum in the Environment and Human Health. *Environ Health Perspect*, 8, 3-95.
- Tomza-Marciniak, A., Pilarczyk, B., Bąkowska, M., Ligocki, M., & Gaik, M. (2012). Lead, cadmium and other metals in serum of pet dogs from an urban area of NW Poland. *Biol Trace Elem Res*, 149 (3), 345-51.
- Wilhelm, M., Passlick, J., Busch, T., Szydlik, M., & Ohnesorge, F. K. (1989). Scalp hair as an indicator of aluminium exposure: comparison to bone and plasma. *Hum Toxicol*, 8 (1), 5-9.
- Wołowicz, P., Michalak, I., Chojnacka, K., & Mikulewicz, M. (2013). Hair analysis in health assessment. *Clin Chim Acta*, 419, 139-71.
- Yokel, R. A. (2000). The toxicology of aluminum in the brain: a review. *Neurotoxicology*, 21 (5), 813-28.

PRELIMINARY CLINICAL EVALUATION OF MESENCHYMAL STROMAL CELL TREATMENTS FOR UNUNITED ANCONEAL PROCESS AND LEGG-CALVE'-PERTHES DISEASE IN DOGS

Antonello BUFALARI¹, Alberto CROVACE², Antonio DI MEO¹,
Vasilica-Flory PETRESCU¹ Alexandra PETEOACA³, Luisa PASCUCCHI¹,
Gabriele SCATTINI¹, Beatrice DEL SAL¹, Giulia MORETTI¹

¹Department of Veterinary Medicine, University of Perugia, Via San Costanzo 4, 06126, Perugia, Italy

²IRCCS "Saverio de Bellis", Via Turi 27, 70013, Castellana Grotte, Italy

³University of Agronomic Sciences and Veterinary Medicine of Bucharest, Faculty of Veterinary Medicine, 105 Spl. Independenței, District 5, 005097, Bucharest, Romania

Corresponding author email: antonello.bufalari@unipg.it

Abstract

Mesenchymal stromal cells are a population of adult stem cells with a vast potential for tissue engineering as well as regenerative medicine. Ununited Anconeal Process (UAP) and Legg-Calvé-Perthes (LCP) disease are two common growth pathologies in young dogs. Even if these diseases present different manifestations and etiopathogenesis, the attention of modern research has focused on the "restoration" of the same cells that were not developed correctly in these bone defects. The administration of Bone Marrow Mesenchymal Stromal Cells and Bone Marrow Mononuclear Cells containing MSCs in these two types of pathologies could be considered as an innovative but also conservative therapy, allowing the formation of new bone tissue in a minimally invasive way. In this preliminary study we evaluated the improvement of the clinical and also the radiographic condition in 2 dogs with UAP and in 3 dogs with LCP, treated with a single administration of autologous Bone Marrow Mesenchymal Stromal Cells and Bone Marrow Mononuclear Cells.

Key words: Ununited Anconeal Process, Legg-Calvé-Perthes disease, dog, Mesenchymal Stromal Cells, Bone marrow Mononuclear cells.

INTRODUCTION

Recent studies have demonstrated the exciting potential of tissue regeneration *via* tissue engineering approaches.

Bone marrow-derived mesenchymal stromal cells (BM-MSCs) were first isolated in the 1970s and were the progenitors of many mesenchymal mature cells, including osteocytes, chondrocytes, and adipocytes.

BM-MSCs are an important source of osteogenic cells for bone tissue engineering, and many studies have shown evidence that they contribute to bone regeneration (Liu et al., 2014).

The Mesenchymal and Tissue Stem Cell Committee of the International Society for Cellular Therapy (ISCT) proposes three standard requirements to better identify MSCs (Dominici et al., 2006):

1. cells must be plastic-adherent when maintained in standard culture conditions.
2. > 95% of the MSCs population must express specific surface antigens (CD105, CD73 and CD90) analyzed by flow cytometry
3. cells must display multipotential differentiation capacity, being able to differentiate into osteoblasts, chondroblasts and adipocytes.

A number of favorable biological characteristics, including their poor immunogenicity and the ability to induce immune-tolerance, make BM-MSCs ideal therapeutic agents.

Hernigou and Beaujean first used bone marrow grafting to treat osteonecrosis and the results were encouraging (Hernigou et al., 2002).

BM-MSCs may be used after isolation and culture expansion or in the form of a concentrate of BM mononuclear cells (BM-MNCs) that includes the fraction of BM-MSCs.

In this study we treated two orthopedic diseases:

- Ununited Anconeal Process (UAP), an uncommon condition of the canine elbow joint causing pain and lameness in young medium-large breeds, thought to be due to physeal osteochondrosis or relative overgrowth of the radius.
- Legg-Calvé-Perthes (LCP) disease, a non-inflammatory aseptic necrosis of the femoral head, thought to develop secondarily to ischaemia and resulting in vascular compromise.

The aim of this study was to evaluate the therapeutic effects of culture expanded BM-MSC and BM-MNCs in the treatment of UAP and of LCP in the dog.

MATERIALS AND METHODS

Owned dogs referred at veterinary teaching The Veterinary Teaching Hospital of Perugia with a radiographic diagnosis of UAP and LCP disease were included in the study. The treatment has been authorized in all the dogs through an informed consent signed by the owners. All the dogs underwent a careful clinical examination and complete blood analysis.

Five dogs were included: 2 cases with UAP and 3 cases with LCP disease, respectively. All the dogs were less than one year of age. For the UAP cases the dogs were 2 Corso breed (8 months old), one male and one female, with mono-lateral UAP, both on the left elbow. The three LCP cases were small breed dogs [1 mixed-breed Chihuahua (6 months old), 1 Miniature Poodle (7 months old), 1 Russian Toy (7 months old)], two males and one female, all with mono-lateral disease.

• UAP group

The dogs were presented for a forelimb lameness arisen 2 months earlier. At the orthopedic evaluation the following clinical signs were noted: grade of lameness (Quinn et al., 2007), joint ectasia and pain at the passive manipulation of the elbow (Tables 1-3). The Range of Motion was reduced especially during flexion even in deep sedation. The diagnostic workup included: radiographic examination, dynamic fluoroscopy imaging, CT study and arthroscopy of the affected elbow joint. The aim of these diagnostic exams was to assess the grade of UAP (Table 4) and to exclude any

other joint disease (eg. Radio-ulnar incongruence, fragmented coronoid process). Dogs with grade III UAP were not included. All the dogs have undergone to surgery to perform a Bi-Oblique Dynamic Proximal Ulnar Osteotomy (BODPUO) (Caron et al., 2016) in addition of the BM-MSCs treatment in order to reduce the load on the ulna compartment. BM sample was taken, at the same time of the ulnar osteotomy surgery, from the iliac crest with a 16 G Jamshidi needle. Bone marrow harvested was diluted 1:1 in phosphate-buffered saline (PBS) containing 2000 U/ml heparin. It was then centrifuged on a density gradient solution (Histopaque 1077, Sigma Aldrich) to collect the mononuclear cell fraction (BMMNCs) that was plated in collagen coated flasks. Cells were cultured in Low Glucose Dulbecco's modified Eagle's medium with 10% fetal bovine serum (FBS) and 1% antibiotics. MSCs in culture adhered to the tissue culture substrate and displayed a fibroblast-like morphology. Primary cultures were maintained until passage 3 to deplete non-adherent haematopoietic cell fraction and expanded to obtain about 30×10^6 cells. At the time of the first radiographic follow up, the cells were ready to be grafted in the ununited anconeal gap. They were detached with trypsin EDTA, washed in FBS free medium and re-suspended in Platelet Rich Plasma (PRP). PRP was activated with 10% Calcium Gluconate immediately prior to administration.

Under general anaesthesia the dogs were positioned in lateral recumbency with the limb to be treated downwards, to allow the medial access to the elbow joint: an arthroscopic visualization of the non-united portion of the Anconeal Process was performed in order to correctly insert a 18G needle into the non-vital portion of the bone in the proximal part of the process. Successively, the joint was drained from the saline solution and the stem cells compound (PRP solution and Calcium Gluconate) was inserted by means of the needle. At the end of this procedure, needle and optic were removed and the skin was closed in a routine fashion.

The follow up were made at 15, 30, 60 days, 3 and 6 months post treatment; they included a clinical and orthopedic evaluation and a radiographic examination.

• **LCP group**

The dogs with LCP disease were presented with severe hindlimb lameness, reluctance to move, severe pain at the palpation of the hip, and muscular hypotrophy. The diagnostic workup consisted in a standard radiograph projection of both hips to assess the severity and grading of LCP disease (Ljunggren, 1967; Mickelson et al., 1981; Crovace, 2013) (Table 5). Dogs with more than grade III LCP disease were not included. The owners of the dogs with LCP disease declined the standard surgical treatment (total hip replacement or head/neck femur ostectomy) and preferred cell therapy. The bone marrow sample was taken from the iliac crest with a 16G Jamshidi needle the same day of the implantation. In order to process the cells quickly, the following protocol was used: bone marrow harvested from iliac crest was diluted 1:1 in phosphate-buffered saline (PBS) containing 2000 U/ml heparin and centrifuged on a density gradient solution (Histopaque 1077, Sigma Aldrich). The BM mononuclear cells (BM-MNCs) at the interphase were transferred to a new conical tube and washed twice adding each time 30 ml of buffer before centrifugation. The cell pellet was finally re-suspended in an appropriate amount of freshly prepared PRP for surgical application. When the compound was ready to implant, dogs were placed again under general anesthesia and in dorsal recumbency, in order to perform a ventral approach to the head of the femur. Under ultrasound (US) guidance a 22G spinal needle was inserted directed to the bone lysis area. A bone tunnel was prepared with a Kirschner wire (0,8 mm in diameter) allowing the following entry of the needle, through the wire, into the bone. After wire retrieval, the injection of the BM-MNCs and PRP was monitored by US guide assuring the correct implantation. The clinical and orthopedic follow up were made at 10 days post treatment while the radiographic follow up were made at 30, 60 days and 6 months post treatment. In all the dogs were evaluated the following: grade of lameness (Table 1) (Quinn et al., 2007), reaction at manipulating the affected joint (Table 2), joint ectasia, joint hyperthermia (Table 3), radiographic score for osteoarthritis signs, radiographic score of amount of radiopacity of the bony defects.

Table 1. Lameness score

Description	Grade
Normal	0
Normal in gait, mild lameness at walk	1
Lame mild to moderate in all the gaits	2
Severe lame in all the gaits	3
Not weight bearing lameness	4

Table 2. Response to manipulation

Response to manipulation	Grade
Normal	0
Mild (turn the head towards the affected limb)	1
Moderate (limb retraction to manipulation)	2
Severe (yelp or aggression)	3
Not possible to manipulate	4

Table 3. Sspecific evaluation of the affected Joint

Clinical signs	Absent	Mild	Moderate	Severe
Ectasia	0	1	2	3
Hyperthermia	0	1	2	3
Skin swelling	0	1	2	3

Table 4. UAP grade

UAP grade	Radiographic description
I	Anconeal process is not united with the proximal metaphysis of the ulna, but still connected by fibrocartilaginous tissue, a mild radiolucent area is evident.
II	Anconeal process is separated by an evident radiolucent line; the gap is complete but the process is still in place
III	Anconeal process is completely detached from the ulna, with a large radiolucent area, erosion of the margins and sclerosis.

Table 5. LCP disease grade by Ljunggren, 1967

LCP grade	Radiographic description
I	Femoral head and neck have a normal profile; there is an increased joint space, the acetabulum is normal and there are few radiolucent areas
II	Flattening of the femoral head, the radiolucent areas are larger and more numerous, the femoral neck is involved with osteophytes
III	Greater alteration of the femoral head profile (flattening and irregularity of the articular surface), irregular radiodensity and osteophyte production
IV	loss of the femoral head profile, large radiolucent areas alternated with small areas with normal density.
V	extensive fragmentation and deformation of the femoral head, signs of discontinuity of the articular surface

RESULT AND DISCUSSIONS

• UAP group

The clinical orthopedic evaluation showed a clinical improvement of the grade of lameness of 2 points in all the dogs at the time of final follow up (6 months post treatment), great reduction of pain during the manipulation of the affected joint, and complete owner satisfaction about the general clinical condition of their dogs (Table 6). The radiographic evaluations showed a partial reduction of the radiolucent defect on the anconeal process. The bone callus, as a result of the ulnar osteotomy, was reshaped at the radiographic follow up at 6 months post-treatment.

Radio-ulnar incongruence was reduced thanks to the dynamic osteotomy, and subsequently subchondral bone sclerosis was mild weaker at the level of the ulnar semilunar incision.

A variety of treatments have been proposed for UAP including removal of the anconeal process (Grondalen et al., 1980; Guthrie et al., 1989), proximal ulnar osteotomy (with or without intramedullary fixation) and lag screw (LS) fixation of the anconeus process with or without proximal ulnar osteotomy (PUO) (Pettitt et al., 2009). PUO has been considered satisfactory in radiographic union of the anconeus in some, but not all, cases (Sjostrom

et al., 1995). A later report combining PUO with LS fixation of the anconeus reported the radiographic union in 4 of 4 cases (Krotscheck et al., 2000) but the small size of this study was a limitation. PUO alone has been reported as a treatment for UAP by putatively relieving the “excessive contact pressure” on the anconeal process (Pettitt et al., 2009). Clinical results compared favorably with excision, although fusion of the anconeus to the ulna in these studies varied from 12 to 95 per cent. Sjostrom et al. (1995) evaluated the outcome with a combination of radiographic and subjective lameness evaluations and reported 21 of 22 elbows had radiographic evidence of healing of the anconeus, where healing was considered complete if only “a narrow radiolucent line was evident” (Pettitt et al., 2009). The BODPUO is an upgraded ulnar osteotomy made-up by Fitzpatrick et al. (2014) for the treatment of elbow dysplasia. The combination of BODPUO and stem cell therapy could be a rational therapeutic strategy to treat UAP: it combines the mechanical dynamism given by the osteotomy to avoid the compression force upon the anconeus process, and the osteogenesis power of BM-MSCs at the level of non-union.

Table 6. UAP group; FU: follow up

FU	Description	1 Uriel	2 Margot
0	Grade of lameness	3	3
	Grade of Manipulation	2	2
	Joint Ectasia	3	3
	Joint Hyperthermia	2	1
	Joint Swelling	2	2
10 days	Grade of lameness	3	
30 days	Grade of lameness	2	
6 months	Grade of lameness	0	
	Grade of Manipulation	0	
	Joint Ectasia	0	
	Joint Hyperthermia	0	
	Joint Swelling	0	

• LCP disease group

A reduction on lameness was seen in all the dogs and the 6 months follow up, the improvement was of 2 points referred to the Quinns' scale. The improvement of the clinical condition was gradual and distributed over a period of 1-5 months.

The clinical improvement was seen since the 30 days follow up, with a reduction of 1 point of lameness in all treated cases and a pain reduction at manipulation of the joint. No sign of severe side effects was seen, except for a transient increase of the lameness' degree in one dog (n.1) during the first week post treatment (Table 7). Post treatment radiographic evaluations showed a partial filling of the radiolucent defects on the femoral head with an increase of subchondral sclerosis and partial remodeling of the shape of femoral head and neck. However, the persistence of the femoral head collapse and the incongruity of the coxo-femoral joint was still present.

Experimental research and clinical studies on human osteonecrosis of the femoral head have shown that necrotic bone tissue can be replaced by active bone tissue, but the osteogenic potential for repair is low in the case of osteonecrosis. For this reason we have excluded from this study dogs with grade IV and V according to Ljunggren's scale (Ljunggren, 1967). Many authors have considered that the grounds for insufficient bone remodeling can be linked to the small number of progenitor cells present in the femoral head (Hernigou et al., 1999; Hernigou et al., 2016). A possible explanation for the therapeutic effect of the bone marrow implant is that BM-MSCs are responsible for the production of angiogenic cytokines, which stimulate the processes of neoangiogenesis with consequent improvement of the osteogenesis. Angiogenesis allows the formation of new vessels by sprouting or dividing pre-existing vascular structures following metabolic stresses in hypoxic tissues and improving tissue capillarization. It involves the interaction of endothelial progenitor cells, pericytes, growth factors and components of the cellular matrix. Blood vessels are essential for the repair of the necrotic femoral head because they bring nutrients and allow the removal of waste substances (Wang et al.,

2013). Hernigou et al. (1999) demonstrated that BM-MNCs are able to induce the formation of new blood vessels from endothelial cell progenitors or from hemangioblasts present in this cellular fraction.

To support this hypothesis, Yan Z. et al in 2009 conducted a study about the survival and differentiation of MSC transplanted in a dog in which the osteonecrosis of the femoral head was reproduced surgically. Patients were treated with autologous BM-MSCs implantation and physiological saline for the control group. The implanted cells were labeled with a green fluorescent protein, in order to monitor the transplant. The immunohistochemistry of the excised femoral heads demonstrated the presence of labeled MSCs at the necrosis site 12 weeks after implantation. Furthermore, they showed an increase in trabecular bone volume compared to the control group. Their studies showed that MSCs from the transplanted bone marrow could survive, proliferate and differentiate directly into osteoblasts, and that they also contributed to the acceleration of the repair process (Yan Z. et al., 2009). Management of avascular necrosis of femoral head can be grouped into three main categories: non-surgical management, head and neck ostectomy and prosthetic hip replacement. The non-surgical management (rest period with NSAD's treatment) is often ineffective. However, in human medicine, has been demonstrated that head preserving procedures which aims at decompression and revascularization of the femoral head have given encouraging results in pre-collapse stages (Mohanty et al., 2017). In light of these considerations, the authors preferred not to include a grade higher than III according to Ljunggren's scale (Ljunggren, 1967) in this study. The core decompression is the most popular revascularization procedure which reduces the intra-osseous pressure caused by interstitial edema, improves vascularity, enhances bone healing and therefore relieves pain. It can be achieved by drilling a large single tract into the femoral head or by drilling multiple drill holes (Mohanty et al., 2017). The mechanical activity obtained by drilling the non-vital bone could be involved in the revascularization process. Moreover, the results of the study by Dahners

& Hillsgrove (1989) suggest that a drill hole in an avascular bone, provides a path for rapid vascular invasion and quickly result in new bone formation. The combination of drilling the non-vital bone and cell therapy could be a

rational therapeutic strategy to treat LCP: it combines the mechanical revascularization given by the single drilling and the osteogenesis power of BM-MNCs at the level of the head.

Table 7. LCP disease group; FU: follow up

FU	Description	1 Lucy	2 Mirò	3 Leo
Time 0	Grade of lameness	4	2	3
	Grade of Manipulation	4	3	3
	Joint Ectasia	1	1	1
	Joint Hyperthermia	1	1	1
	Joint Swelling	1	1	1
10 days	Grade of lameness	3	2	3
30 days	Grade of lameness	0	1	1
6 months	Grade of lameness	0	0	0
	Grade of Manipulation	0	0	0
	Joint Ectasia	0	0	0
	Joint Hyperthermia	0	0	0
	Joint Swelling	0	0	0

CONCLUSIONS

In this preliminary study, the application of autologous cell therapy in dogs is well tolerated and requires a minimally invasive approach providing a full clinical improvement and a partially radiographical amelioration in dogs affected by Ununited Anconeal Process and Legg-Calvé-Perthes disease; for the UAP group, in addition to cell therapy, proximal ulnar osteotomy was performed. We cannot exclude that the biomechanical changes obtained by dynamic ulnar osteotomy could contribute to the clinical outcome.

In the LCP group, the injection of BM-MNCs was performed through a shaped drill hole: we performed only a single mini-tunnel drilling into the femoral head. As discussed previously, drilling a non-vital bone could induce an active revascularization and new bone formation. In our preliminary study, even if a single drilling micro-hole was made, is not possible to exclude that this minimal mechanical action

has created the conditions for the improvement of the healing process.

The results obtained, allow the authors to consider this technique as a valid alternative therapy, especially when the owner refuses standard treatments (as for the LCP disease group). The technique allows a good remission of clinical signs and, moreover, represents a minimally invasive treatment compared to conventional ones. The use of Ultrasonography guidance in the LCP group could represent a non-invasive and safe way of administration avoiding the use of x-ray, and allowing a good visualization of the pathologic bone area. Further prospective studies are required to confirm whether the proposed techniques are associated with a durable clinical improvement.

REFERENCES

- Baksh D., Yao R., Tuan R.S. (2007). Comparison of proliferative and multilineage differentiation potential of human mesenchymal stem cells derived from umbilical cord and bone marrow. *Stem Cells*. 25:,1384-1392.

- Caron A., Fitzpatrick N. (2016). Bi-Oblique Dynamic Proximal Ulnar Osteotomy: Surgical Technique and Clinical Outcome in 86 Dogs. *Veterinary Surgery*. 45(3),356-63. doi: 10.1111/vsu.12464.
- Crovace A. (2013). Implantation of autologous bone marrow mononuclear cells as a minimal invasive therapy of Legg-Calvé-Perthes disease in the dog. 2nd International Conference and Exhibition on Orthopedics & Rheumatology, Accepted Abstracts. *Journal of Orthopedics and Muscular System*. 2,2. DOI: 10.4172/2161-0533.S1.014
- Dahners L.E. & Hillsgrove D.C. (1989). The effects of drilling on revascularization and new bone formation in canine femoral heads with avascular necrosis: an initial study. *Journal of Orthopedic and Trauma*. (4),309-12.
- Dominici M, Le Blanc K, Mueller I, Slaper-Cortenbach I, Marini F, Krause D, Deans R, Keating A, Prockop Dj, Horwitz E.(2006). Minimal criteria for defining multipotent mesenchymal stromal cells. The International Society for Cellular Therapy position statement. *Cytotherapy*, (4),315-7.
- Grøndalen J., Rørvik A.M. (1980). Arthrosis in the elbow joint of young rapidly growing dogs. IV. Ununited anconeal process. A follow up investigation of operated dogs. *Nordisk veterinærmedicin*. 32(5),212-8.
- Guthrie S. (1989). Some radiographic and clinical aspects of ununited anconeal process. *Veterinary Record*. 24(25),661-2.
- Hernigou P., Beaujean F. (2002). Treatment of osteonecrosis with autologous bone marrow grafting. *Clinical Orthopaedics and Related Research*. (405),14-23.
- Hernigou P., Trousselier M., Roubineau F., Bouthors C., Chevallier N., Rouard H., Flouzat-Lachaniette C.H. (2016). Stem Cell Therapy for the Treatment of Hip Osteonecrosis: A 30-Year Review of Progress. *Clinics in Orthopedic Surgery*. 8(1):1-8.
- Jiang Y., Jahagirdar B.N., Reinhardt R.L., Schwartz R.E., Keene C.D., Ortiz-Gonzalez X.R., Reyes M., Lenvik T., Lund T., Blackstad M., Du J., Aldrich S., Lisberg A., Low W.C., Largaespada D.A., Verfaillie C.M. (2002). Pluripotency of mesenchymal stem cells derived from adult marrow. *Nature*. 4,(6893):41-9.
- Krotscheck U., Hulse D.A., Bahr A., Jerram R.M. (2000) Ununited anconeal process: lag-screw fixation with proximal ulnar osteotomy. *Veterinary and Comparative Orthopaedics and Traumatology*. 13, 212-216.
- Liu X., Liao X., Luo E., Chen W., Bao C., Xu U.H.K.H. (2014). Mesenchymal Stem Cells Systemically Injected into Femoral Marrow of Dogs Home to Mandibular Defects to Enhance New Bone Formation. *Tissue Engineering*. Part A, 20,883-92. DOI: 10.1089/ten.tea.2012.0677
- Ljunggren G. (1967). Legg-Perthes disease in the dog. *Acta Orthopaedica Scandinavica*. 95,1-79.
- Mickelson M.R., Mccurnin D.M., Awbrey B.J., Maynard J.A., Martin R.K. (1981). Legg-Calvé-Perthes disease in dogs: A comparison to human Legg-Calvé-Perthes disease. *Clinical Orthopaedics and Related Research*. (1),287-300.
- Mohanty S.P., Singh K.A., Kundangar R., Shankar V. (2017). Management of non-traumatic avascular necrosis of the femoral head-a comparative analysis of the outcome of multiple small diameter drilling and core decompression with fibular grafting. *Musculoskeletal Surgery*. (1),59-66. doi: 10.1007/s12306-016-0431-2.
- Orford K.W., Scadden D.T. (2008). Deconstructing stem cell selfrenewal: genetic insights into cell-cycle regulation. *Nature Reviews Genetics* 9(2),115-28.
- Pettitt R.A., Tattersall J., Gemmill T., Butterworth S.J., O'Neill T.J., Langley-Hobbs S.J., Comerford E.J., Innes J.F. (2009). Effect of surgical technique on radiographic fusion of the anconeus in the treatment of ununited anconeal process. *Journal of Small Animal Practice*. 50,545-548. DOI: 10.1111/j.1748-5827.2009.00821.x
- Pettitt R.A., Tattersall J., Gemmill T., Butterworth S.J., O'Neill T.J., Langley-Hobbs S.J., Comerford E.J., Innes J.F. (2009). Effect of surgical technique on radiographic fusion of the anconeus in the treatment of ununited anconeal process. *Journal of Small Animal Practice*. 50(10),545-8. doi:10.1111/j.1748-5827.2009.00821.x.
- Potten C.S., Loeffler M. (1990). Stem cells: attributes, cycles, spirals, pitfalls and uncertainties. Lessons for and from the crypt. *Development*. 110(4),1001-20.
- Quinn M.M., Keuler N.S., Lu Y., Faria M.L.E., Muir P., Markel M.D. (2007). Evaluation of agreement between numerical rating scales, visual analogue scoring scales, and force plate gait analysis in dogs. *Veterinary Surgery*. 36, 360-367.
- Ryan J., Barry F., Murphy J.M., Mahon B. (2005). Mesenchymal stem cells avoid allogenic rejection. *Journal of Inflammation*. 2,8.
- Sjostrom L., Kasstrom H., Kallberg M. (1995). Ununited anconeal process in the dog – pathogenesis and treatment by osteotomy of the ulna. *Veterinary and Comparative Orthopaedics and Traumatology*. 8, 170-176.
- Wang M., Liao Q., Zhou B., Qiu Z.Q., Cheng L.M. (2013). Preliminary study of influence of bone tissue from osteonecrosis of femoral head on the proliferation and differentiation of canine bone marrow mesenchymal stem cells. *Chinese Medical Journal*. 11, 856-859. DOI: 10.3760/cma.j.issn.0376-2491.2013.11.016
- Wilson E.B. (1986). The cell in development and inheritance. MacMillan, London.
- Yan Z., Hang D., Guo C., Chen Z. (2009). Fate of Mesenchymal Stem Cells Transplanted to Osteonecrosis of Femoral Head . *Journal of Orthopaedic Research*. 4, 442-446. DOI 10.1002/jor.20759

PRELIMINARY RESEARCH REGARDING CLINICAL AND MORFOLOGICAL FINDINGS IN NEGLECTED DOGS

Elena CÂRCIUMARU, Emilia CIOBOTARU-PÎRVU

¹University of Agronomic Sciences and Veterinary Medicine of Bucharest,
59 Marasti Blvd, District 1, Bucharest, Romania

Corresponding author email: e.carciumaru@yahoo.com

Abstract

The study aimed to present the clinical and morphological findings in neglected dogs during the period of 2015-2018 recorded in a private veterinary practice, in Bucharest, Romania. The purpose of this study was to identify and classify forms of passive abuse along with their effects on canine individuals. During the aforementioned period, 41 dogs were included in the study. Routine clinical and paraclinical methods of examinations were used, as well as after treatment follow-up. Several types of passive abuse have been recognised, such as lack of water and food, shelter, veterinary care and absence of proper surveillance. Lack of veterinary attendance was identified in 65% of studied animals (n=27), 26% were deprived of shelter (n=11), and 20 % were deprived of food and water (n=8). The dogs presented specific clinical signs and morphological features of malnutrition (n=8, 20 %), extremely large tumoral lesions (n=17, 41%), or severe parasitic dermatitis (n=10, 24%). Eleven dogs (26%) were deprived of shelter and surveillance. Multiple types of neglect were identified in the same dog (n=20, 49%). Conclusions: 44% of animals were older than 8 years (n=18), twelve animals died (30%) and 29 individuals (70%) were fully or partially recovered cases.

Key words: abuse, dog, malnutrition, neglect, neoplasia.

INTRODUCTION

The relationship between humans and animals is characterized by some paradoxes that are obvious in the extreme expressions of infinite love, unexplainable hatred and the most ruthless forms of cruelty to animals (Livingston, 2001). The issue of violence against animals is very complex. Considering these acts as being committed against the life and body of living beings, they also pose a threat to the environment; however, some deviant forms of animal behavior are closely associated with different forms of violence against humans (Bell, 2001). The Five Freedoms For Animal Welfare have been established as a guideline for the welfare of animals: freedom from hunger or thirst; freedom from discomfort; freedom from pain, injury, or disease; freedom to express normal behavior; and freedom from fear or distress (Merck, 2007). Under current legislation, pet owners must adhere to certain principles. The basic principle of animal welfare refers to the fact that no one has to produce unnecessary pain, physical or mental suffering or abandon

the animal, and financial excuses do not alleviate that responsibility. Any owner of a pet must be responsible for his/her health and well-being, as well as ensuring all conditions, along with care and attention, taking into account the ethological needs, depending on species and breed (sufficient food and water, possibility of movement, taking necessary measures for preventing animal straying). (Merck,2007; Legea 205/2004; Legea 9/2008). Shelters and accessories for restraint must be constructed and maintained in such a way for having not sharp or protruding edges that can injure the animal (Legea 205/2004; Legea 9/2008). This study is focused on dogs which have been presented by their owners in different stages of malnutrition, having extremely large tumoral lesions, severe parasitic dermatitis and other type of passive abuse, such as neglected fractures or wounds caused by the lack of shelter.

According to the explanatory dictionary of Romanian language, abuse is defined as violation of legality, an illegal act, an offense committed by someone's overthrow of his authority, an offense committed by deceiving

someone's trust. Moreover, definition of neglect is: who does not perform his duties with sufficient care; indolent, careless.

Abuse of animals can be defined as a deliberate or neglectful act of injuring or killing an animal. Neglect can be an act of omission or commission. It is often a continuum of action or lack of action by the owner over a prolonged period of time (Merck, 2007).

Classification of abuse takes several forms: neglect, beating, starvation, stabbing, zoophilia, burning, boiling, immersion in various substances, hanging, strangling, throwing an animal from upper floors, placing in a microwave oven, decapitation, alive skinning (Ciobotaru,2013).

The forms of passive abuse are the lack of food and water, lack of shelter and lack of veterinary care (Munro, 2008).

MATERIALS AND METHODS

The period analyzed in this study was 2015-2018. During the aforementioned period, 41 dogs were included. The data, collected from a private veterinary practice, have been statistically processed and interpreted in 2018.

In order to characterize the type of abuse on neglected animals, the following methods were used: clinical evaluation (inspection, auscultation, palpation, percussion, temperature monitoring) and paraclinical examination: laboratory investigations (haematological and biochemical blood work), imaging diagnostic (ultrasound or x-ray).

Body condition have been assessed in order to objectively consider or exclude malnutrition. Thus, WSAVA Global Nutrition Committee standard have been used for assessment. The method is particularly suited to live animals, but it have been also applied on corpses. Regardless the state of animal (dead or alive), the values of body weight as well as body score have been compared with those of breed standard (Laflame, 1997; Merli, 1987; Mitranescu et al. 2017).

Another methods used in this study was the necropsy and histopathological investigation for tumoral lesions, as well as parasitological examination. Progression of clinical status of each animal have been followed until corresponding healing or death. Symptomatic or

etiological treatment was provided according to each case, involving surgical removal of tumors, followed by cytopathological or histopathological diagnosis, treatment of fractures and wounds, antiparasitic, antimycotic and antibiotic treatment, along with supportive medication.

RESULTS AND DISCUSSIONS

The main types of passive abuse, according to the literature are: lack of veterinary assistance, lack of adequate supervision and shelter and lack of food and water (Munro, 2008). The framing of the results obtained in this study and the percentage representation are shown in Figure 1.

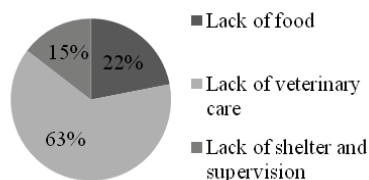


Figure 1 - Types of passive abuse

The lack of veterinary care is featured by all severe diseases, which are clearly visible (odor, swelling, bleeding, pain) as being in a very advanced stage of evolution and those where presentation to veterinarian for receiving medical help was not made at in very early stages of disease.

Gender had almost equal incidence in neglected animals, the difference between male and female being insignificant (Figure 2). The age presented small variations, many of the animals being over 8-year-old (figure 3).

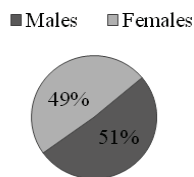


Figure 2 - The gender ratio

In terms of age, individuals under two years of age represented 19% of the studied animals (n = 8), those aged two to eight years accounted for 37% (n = 15), and those over eight years represented 44% of the sample (n = 18) as in Figure 3.

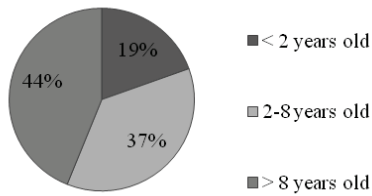


Figure 3 - The age of the subjects of the study

Lack of veterinary care- Neoplasia

Seventeen dogs were diagnosed with tumoral disease. Various actions have been taken for the animals with tumors (Figure 4). The following assessments have been done: CBC count, biochemical panel along with ultrasound and x-ray for assessing the clinical stage of disease. Surgical removal has been done subsequently in almost a half of animals followed by histopathological diagnosis. Animal examination must always note obvious signs, such as: odour, suppurative discharge associated with tumoral lesion, hemorrhage, and physical deformities due to excessive volume of tumor (Merck, 2007).

- Ablation
- Histopathological diagnosis
- Without intervention

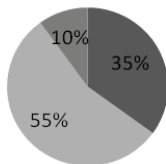


Figure 4 - The measures taken for diagnostic

Histopathological diagnosis revealed both benign tumors and malignant tumors, as well as various embryonic origin of tumors (Table 1).

Table 1. The origin and the type of analyzed tumors

Embryonic origin	Count	%	Type	Count	%
Mesenchymal	5	45	Malign	10	91
Epitelial	5	45	Benign	1	9
Neuroectodermal	1	10			

From the 11 samples collected and examined, there was 9% benign tumors identified (n = 1), and 91% (n = 10) of malignant tumors.

In the case of 53% (n=9) patient recovery was achieved, while 47% (n= 8) died of various reasons. (Figure 5).

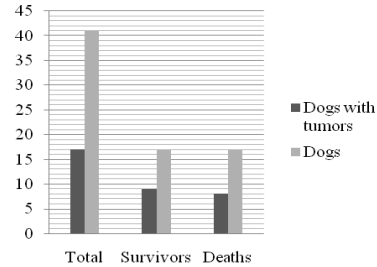


Figure 5 - The survival rate of the ones with tumors

Various causes of death were established after necropsy in dogs with tumors: postoperative complications, malnutrition, self-mutilation and associated traumatic shock, paraneoplastic syndrome and cardiopulmonary failure. Patient euthanasia was considered as final decision in irrecoverable cases, featured by impairment of basic physiological abilities or poor evolution of disease (inability to breathe or nourish properly, repeated recurrence of the tumoral process with concurrent tumoral invasion of nose and mouth), resulting in poor life quality (Table 2).

Table 2. The cause of death for individuals with tumors

Cause of death	Individuals
Complications	1
Self-mutilation	1
Malnutrition	2
Paraneoplastic disease	1
Euthanasia	2
Chronic disease	1

Lack of veterinary care- Fractures

Neglected fractures are also features of animal deprivation of proper medical care. The dogs with fractures have been treated by surgical approach (n=2, 4.9%). Follow-up of first case proved partial recovery caused by excessive callus formation (x-ray diagnosis). The second case have been presented with open fracture of forelimb, with complication such as skin and bone necrosis and severe secondary infection. The odour and the deformity were significant.

Both cases survived due to surgical and drug therapy.

The literature mentions the same findings in old, untreated fractures. Periosteal proliferation, which is the first step in external callus formation, may begin 24 hours after the fracture but is not grossly visible at that time. Primary mineralization of the callus occurs approximately in the first week post-fracture, being observed radiologically within 2 weeks. Older fractures present callus. The neglected fractures lead to skin lesions when the animal attempts to protect its affected area. The fracture site is contaminated with soft tissue and bone necrosis occurs (Munro, 2008).

Lack of veterinary care- Parasitic dermatitis

The results refers specifically to parasite dermatological conditions, such as demodicosis and sarcoptic mange, coexisting with various secondary infections (*Staphylococcus* spp., *Streptococcus* spp., *Candida albicans*, *Aspergillus* spp.). The patients with parasitic dermatitis were brought for medical care after a long period of time from the onset of clinical signs, along with localized or generalized pruritus and alopecia, as well as secondary infections. Complete healing after antiparasitic treatment was observed in all monitored cases (n=10, 24%) with disappearance of characteristic symptoms. Long-lasting treatment protocol has been applied, adapted to etiological agent, those being either *Demodex canis* or *Sarcoptes scabies*.

The literature mentions that demodicosis is often associated with cases of neglect, generalized demodicosis being fatal if left untreated (Merck, 2007).

Lack of veterinary care- Myiasis

The dogs (n=2, 4.9%) that arrived in the clinic have presented various wounds associated with wound peripheral congestion, necrosis, and subcutaneous myiasis at various stages of evolution, shock, expressed as semi-conscious state and even to unconsciousness. One of cases was older than eight years of age, and the other younger. None of those two patients could be saved because of the extensions of the lesions and complications.

Forensic entomology could be of value in determining the length of time of neglect in such cases (Merck, 2007).

The neglect of the owner has a major role in the onset of myiasis, as it seemed to be the result of an unhealed wound, as well as the dirty hair along with the presence of feces. The onset of myiasis is favoured by some mandatory conditions: wounds that results in blood clot, necrotic tissue, feces or urine that will attract flies. Moreover, the animal must be somewhat helpless and incapable of cleaning (elderly, debilitated). Consequently, rapid cleaning of any injury and proper medical care will greatly reduce the risk of infestation. The risk is further increased if the animal spends most of its life outdoor (Anderson et al., 2004).

In our study, myiasis was framed as secondary complication of wounds. The owners have declared that bite wounds have been noticed, days or even a week before medical examination. The animal had been bitten by dogs of the same family, or of the neighbor, lacking immediate veterinary assistance, although the patients have presented lack of appetite, apathy and prolonged lateral decubitus.

Lack of supervision and shelter

Lack of supervision results in high possibility of bite wounds produced by congeners, varying in intensity, as well as wounds induced by contact with a very tight collar (Munro, 2008). Six patients (n=6, 15%) have been examined, each presenting various conditions resulting from lack of shelter and supervision. Some of them (n=2) were sheltered in heterogeneous groups, with no regard for age or personality. Survival rate reached 50% of cases (n=3), being concurrent with the same number of deaths, induced by traumatic shock and other medical conditions, such as stage four dirofilariasis.

Some of the wound have featured epidermolysis in the cases were the collar was too tight. The bite wounds were followed by skin necrosis. Survivors have shown some symptoms attributable to posttraumatic shock, like trembling, hiding in the back of the cage, barking, drinking and eating only when alone, this characteristic behavior being induced by various stimuli (other dogs, noises, people).

The literature states that collars can cause severe infection and serious disfigurement of the neck, and the infection can eventually result in septicemia (Merck, 2007).

Lack of food-Malnutrition

The issue of improper feeding resulting in malnutrition may be considered an act of animal cruelty. Starvation can be caused by food deprivation, poor quality food, inappropriate food, intermittent feeding, or a lack of appetite which is often due to underlying disease (Merck, 2007). Other definitions states that malnutrition is the condition that occurs when a diet supply nutrients were given in insufficient amounts (Mitrănescu et al., 2017) malnutrition or inadequate feeding occurring as a result of insufficient or deficient food intake, or due to poor digestion or poor nutrient assimilation (Munro,2008).

Animals with advanced malnutrition status (BCS 1, BCS 2) were presented in this condition due to the lack of food, impossibility of moving to a food source (multiple fractures) and cancer cachexia. The aforementioned situations have been framed as passive abuse, since in all the cases observed (n=8, 20%), early presentation to the veterinarian along with food intake would have improved the body and health condition of those animals. The two cases in which the death occurred, were co-associated with neoplastic causes.

The clinical aspects of malnutrition were exhaustion, the animals could not maintain posture, along with persistent lateral decubitus. Ribs were easily palpable with minimal fat covering; the lumbar vertebrae were obvious; obvious waist has been seen behind ribs and minimal abdominal fat was observed.

Biochemical tests can be useful in detecting malnutrition in clinical practice, but difficult to interpret in the context of hepatic disease (Merli et al., 1987). The biochemical parameters have been observed in dogs with protein-deficient diet and they have confirmed that dogs were in a state of protein malnutrition as they fell below the reference range and presented significantly different values of urea, serum albumin and total serum protein. The subcutaneous connective tissue presented reduced adipose tissue, and skin wrinkled after

dehydration. Protein deficiency determines the presence of a rough, dry hair coat. Muscular mass atrophy occurs at monogastric at 24 hours of starvation. The spinal and thigh muscles are first affected and then the process expands (Munro, 2008).

CONCLUSIONS

There have been 41 cases of neglect (passive abuse), framed in following categories: lack of veterinary assistance, lack of adequate supervision and shelter and lack of food and water.

Advanced stages or terminal tumoral diseases, severe parasitic dermatitis, deprivation of shelter and supervision malnutrition were conditions with the highest incidence in this study.

Two or more types of passive abuse occurred concurrently represented by lack of veterinary care, lack of food or lack of shelter and adequate supervision.

Death occurred in 30% (n=12) of cases, following consecutive complications.

The highest incidence of abuse was observed in animals that aged more than 8 years (44%).

Partial or total recovery of animals was found in 70% of cases (n=29).

REFERENCES

- Anderson G.S., Huitson N.R. (2004). Myiasis in pet animals in British Columbia: The potential of forensic entomology for determining duration of possible neglect, *Can Vet J* 45(12), 993–998
- Bell L. (2001) Abusing children, – Abusing animals, *Journal of Social Work*, 1(2), 223-234.
- Ciobotaru E. (2013). *Medicină legală veterinară*, Ed. Ceres, Bucharest, Romania.
- Laflamme D. (1997).Development and validation of a body condition score system for dogs. *Canine Practice*, 22(4):10-15
- Levitt L., Hoffer T.A., Loper A.B. (2016). Criminal histories of a subsample of animal cruelty offenders, in *Aggression and Violent Behavior*, Elsevier, 30, 48-58
- Livingston, M. (2001). Desecrating the Ark:Animal abuse and the law's role in prevention. *Iowa Law Review*, 87, 7–72
- Merck M.D. (2007),*Veterinary forensic: Animal Cruelty Investigations*, Second Edition, Wiley-Blackwell, 207-233
- Merli M, Romiti A, Riggio O, Capocaccia L. (1987). Optimal nutritional indexes in chronic liver disease. *JPEN J Parenter Enteral Nutr*. Sep-Oct, 11

Mitrănescu E., Furnaris F. (2017). *Managementul bunăstării animalelor*, Ed Printech, București , 200-222

Munro R.,Munro H.M.C. (2008). *Animal abuse and unlawful killing*, Elsevier Publishing, 17-29

***Legea 60 din 24 Martie 2004 privind ratificarea Convenției Europene pentru protecția animalelor, *Monitorul Oficial*.nr. 400 din 5 Mai 2004

***Legea 205 din 26 mai 2004 privind protecția animalelor, *Monitorul Oficial* nr. 531 din 14 Iunie 2004

***Legea 9/2008 privind modificările și adăugările la Legea. 205/2004 privind protecția animalelor, *Monitorul Oficial* nr. 29 din 15 Ianuarie 2008.

***Body Condition Score, WSAVA Global Nutrition Committee, www.wsava.org.

STUDY ON CHANGES IN HAEMATOLOGICAL PARAMETERS FOLLOWING ADMINISTRATION OF NSAIDs IN DOGS

Ionuț Răzvan DOBRE, Diana Mihaela ALEXANDRU, Maria CRIVINEANU

University of Agronomic Sciences and Veterinary Medicine of Bucharest, 59 Marasti Blvd,
District 1, Bucharest, Romania

Corresponding author email: drrazvandobre@gmail.com

Abstract

NSAIDs have the ability to suppress the inflammatory process. They have antithrombotic action at low doses, analgesic and antipyretic action at medium doses and anti-inflammatory effects at elevated doses. Whereas the beneficial effects of NSAIDs are often overshadowed by the adverse effects, the aim of the study is to track side effects on hematology parameters after administration of anti-inflammatory NSAIDs in dogs. The study was performed on 8 dogs, male and female, of different races and ages, to whom were administered Flunixin, Metacam and Carprofen. The side effects on haematological parameters were observed and analyzed, when given medication as prescribed. In the case of Flunixin, increased white blood cell counts and decreased number of red blood cells, hematocrit have been observed. Metacam and Carprofen caused a lower decrease in hematocrit and red blood cell counts, as well as increased leucocyte counts. In all cases, a decrease in platelet count and a prolongation of prothrombin time were observed. This study conducted to the conclusion that the substances used didn't cause significant haematological changes, at the same time having a constant antithrombotic action and favouring coagulopathies.

Key words: NSAIDs, dog, osteoarthritis, haematological parameters.

INTRODUCTION

Anti-inflammatory, analgesic and antipyretic drugs comprise a heterogeneous group of compounds with different chemical structure but with similar pharmacological effects and side effects (KuKanich et al., 2012).

All drugs in this group associate, in varying proportions, analgesic, anti-inflammatory and antipyretic actions. These can be used either as symptomatic drugs in fever and pain conditions, or for anti-inflammatory action in rheumatic conditions (Jones et al., 2002; Watson et al., 1996).

The actions of these substances are attributed to the metabolic effect of diminishing prostaglandin synthesis as a consequence of cyclooxygenase inhibition. Cyclooxygenase is the enzyme which catalyses the oxidative cyclization of arachidonic acid with the formation of cyclic endoperoxides, which are precursors of prostaglandins, thromboxanes and prostacyclin (Lascelles et al., 1998).

Recent data has indicated that cyclooxygenase, which is the central enzyme of prostanoid biosynthesis, exists in two forms: COX₁ and COX₂. COX₁ is present in normal tissues and

involved in the formation of prostaglandins that protect the stomach and intestinal mucosa against the harmful effects of gastric acid, promotes blood clotting by activating platelets and maintains good kidney function (Ngo & Addison, 2018; Wallace et al., 1990).

COX₂ plays a role in the secretion of prostaglandins involved in inflammation, pain and fever, is present in all inflamed tissues and its formation is induced by cytokines (Bree et al., 1994).

Classical non-steroidal anti-inflammatory drugs inhibit both types of cyclooxygenases (COX₂ inhibition justifies pharmacodynamic effects while inhibition of COX₁ induces most adverse effects). They are commonly used to treat orthopedic problems in dogs but at the same time they are account for about 8% of all officially recorded intoxications (Dharmaceelan et al., 2018).

Recently, non-steroidal anti-inflammatory drugs have been synthesized that selectively inhibit COX₂, thus achieving the desired pharmacodynamic effects with minimal adverse reactions (Luna et al., 2007; McCann et al., 2004).

The anti-inflammatory effect of these substances is proportional to the cyclooxygenase inhibitory capacity (Borer et al., 2003).

The purpose of the study was to monitor the clinical effects and possible adverse reactions following the use in the therapy of osteoarticular disorders of non-steroidal anti-inflammatory drugs. Studies conducted so far in dogs have shown that side effects are minimal in this species, being mainly due to digestive disorders and very rare nephrotoxicity.

MATERIALS AND METHODS

The experiment was performed in a veterinary clinic and the haematological examination in the laboratory of the Faculty of Veterinary Medicine in Bucharest. The study was conducted on 8 cases of dogs, males and females of different ages, who after clinical and paraclinical examinations were diagnosed with different orthopedic problems.

Non-steroidal anti-inflammatory drugs used to study haematological changes following administration in dogs were:

- Flunixin (Flunixin meglumine), 100 ml vials containing 50 mg flunixin meglumine / ml.
- Metacam (Meloxicam), 100 ml suspension for oral administration containing 5 mg meloxicam / ml.
- Rimadyl (Carprofen), vials with 20 ml of oily suspension for injection containing 50 mg carprofen / ml.

Flunixin meglumine is part of the carboxyl group and the administration period

recommended by the manufacturer for dogs is 5 days (Erdogan et al., 2003).

Metacam (meloxicam) belongs to the group of enolic acids and Carprofen belongs to the group of carboxylic acids. These two preparations may be administered for a longer period of time (Doig et al., 2000).

Secondary effects (haematological changes) were observed under non-steroidal anti-inflammatory drug therapy using the therapeutic dose.

The three non-steroidal anti-inflammatory drugs used were administered as follows:

- flunixin meglumine was administered subcutaneously at the dose of 1.1 mg / kg for 7 days;
- meloxicam was orally administered at a dose of 0.1 mg / kg for 30 days;
- carprofen was administered subcutaneously at the dose of 4 mg / kg for 30 days.

In all cases, anti-inflammatory substances have been administered as a single therapy without resorting to association with other medicinal products.

Prior to drug administration, 7 days after flunixin meglumine administration, 15 and 30 days after Carprofen and Meloxicam administration blood samples were taken from all subjects in order to determine hemoglobin, hematocrit, number of red blood cells, leukocytes, platelets, reticulocytes, leukocyte formula and prothrombin time (Quick).

RESULTS AND DISCUSSIONS

Following the haematological examinations performed, the following results were obtained, as shown in Tables 1, 2 and 3:

Table 1. The average values of hematology parameters in dogs following administration of Flunixin meglumine

Parameters	Reference values	Before treatment	7 days after treatment
Hemoglobin (g/dl)	12-18	14.60	13.80
Hematocrit (%)	37-55	46.70	44.60
RBC count	5.5-8.5 x 1,000,000	4,948,000	4,760,000
Platelets count	1.75-5 x 100,000	255,300	310,400
Reticulocyte (%)	0-1.5	12.5	24.5
Leukocytes count	6-17 x 1,000	11,240	12,100
Neutrophils (%)	3.6-11.5 x 1000	54.8	61.2
Eosinophils (%)	0.01-1.25 x 1000	3.4	2.2
Basophils (%)	0.0-0.3 x 1000	2.7	2
Lymphocytes (%)	1.0-4.8 x 1000	29.1	27.3
Monocytes (%)	0.15-1.35 x 1000	9.9	7.2
Quick time (seconds)	11-17	13.6	14.8

Table 2. The average values of hematology parameters in dogs following administration of Meloxicam

Parameters	Reference values	Before treatment	15 days after treatment	30 days after treatment
Hemoglobin (g/dl)	12-18	14.54	13.35	13.24
Hematocrit (%)	37-55	49.6	43.8	45.6
RBC count	5.5-8.5 x 1,000,000	4,772,000	4,672,000	4,770,000
Platelets count	1.75-5 x 100,000	164,000	192,200	247,000
Reticulocyte (%)	0-1.5	15.8	28.6	31.3
Leukocytes count	6-17 x 1,000	10,800	11,630	12,350
Neutrophils (%)	3.6-11.5 x 1000	61.6	59.2	52.6
Eosinophils (%)	0.01-1.25 x 1000	6.3	6.1	6.9
Basophils (%)	0.0-0.3 x 1000	0	0	0
Lymphocytes (%)	1.0-4.8 x 1000	27.4	31	34
Monocytes (%)	0.15-1.35 x 1000	4.6	3.6	6.4
Quick time (seconds)	11-17	11.4	13.6	14.4

Table 3. The average values of hematology parameters in dogs following administration of Carprofen

Parameters	Reference values	Before treatment	15 days after treatment	30 days after treatment
Hemoglobin (g/dl)	12-18	15.35	15.22	13.85
Hematocrit (%)	37-55	47.8	47	45.4
RBC count	5.5-8.5 x 1,000,000	4,884,000	4,866,000	4,714,000
Platelets count	1.75-5 x 100,000	174,000	190,000	305,000
Reticulocyte (%)	0-1.5	11.25	18.8	29
Leukocytes count	6-17 x 1,000	7,940	8,360	10,460
Neutrophils (%)	3.6-11.5 x 1000	51.6	53.4	63.2
Eosinophils (%)	0.01-1.25 x 1000	5.2	6.1	5.8
Basophils (%)	0.0-0.3 x 1000	0	0	0
Lymphocytes (%)	1.0-4.8 x 1000	37.3	36	27.7
Monocytes (%)	0.15-1.35 x 1000	5.8	4.4	3.2
Quick time (seconds)	11-17	11.11	13.2	15.2

When flunixin meglumine was administered to dogs with various osteoarticular disorders, were observed a decrease in hematocrit and number of red blood cells, increased white blood cell counts, increased neutrophil count and decreased lymphocytes, and a significant increase in platelet count and prothrombin time (Quick).

Following administration of Meloxicam resulted in a more pronounced decrease in hematocrit compared to the Flunixin administration, increased platelet count and leucocyte counts, neutrophil decrease and lymphocyte growth and a slight increase in Quick Time.

Following the administration of Carprofen to dogs with osteoarticular disorders, were observed a slight decrease in hematocrit and number of red blood cells, significant increase in platelet counts, increased white blood cell count and neutrophil count, decreased lymphocyte count and prolonged Quick Coagulation Time.

Of all the investigated animals with osteoarthritis at various stages, hematological

parameters following administration of non-steroidal anti-inflammatory drugs, determined at different time intervals from the start of treatment, experienced greater or smaller variations as can be seen from the following graphs (Figures 1, 2, 3, 4, 5 and 6).

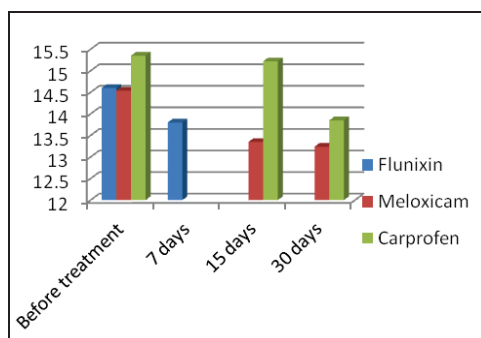


Figure 1. Average hemoglobin values during treatment with the three products

It is noted that all average values of hemoglobin remain within the reference limits,

with a more pronounced decrease in Meloxicam and Carprofen products.

All average hematocrit values are within the reference limits, a more significant variation being observed for meloxicam.

The average number of red blood cells is slightly below the reference range, with no significant variation in the time of therapy with these pharmaceuticals.

The average number of red blood cells is slightly below the reference range, with no significant variation in the time of therapy with these pharmaceuticals.

Average platelets values remain throughout the study within the reference limits, the slight increase had no clinical significance.

Likewise, leukocytes are placed within the reference range at all times of the assay, the growth trend being not significant.

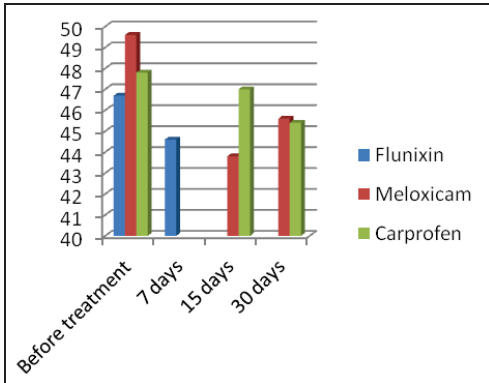


Figure 2. Average values of hematocrit during the studied period

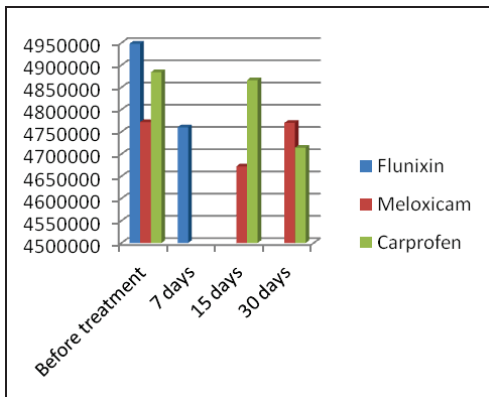


Figure 3. Average values of red blood cells during the study

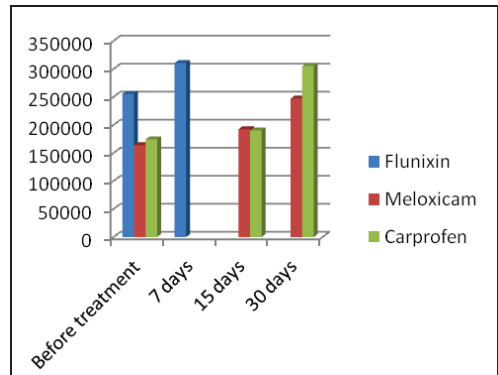


Figure 4. Average platelet values during the study period

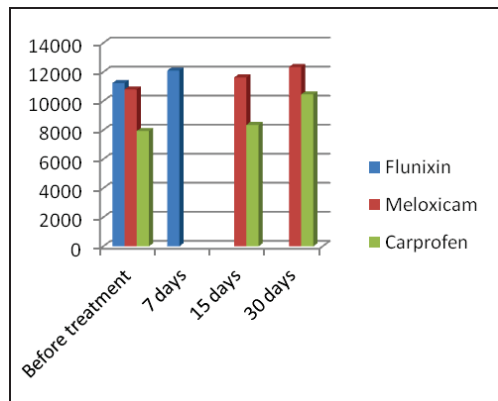


Figure 5. The average values of leukocytes during the administration of the anti-inflammatory drugs studied

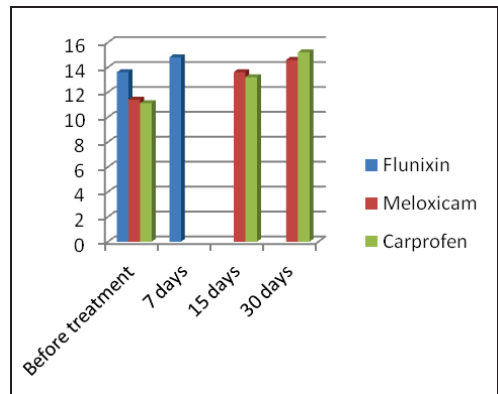


Figure 6. Average values of prothrombin time (Quick) during the study period

In the case of prothrombin time, it is placed in the reference range until the last determination but, in all cases, a trend of prolongation (coagulopathy tendency) is observed.

CONCLUSIONS

The experiment conducted on a number of 8 dogs with osteoarticular disease followed the hematological side effects of 3 NSAIDs with different chemical structures and similar action mechanisms.

From the determinations made with the three substances, there is a constant increase in the prothrombin time (coagulopathy) and insignificant alterations of the other parameters. Comparative study of changes in haematological parameters in the use of the 3 substances showed that the least changes occurred with the use of flunixin meglumine followed by carprofen and meloxicam.

Studies have shown that preparations of the non-steroidal anti-inflammatory drug used in dogs do not cause obvious haematological changes.

REFERENCES

- Borer, L.R., Peel, J.E., Seewald, W., Schawalter, P., & Spreng, D.E. (2003). Effect of carprofen, etodolac, meloxicam, or butorphanol in dogs with induced acute synovitis. *American journal of veterinary research*, 64(11). 1429-1437.
- Bree, H. Van, Justus, C., Quirke, J.F. (1994). Preliminary observation on the effects of meloxicam in a new model for acute intraarticular inflammation in dogs. *Veterinary Research Communication*, 18(3). 217-224.
- Dharmaceelan, S., Manikandan, R., Jayakumar, K., Senthilkumar, S., & Selvaraj, P. (2018). Haemato-biochemical alterations and stress response to pre-emptive administration of meloxicam, ketoprofen, tolfenamic acid and flunixin in dogs. *The Pharma Innovation Journal*, 7(11). 218-221.
- Doig, P.A., Purbrik, K.A., Hare, H.F., Mc Keown, D.B. (2000). Clinical efficacy and tolerance of meloxicam in dogs with chronic osteoarthritis. *Canadian Veterinary Journal*, 4(4). 296-300.
- Erdogan, H.M., Gunes, V., Gorkce, H.I., Uzun, M., Cital, M., Yuksek, N. (2003). Effects of prolonged intravenous of flunixin meglumine in healthy dogs. *Acta Veterinaria Brno*, 72(1). 71-78.
- Jones, C.J., Streppa, H.K., Harmon, B.G., Budsberg, S.C. (2002). In vivo effects of meloxicam and aspirin on blood gastric mucosal and synovial fluid prostanoid synthesis in dogs. *American Journal of Veterinary Research*, 63(11). 1527-1531.
- KuKanich, B., Bidgood, T., & Knesl, O. (2012). Clinical pharmacology of nonsteroidal anti-inflammatory drugs in dogs. *Veterinary anaesthesia and analgesia*, 39(1). 69-90.
- Lascelles, B.D.X., Cripps, P.J., Jones, A., Waterman-Pearson, A.F. (1998). Efficacy of kinetics carprofen administered preoperatively or postoperatively, for the prevention of pain in dogs undergoing ovariohysterotomy. *Veterinary Surgery*, 27(6). 568-582.
- Luna, S.P., Basílio, A.C., Steagall, P.V., Machado, L.P., Moutinho, F.Q., Takahira, R.K., & Brandão, C.V. (2007). Evaluation of adverse effects of long-term oral administration of carprofen, etodolac, flunixin meglumine, ketoprofen, and meloxicam in dogs. *American journal of veterinary research*, 68(3). 258-264.
- McCann, M.E., Donald, R., Zhang, D., Brideau, C., Black, W.C., Hanson, P.D., & Hickey, G.J. (2004). In vitro effects and in vivo efficacy of a novel cyclooxygenase-2 inhibitor in dogs with experimentally induced synovitis. *American journal of veterinary research*, 65(4). 503-512.
- Ngo, S.N., & Addison, C.J. (2018). Are COX-2 Selective NSAIDs Associated with Less GI, Renal, and Cardiovascular Side Effects: Evidence from Animals Treated with NSAIDs. *Annual Research & Review in Biology*, 1-8.
- Wallace, M.S., Zawie, D.A., Garvey M.S. (1990). Gastric ulceration in the dog secondary to use of nonsteroidal anti-inflammatory drugs. *J. Am. Anim. Hosp. Assoc.*, 26. 467-472.
- Watson, A.D.J., Nicholson, A., Church, D.B., & Pearson, M.R.B. (1996). Use of anti-inflammatory and analgesic drugs in dogs and cats. *Australian veterinary journal*, 74(3). 203-210.

INVESTIGATIONS REGARDING THE PARTICULARITIES OF NON-SPECIFIC RESISTANCE AT NEONATAL CALVES

Rita GOLBAN

State Agrarian University of Moldova, 42 Mircești Street,
Chișinău, Republic of Moldova

Corresponding author email: golbanrita@gmail.com

Abstract

The scientific investigations revealed in this research present the study in dynamics of blood immunological indices characteristic to non-specific resistance at the neonatal calves in different age periods. In the study are presented the aspects of these immunological indices, regarding their correlation in determining the cellular and humoral immunity. Important data reveal the correlation of the concentration of lymphocytic, leukocyte indices, the phagocytic, lysozyme and bactericidal activity, which justifies the importance of nonspecific humoral resistance of the newborn organism, which denotes the assimilation of antibodies by colostrum during the neonatal period as a result of the installation of colostrum immunity.

The initiation of these studies has demonstrated the importance of nonspecific or inborn immunity, constituting the first line of defense against pathogenic microbial agents at newborn animals.

Key words: non-specific resistance, phagocytosis, lysozyme, bactericidal activity.

INTRODUCTION

Non-specific resistance at the neonatal calves comprises many factors and mechanisms. It is well known, that the organism is defending through the skin integrity and through the mucous which acts as anatomical barriers to microbial invasion, and through diverse physiological mechanisms (Golban, 2015; Horhoge, 2015).

Many studies confirm the importance of immunoglobulins in mucosal secretion, out of which a specific interest is to immunoglobulin with protective, anti-infective IgA role. The normal microbial flora of both the skin and the mucous membrane is defended by a normal microbial microflora - saprophyte, consisting of non-pathogenic microbes, which prevents the pathogenic microbes from multiplying and penetrating into the body (Siloși, 2014).

Remarkably, in the non-specific resistance processes at neonatal animals, is presented an important mechanism of defense of the organism against infection - phagocytosis, the action of which is expressed by incorporation and destruction - the digestion of microbes by leucocytes, especially the cells of the reticulo endothelial system (Broca, 2013; Gâjâilă, 2002).

The bibliographic data denotes important aspects, regarding the importance of the anti-infective protection system, complement, which intervenes in the destruction of the germs that have entered in the blood. This humoral factor of nonspecific natural resistance gives the blood a bactericidal power and prevents the multiplication of microbes that have entered into the blood.

The age is another factor, meaning that infant calves have a "immaturity" in anti-infective defenses (Rosen, 2008; Tașbac, 2014).

Therefore, the non-specific or inborn immunity provides the first line of defense against pathogenic microbial agents at newborn animals. It consists of immune, non-specific, rapid and equally intense immune responses, indifferent of the type of pathogen, which are rare enough to completely eliminate cellular microbial infections and lack of immunological memory or a lasting protective immunity (Gâjâilă, 2003).

Currently, a number of research shows that immune function is essential for the human and animal body and therefore severe immune dysfunctions are incompatible with survival. Therefore, inappropriate activation of immune function has the consequence of initiating or progression of pathological states of

hypersensitivity and autoimmune diseases, which has shown interest in this study. For this reason, the objectives of these researches were to study the specificities of non-specific resistance in neonatal calves (Christopher et al., 2008; Andrieş et al., 2014).

MATERIALS AND METHODS

The investigations were performed in the laboratory of microbiology of the Faculty of Veterinary Medicine of the Moldavian State Agrarian University and in the private laboratory Sinevo from Chisinau municipality. Blood samples were taken from newborn calves up to 30 days old to perform the investigations.

Blood samples were collected from the heparin jugular vein based on the calculation of 0.3 ml of heparin to 10 ml of blood for anticoagulation. The samples were used to identify the number of leukocytes, lymphocytes, the opsono-phagocytic test, lysozyme activity and bactericidal activity.

RESULTS AND DISCUSSIONS

The results of immunological immune system investigations on non-specific immunity at the newborn calves show that leucocytes, lymphocytes, phagocytic indices of bactericidal activity and lysozyme vary in different stages of the age of the animals (Table 1).

Significant results of the indices of leukocytes and lymphocytes were recorded in calves aged of 5 and 10 days, constituting values white blood cells, namely, 8.20 ± 0.81 and 7.90 ± 0.81 compared to values obtained from calves aged 20 and 30 days, where the indices constituted the level of 6.95 ± 0.81 and 7.35 ± 0.81 . At the same time, the number of lymphocytes was determined and assessed at newborn animals, which shows appreciable values at age 5 and 10 days, constituting 3.69 ± 0.81 and 3.71 ± 0.81 compared to calves aged 20 and 30 days constituting 3.90 ± 0.8 and 3.31 ± 0.81 .

The dynamics of these indices demonstrates that during neonatal period at 5-day old calves the phagocytic activity constituted 52.33 ± 0.60 , compared to the age of 10 days, which constituted 41.67 ± 0.65 , which denotes a decrease expressed by various aspects of

external factors that act on the newborn animal during the early days of life.

Table 1. Leukocyte and lymphocyte dynamics at neonatal calves depending on age, %

Age (days)	Leukocyte (thousands/mcl)	Lymphocyte (thousands/mcl)
5	8.20 ± 0.81	3.69 ± 0.81
10	7.90 ± 0.81	3.71 ± 0.81
20	6.95 ± 0.81	3.90 ± 0.81
30	7.35 ± 0.81	3.31 ± 0.81

The study of the immune defense mechanisms in the neonatal period at calves revealed various indices characteristic to phagocytic activity and intensity varying in different age groups. Thus, the indices of phagocytic activity in neonatal calves determined significant values at various age ranges (Table 2). These data indicate that animals have resistance to infectious germs.

Table 2.Indices on phagocytic activity at neonatal calves depending on age

Age	Phagocytic activity
5	52.33 ± 0.60
10	41.67 ± 0.65
20	38.56 ± 0.56
30	35.44 ± 0.47

Following the dynamics of phagocytic activity indices at the age of 20 and 30 days it was found that the values constituted 38.56 ± 0.56 and 35.44 ± 0.47 , fact which confirms the diminution of the phagocytic processes at these animals.

In the immunological aspect, it can be observed that the phagocytic activity during this period of life of the neonatal calves is attributed to the first level of neutrophils, the rest being made by macrophages.

Therefore, phagocytic mechanisms induce two-way phenomena that are dependent on bacterial resistance: the first pathway without opsonization through direct interaction between the phagocytic cell and the antigen; and the second pathway with opsonization constitutes the interaction that requires an additional opsonin molecule that acts as an adapter between bacteria and leukocyte. In this context, phagocytosis continues with adhesion, then with the phase in which the pseudopods surround the bacterium. The final stage of

destruction provides complete digestion of the bacterium.

Relevant data were recorded, regarding the phagocytic intensity of neonatal animals in different age periods (Table 3).

From the results, it can be observed that the phagocytic intensity at neonatal animals at the age of 5 and 10 days determined significant values of 2.32 ± 0.02 and 1.83 ± 0.01 compared to the animals aged of 20 and 30 days, where these values constituted 1.78 ± 0.01 and 1.57 ± 0.01 . Therefore, at neonatal animals the defense mechanisms are not triggered enough to protect the aggression of microorganisms, viruses and other pathogens.

Relevant data were recorded, regarding the phagocytic intensity of neonatal animals in different age periods (Table 3).

Table 3. Indices of phagocytic intensity at neonatal calves depending on age

Age	Phagocytic intensity
5	2.32 ± 0.02
10	1.83 ± 0.01
20	1.78 ± 0.01
30	1.57 ± 0.01

From the results, it can be observed that the phagocytic intensity at neonatal animals at the age of 5 days and 10 days determined significant values of 2.32 ± 0.02 and 1.83 ± 0.01 compared to the animals aged of 20 days and 30 days, where these values constituted 1.78 ± 0.01 and 1.57 ± 0.01 . Therefore, at neonatal animals the defense mechanisms are not triggered enough to protect the aggression of microorganisms, viruses and other pathogens

Table 4. Indices of bactericidal activity at neonatal calves depending on age

Age	Bactericidal activity
5	35.91 ± 0.44
10	36.00 ± 0.25
20	37.27 ± 0.27
30	42.18 ± 0.42

Table 4 shows that in the neonatal period at calves aged of 5 days the bactericidal activity was 35.91 ± 0.44 compared to the age of 10 days, which constituted 36.00 ± 0.25 , indicating an increase expressed by various aspects of humoral immunity that act on the newborn calf during the first few days of life

after colostrum feeding. Following the dynamics of bactericidal activity indices at 20 and 30 days of age, it was found that the values constituted 37.27 ± 0.27 and 42.18 ± 0.42 , which confirmed the establishment of newborn cow resistance and the installation of colostrum immunity.

Table 5. The level of lysozyme (%) in the serum of the neonatal calves serum depending on age

Age	Level of lysozyme
5	4.21 ± 0.01
10	4.32 ± 0.01
20	4.31 ± 0.01
30	4.14 ± 0.02

The analysis of the results related to the lysozyme activity at the neonatal calf serum (Table 5) shows that at the age of 5 days, the lysozyme level constituted 4.21 ± 0.01 compared to the age of 10 days, which constituted 4.32 ± 0.01 , indicating an increasing characteristic of the action of non-specific mechanisms, which contributes to the intervention of the neonatal animal organism protection. Following the dynamics of the lysozyme indices at the age of 20 days and 30 days it was found that the values constituted 4.31 ± 0.01 and 4.14 ± 0.02 , which confirms the decrease of the nonspecific resistance of the newborn calf.

These aspects interpret the insufficiency of the immune defense mechanisms by which they influence the animal organism.

In this context, the immune response is considered as a defense mechanism by which the body recognizes what is foreign to itself. Recognition of self as opposed to non-self is very precise and specific to each organism, therefore among the mechanisms that generate disease or favors chronicising an important role is played by the deregulation immune response expressed by the intervention of non-specific resistance factors on both the human and the animal body.

CONCLUSIONS

Non-specific immunity is the first line of defense against pathogenic microbial agents at neonatal calves. It consists of immune, non-specific, fast, and equally intense immune responses, regardless of the type of pathogen,

which are rare enough to completely eliminate microbial infections.

Evaluation of the mechanisms of non-specific resistance formation at the newborn animal organism provides the opportunity to follow the evolution of cellular and humoral responses that maintain immune homeostasis of the organism and are considered the principal in regulating the immune system.

There was an increase in lymphocytic, phagocytic, bactericidal and lysozyme activity over different periods of age by 1.19; 1.21; 1.26 and 1.3 times.

The study of the specific features of non-specific resistance at neonatal calves determined significant values in the appearance and decreasing of the development of cellular and humoral immunity, proving that the animal body recognizes what is alien to itself and is able to present its immunological defense mechanisms against various infections.

REFERENCES

- Andrieș L., Barba D., Cernățchi O., Stratan V. (2014). *Imunologie clinică*. Chișinău: Editura „Tipografia Centrală”. 556 p: ISBN 978-9975-53-383-6.
- Brokaw A. (2013). *Immunology: Use Howard Hughes Medical Institute Resources to Teach*. Ohio. 37 p. Disponibil: <http://www.hhmi.org/biointeractive/teacher-guide-immunology>.
- Christopher S., Baliga, Mary E., Paul. (2008). *HIV Infection and Acquired Immunodeficiency Syndrome*. In *Clinical Immunology. Principles and Practice*, Mosby, Elsevier, Third Edition, 571-582.
- Găjăilă G. (2002). *Imunologie analitică. Aspecte fundamentale și metodologice*. București: Editura „Printech”. 224p: ISBN 973-652-583-X.
- Găjăilă G. (2003). *Sistemul imunitar la suine*. București: Editura „Cartea Universitară”. 131 p. ISBN 973-86231-7-0.
- Golban R. (2015). *Imunologie și imunopatologie. Curs de prelegeri*, Chișinău: uasm.moodle.md ,UASM, 155p., 4,8 c.a.
- Horhoge C. (2015). *Imunologie și imunopatologie*. Iași: Editura „Ion Ionescu de la Brad”. 164 p. ISBN 978-973-147-185-3.
- Rosen R Hugo. (2008). *Transplantation Immunology: What the Clinician Needs to Know for Immunotherapy Gastroenterology*. 134 : 1789-180.
- Siloși I. (2014). *Imunologie*. Craiova: Editura „SITECH”. 266P. ISBN 978-606-11-3717-6.
- Tașbac A. (2014). *Îndrumar pentru laboratorul de imunologie veterinară*. București: Larisa, Câmpulung Muscel, 170p. ISBN 978-606-715-271-5.

DORSAL DISPLACEMENT OF THE SCAPULA IN A CAT – CASE REPORT

**Cornel IGNA, Roxana DASCALU, Bogdan SICOE,
Cristian ZAHA, Larisa SCHUSZLER**

Banat University of Agricultural Sciences and Veterinary Medicine, “King Michael I of Romania”,
from Timisoara, Faculty of Veterinary Medicine, 119 Calea Aradului, 300645, Timisoara, Romania

Corresponding author email: ignacornel@gmail.com

Abstract

Scapular luxation is an uncommon cause of forelimb lameness in cats. Dorsal dislocation of the scapula occurs by trauma, having a result a tearing of the muscular support for the scapula, the serratus ventralis, trapezius, and rhomboideus muscles. In this case report is presented the surgical management of dorsal scapula luxation in one adult cat. Dorso-caudal scapula approach (dissection of the infraspinatus muscle) was performed and a small portion of teres major muscle was elevated. Caudal scapular border was attached of the 5th rib with a cerclage wire and the torn edges of the trapezius and rhomboideus muscles were sutured. Postoperative pneumothorax was diagnosed and treated with thoracentesis and aspiration. Clinical outcome was considered good with resolution of lameness and normal scapular motion. Open reduction and internal fixation (scapulo-costal cerclage) represent one treatment option in dorsal scapular luxation in cats.

Key words: *cat, dorsal luxation, internal fixation, scapula.*

INTRODUCTION

Scapular luxation with dorsal dislocation in cats is a rare orthopaedic condition caused by trauma with tearing of muscles (serratus ventralis, trapezius, and rhomboideus muscles) that binds the scapula to the thoracic wall (Parker, 2003; Woss et al., 2009; Perry et al., 2012). Scapular luxation occurs more often in cats than in dogs, animals of any age and sex being affected (Schulz, 2013). Scapular luxation with dorsal luxation in cats also known as dorsal subluxation of the scapula usually occurs after jumps, falls or bites (Cagatay et al., 2018). The disease is clinically diagnosed (dorsal movement of the scapula during locomotion) and confirmed radiologically (Ozsoy & Guzel, 2013) or by computer tomography (Kano et al., 2013).

In the scientific literature, scapular luxation with dorsal dislocation in cats has been described in several books (Parker, 2003; Bordelon et al., 2005; Scott & Mc Laughlin, 2006; Woss et al., 2009; Drobats et al., 2011; Schulz, 2013), but information on the results of different surgical methods of treatment are relatively limited to only three cases for open reduction and internal fixation by scapulo-ribs

cerclage (Cagatay et al., 2018; Ozsoy & Guzel, 2013; Perry et al., 2012) and to six cases treated only by suturing the serratus and rhomboideus muscles to the infraspinatus and supraspinatus muscles (Ozer et al., 2017).

In the present study we present the surgical treatment by open reduction and internal fixation (scapulo-ribs cerclage) in a cat with dorsal scapular luxation.

MATERIALS AND METHODS

A 1-year old European domestic short hair intact male cat was presented in the Surgery Clinic of the Faculty of Veterinary Medicine from Timisoara with approximately 10 days history of thoracic limb lameness. Physical examination of the patient revealed a normothermic animal (38.6°C), heart rate of 117 bpm, respiratory rate of 23 bpm and which in resting position highlighted exaggerated left suprascapular cartilage (Figure 1) and in gait exhibited lameness. During the support phase of the affected limb there was a marked tendency of dorsal displacement of the left suprascapular cartilage, accompanied by an obvious detachment of the scapula from the thoracic wall.

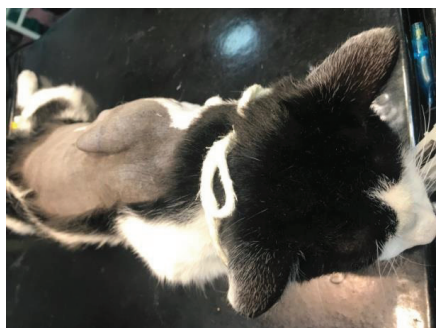


Figure 1. Appearance of the cat with dorsal scapular luxation

Clinical examination of affected limb did not reveal any swellings, ecchymosis or wounds, and no abnormal pain sensitivity. Adduction of the left leg induced lateral displacement of the scapula.

The cat did not show signs of respiratory failure and preoperative complete blood count (hemoleucogram) and blood chemistry (GOT, GPT, urea, creatinine, glucose, and total proteins) were normal. Tests for feline leukemia virus (FeLV) and feline immunodeficiency virus (FIV) were negative. The radiographic images (dorso-ventral and right-lateral – view) have revealed a dorsal left scapular luxation with no evidence of fracture of the scapula or lung atelectasis, emphysema or pneumothorax (Figure 2).

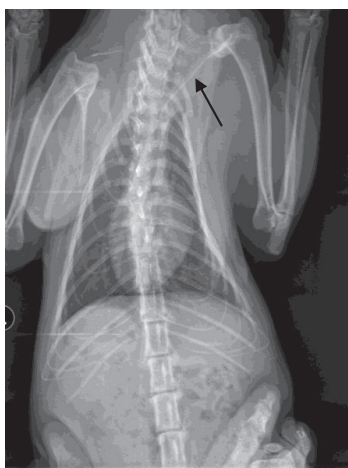


Figure 2. Radiographic image showing left scapulothoracic luxation with dorsal displacement (black arrow) and left scapula and left thoracic ribs with no signs of fracture

The surgical procedure was performed under general anaesthesia, which consisted of premedication with xylazine (1 mg/kg b.w., i.v.) and ketamine (5 mg/kg b.w., i.v.) followed by induction with propofol (3 mg/kg b.w., i.v.). General anaesthesia was maintained with isoflurane vaporized in oxygen using intermittent positive pressure ventilation. Postoperative analgesia was provided with one dose of butorphanol (0.4 mg/kg b.w., s.c.) administered 15 minutes before recovery. Ampicillin (20 mg/kg b.w., i.v.) was administered at induction and at the end of surgery.

The surgical site was aseptically prepared. The patient was placed in right lateral recumbency. Incision of the skin and subcutaneous tissue on dorso-caudal edge of the scapula and identification of the tears in the trapezius and rhomboideus muscles were the first surgical steps (Figure 3).

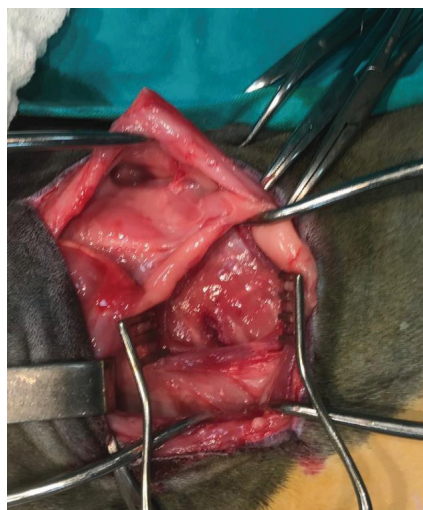

Figure 3. Identification of trapezius, rhomboideus and serratus ventralis muscles tearing

Dissection between the infraspinatus and teres major muscles allows highlighting of the caudal scapular edge and tears of the serratus ventralis muscle (Figure 3). On 5th left rib, the periosteum was elevated on a portion of about 0.5 cm and a loop of stainless steel wire (0.8 mm in diameter) was passed around the rib with caution to not enter the thorax (Figure 4).

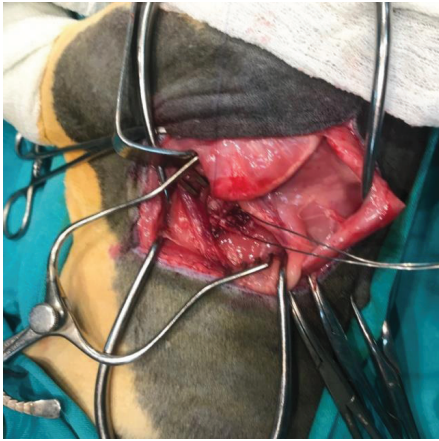


Figure 4. The stainless steel wire passed around the 5th rib

Through the scapula, beneath a 1 cm elevated portion of the teres major muscle insertion, two holes were drilled (Figure 5) through which the ends of the wire were passed and anchored to the 5th rib, and the wire was twisted on the lateral surface of the scapula.

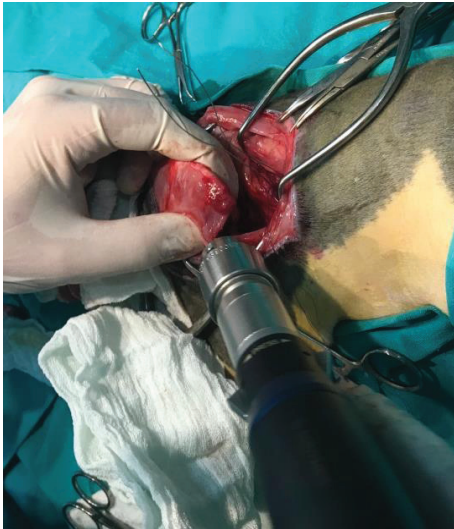

Figure 5. The holes drilled through the caudal edge of scapula

The teres major muscle was reattached to the scapula using the two holes drilled in its cranio-dorsal edge (Figure 6).

The trapezius and rhomboideus muscles were reattached to the scapular spine by interrupted sutures, using 2.0 metric polyglactin 910 (PGA, Biosintex) (Figure 7).

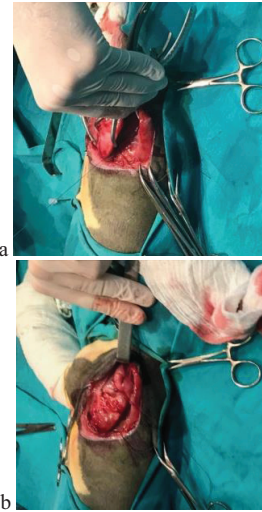

Figure 6. Reattachment through suture of the teres major muscle (a) at the cranio-dorsal edge of the scapula (b)

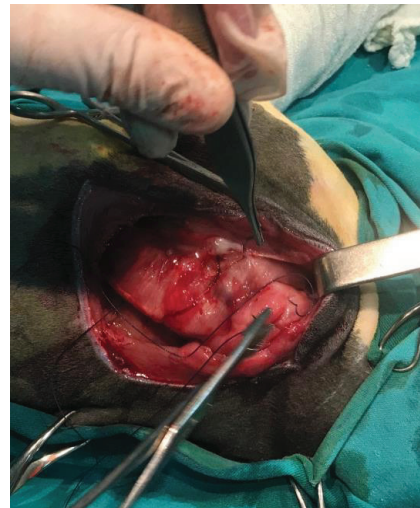

Figure 7. Suturing the tears in the trapezius and rhomboideus muscles

The subcutaneous fascia was closed in a simple continuous pattern, using 1.5 metric polyglactin 910 (PGA, Biosintex) thread. The skin was closed with simple interrupted sutures using 2.0 metric polypropylene (Prolene, Ethicon).

Postoperative, a radiograph was performed to check the metallic wire placement and the possibility of iatrogenic pneumothorax appearance (Figure 8). The operated limb was immobilized for the next 8 days using a Velpeau sling.

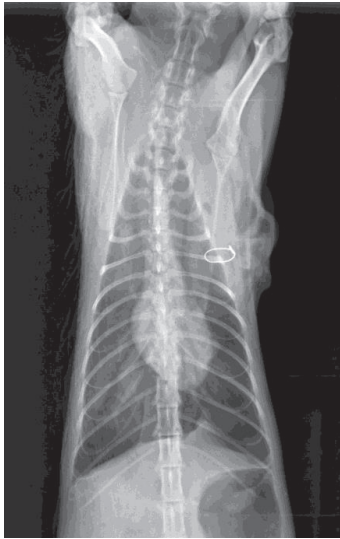


Figure 8. Immediate postoperative dorso-ventral radiography

RESULTS AND DISCUSSIONS

In the postoperative radiography (Figure 8) a pneumothorax was diagnosed probably produced intraoperatively by iatrogenic causes. This complication probably occurred when the metallic wire was passed around the Vth rib. Postoperative pneumothorax was treated with thoracentesis and aspiration two times a day for 4 days. There was no subcutaneous emphysema. Prophylaxis of possible septic complications was made using Ampicillin (20 mg/kg b.w., i.v.) every 12 h for 5 days postoperative.

The Velpeau sling was changed daily, for the next 8 days, to inspect and perform antisepsis of the surgical wound and to check the patient's locomotion. The cat resumed its locomotion in the next postoperative day, placing the operated limb in light contact with the ground and has continued to do so for the first three days after surgery. One week later, a slight lameness during walking was observed (1-2 level), without scapular dislocation.

Skin sutures were removed at 8th postoperative day. Two weeks postoperative, the cat presented a normal gait without signs of lameness. No other postoperative complications were observed.

At three months postoperative, the animal had a normal behaviour and locomotion, the owner

did not tell about possible (Ozer et al., 2017) pain episodes or lameness as a reaction to the implanted metal wire.

Various methods are available for the treatment of dorsal scapular luxation.

In cats with displacement of the scapula after recent trauma, closed reduction and immobilization for 2-3 weeks using a Velpeau sling is sufficient (Bordelon et al., 2005).

Due to the fact that displacement of the scapula occurs secondary to traumatic disruption of the serratus ventralis muscle, and the serratus ventralis muscle is the primary supporting muscle of the scapula to the thorax (Pick, 2012; Parker, 2003), the scientific literature also presents two techniques of open reduction of scapular luxation in cats.

One technique is to fix the ruptured muscles and re-attach them to the scapula - the ruptured section of the serratus ventralis muscle was pulled across the lateral surface of the scapula and sutured to the supraspinatus and infraspinatus muscles using horizontal mattress sutures, and the rhomboideus muscle was pulled over the scapular cartilage and sutured to the infraspinatus muscle using horizontal mattress sutures (Ozer et al., 2017). This procedure has been reported to fail to achieve sufficient stabilization for the extremity to bear weight (Johnson & Hulse, 2002).

Another method is to restore the scapula to its normal anatomical position and attach it to the ribs (Cagatay et al., 2018; Schulz, 2011; Ozsoy & Guzel, 2013; Perry et al., 2012; Woss et al., 2009) combined with reconstruction of the serratus ventralis muscle re-attached in the holes drilled in the cranio-dorsal edge of the scapula (Piermattei et al., 2006; DeCamp et al., 2016). This technique has the possibility of causing intercostal muscle ruptures, subcutaneous emphysema and breathing difficulties due to the cerclage wire passed around the rib (Ozer et al., 2017).

In our case, we preferred to restore the scapula to its normal anatomical position and attach it to the ribs, re-attach the serratus ventralis muscle in the holes drilled in the cranio-dorsal edge of the scapula and re-attach the rhomboideus and trapezius muscles to the scapular spine, which provides a good functional outcome.

There are several limitations to this report. The absence of a larger number of cases did not allow us to verify the fact that the surgical technique applied by us is superior to other conservative or surgical methods described by the scientific literature.

CONCLUSIONS

Open reduction and internal fixation (scapular-rib cerclage) represents a treatment option in dorsal scapular luxations in cats.

Clinical outcome was considered good with resolution of lameness and normal scapular motion.

ACKNOWLEDGEMENTS

This study was realised using the support and infrastructure project "Dezvoltarea infrastructurii de cercetare, educație și servicii în domeniile medicinei veterinare și tehnologiilor inovative pentru RO 05", cod SMIS-CSNR 2669.

REFERENCES

Bordelon, J. T., Reaugh, H. F., Rochat, M. C. (2005). Traumatic luxations of the appendicular skeleton. *Veterinary Clinics: Small Animal Practice*, 35(5). 1169-1194.

Çağatay, S., Sağlam, M., Pilli, M. (2018). Dorsal scapular luxation and its surgical treatment in a cat. *Vet Hekim Der Derg.*, 89(1). 92-96.

DeCamp, C. E., Johnston, S. A., Dejardin, L. M., Schaefer, S. L (2016) The shoulder joint. In: C. E. DeCamp, S. A. Johnston, L. M. Dejardin, S. L. Schaefer (Eds), *Brinker, Piermattei, and Flo's*

Handbook of Small Animal Orthopedics and Fracture Repair. Fifth edn., (pp. 260-297). Missouri: Elsevier.

Drobatz K. J., Beal W. M., Syring S. R. (2011). *Manual of Trauma Management in the Dog and Cat*. Oxford, John Wiley & Sons.

Johnson, A. L., Hulse, D. A. (2002). Diseases of joints. In: T. W. Fossum (Ed): *Small Animal Surgery*. 2nd edn., (pp. 1023-1150). China: Mosby.

Kano, W. T., Rahal, S. C., Mesquita, L. R., Faria L. G. (2013). Gait analysis in a cat with scapular luxation and contralateral fore limb amputation. *Can. Vet. J.*, 54. 990-991.

Özer, K., Karabağlı, M., Ömer, H., Demir, M. E. (2017). Surgical treatment of dorsal scapular luxation in cats: 6 cases (2010-2016). *Kafkas Univ Vet Fak Derg.*, 23. 503-506.

Özsoy, S., & Güzel, Ö. (2013). Dorsal luksasyon of the scapula in a cat. *Turk. J. Vet. Anim. Sci.*, 37. 618-620.

Parker, R. B. (2003). Scapula. In: D. Slatter (Ed.), *Textbook of small animal surgery*. 3rd ed. (pp 1896–1897). Philadelphia: Saunders Elsevier.

Peck J. (2012). Scapula. In: K. M. Tobias, S. A. Johnson (Ed.). *Veterinary Surgery: Small Animal*. Volume 1. (pp. 690-691). St. Louis. Missouri: Saunders.

Perry, K. L., Lam, R., Rutherford, L., Arthurs, G. I. (2012). A case of scapular avulsion with concomitant scapular fracture in a cat. *Journal of feline medicine and surgery*, 14(12). 946-951.

Piermattei, D. L., Flo, G. L., DeCamp, CE. (2006). The shoulder joint. In: W.O. Brinker, D. L. Piermattei, G. L. Flo (Eds.), *Handbook of small animal orthopedics and fracture repair*. 4th ed. (pp 262-296). St. Louis: Saunders Elsevier.

Schulz, K. S. (2013). Diseases of joints. Scapular luxation. In: T. W. Fossum (Ed.), *Small animal surgery* 4th ed, (pp. 1246). St Louis: Elsevier.

Scott, H., Mv Laughlin, R. (2006) *Feline Orthopedics* (pp. 111). Boca Raton: Taylor and Francis Group.

Voss, K., Langley-Hobbs, S. J., Montavon, P. M. (2009). Scapula. In: P. M. Montavon, K. Voss, S. Langley Hobbs (Ed.), *Feline orthopaedic surgery and musculoskeletal disease*. (pp. 329–336). Philadelphia: Saunders Elsevier.

CLINICAL AND THERAPEUTICAL APPROACH TO PROTEIN-LOSING NEPHROPATHY IN DOGS - A REVIEW

Roxana-Mariana IGNĂTESCU (ȚÎMPĂU), Ana-Maria GOANȚĂ,
Ana-Maria BĂDULESCU, Daniela BRĂSLAȘU, Lucian IONIȚĂ

University of Agronomic Sciences and Veterinary Medicine of Bucharest,
59 Marasti Blvd, District 1, Bucharest, Romania

Corresponding author email: roxana_mariana_12@yahoo.ro

Abstract

Protein-losing nephropathy (PLN) is a general term used to describe a list of glomerular disorders characterized by protein loss. Most common breeds affected are: Soft Coated Wheaten Terrier (adult age), Bernese Mountain Dog, Chinese Shar-pei, Labrador and Golden Retrievers. The main expression of PLN is proteinuria, which represents the presence of any excessive amount of proteins in the urine. PLNs include glomerulonephritis (GN), glomerulopathy, and amyloidosis, but only histological examination can differentiate these conditions. PLN may arise idiopathically and often co-exists with hypertension, hypoalbuminemia, moderate anemia, hypercholesterolemia, thromboembolism, edema or effusions and progressive renal disease. Diagnosis of PLN involves documenting significant proteinuria. Urine analysis should be performed as a complementary test in each routine investigation and elevated urine protein-creatinine ratio might confirm the renal origin of the proteinuria. The main therapeutic objective is the reduction of proteinuria. Resolution of PLN is possible if the underlying condition can be treated, but this is oftentimes difficult.

Key words: protein losing nephropathy; proteinuria; glomerulonephritis; amyloidosis.

INTRODUCTION

Protein Losing Nephropathy (PLN) is an inherited disease that affects Soft-Coated Wheaten Terriers, Bernese Mountain Dogs, Chinese Shar-pei, Labrador and Golden Retrievers and results in essential proteins being lost through the kidney.

The disease can be mild and stable for years however, it may lead to severe complications such as chronic kidney disease (CKD). Progression of the symptoms is variable and often influenced by environmental factors.

The clinical signs of PLN vary depending on the degree of proteinuria and presence and stage of CKD. In some asymptomatic animals, proteinuria is detected incidentally. Anorexia, weight loss, vomiting, and polyuria/polydipsia are common in advanced disease.

Clinical signs may also reflect complications from hypertension (retinal hemorrhage), hypercoagulability (pulmonary thromboembolism) or hypoalbuminemia which may lead to ascites and pleural effusion (Grant D. C. et al., 2001; Littman M.P., 2011; Cook A.K. et al., 1996).

MATERIALS AND METHODS

We used comprehensive and current databases to review the literature describing PLN in canine veterinary medicine using the following key-words: protein losing nephropathy, proteinuria, glomerulonephritis, amyloidosis.

We selected those articles which discuss the most important theories and supporting evidence on the pathogenesis of PLN followed by an overview of the clinical features and therapeutic management of this condition in dogs. The purpose of this article is to discuss the general management of dogs with PLN according to its etiology because any change or recovery would depend on the underlying cause of the proteinuria. Proteinuria as main expression of PLN is mentioned in the sources consulted and the challenge is to differentiate renal proteinuria from pre-renal and post-renal causes using appropriate diagnostic tools.

RESULTS AND DISCUSSIONS

Since 1997, The Soft Coated Wheaten Terriers Open Registry (SCWTOR) listed 722 dogs

documented with PLN. The real etiology was not clear enough, but it is believed that this disease is inherited.

The mode of inheritance appears complex and some affected dogs demonstrate an autosomal recessive mode of inheritance, while only some mixed breed dogs with one affected Soft Coated Wheaten Terrier parent are affected, thus suggesting a dominant mode of inheritance. The highest chances of being affected is 95%, and belongs to dogs homozygous for the mutation.

Approximately 10 to 15% of Soft Coated Wheaten Terriers are affected by the disease. PLN was also described in Bernese Mountain Dogs, Labrador Retrievers and Golden Retrievers, but the causative mutation was different. It is observed that females are more at risk than males (Littman M.P. et al., 2013; 2015).

PLN commonly results from two primary diseases: glomerulonephritis and amyloidosis. While amyloidosis is generally considered a genetic disease with certain breed predispositions, glomerulonephritis can be caused by a number of underlying diseases.

These diseases can be primarily associated with kidney injury or systemic injury (such as neoplasia, infections, immune-mediated conditions) (Cook A.K. et al., 1996).

Familial glomerulopathy is an inherited condition with abnormal glomerular collagen deposition leading to proteinuria and progressive renal disease.

In amyloidosis, abnormal amyloid protein is deposited in the glomerulus.

Proteinuria with renal amyloidosis can be massive and may lead to the development of nephrotic syndrome (Rivas, Al., 1993; Wehner, A., 2008).

The nephrotic syndrome also occurs as a result of glomerular disease and is characterised by proteinuria, hypoalbuminaemia, hyperlipidaemia and edema (Carter, 1994).

Although considered to be pathognomonic for glomerular disease, nephrotic syndrome was present in only 15% of dogs with glomerulonephritis, most commonly in dogs with heavy proteinuria (Center, S.A. et al., 1987).

PLN Pathogenesis

PLN is a broad term that describes diseases of the glomerulus that cause protein loss into the urine. Proteinuria results when the normal renal handling of protein malfunctions or is overwhelmed. Normally the small amount of protein that is present in the filtrate is passed through the glomerular capillary wall and reabsorbed by the proximal tubule. The anatomical barrier that is the glomerular capillary wall serves as the primary mechanism by which proteinuria is prevented. Thus, changes in glomerular permeability result in significant protein loss in urine (Rennke H.G., et al., 1975; Haraldsson B. et al., 2004; Tryggvason K. et al., 2006).

The glomerulus is a complex structure that functions as a filter to form an ultrafiltrate of plasma.

This filtration system, made up by the fenestrated endothelium, glomerular basement membrane and visceral epithelial cells (podocytes) is freely permeable to water and small dissolved solutes, but retains cells and most macromolecules, such as proteins.

The podocyte is the most differentiated cell in the glomerulus and essential to the filtration unit (Tobilli et al, 2012).

Despite this complex filtration system, the glomerulus normally leaks albumin. Rapid endocytosis and hydrolysis of these proteins by proximal tubular cells occurs.

Filtered albumin and other proteins are resorbed and ultimately released in the blood as amino acids. A normal animal should excrete virtually no protein in the urine, but certainly an amount that is below the limit of detection of routine urine protein assays (Maack, 2011). In certain clinically healthy dogs, a fraction of albumin is not resorbed and may be detected in low concentrations in the urine (Stockham and Scott, 2008).

Persistent and increased protein levels in the urine are abnormal.

Renal loss of plasma proteins can determine hypoalbuminemia and alter mineral and electrolyte metabolism, coagulation, cellular immunity, hormonal status, and may determine hyperlipidemia (Littman M.P., 2011; Bernard D.B., 1988, Harley L., 2012).

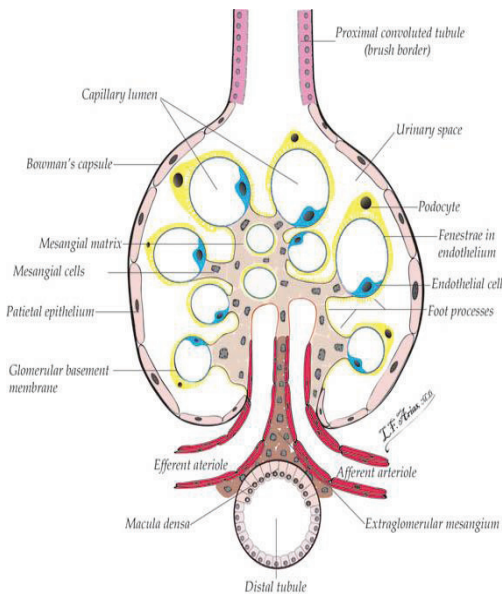


Figure 1. Schematic representation of a normal glomerulus (www.kidneypathology.com)

The origin of proteinuria

Proteinuria may be caused by physiologic conditions such as strenuous exercise, fever, seizures, stress, decreased physical activity and by pathologic causes: urinary or nonurinary disorders. Transient damage to the glomerulus from fever or heatstroke may cause transient proteinuria. Some authors consider that exercise does not appear to cause proteinuria in dogs as it does in people. The interval to determine whether there is persistent proteinuria is not firmly established, but reevaluation a month later is reasonable (Grauer G. F., 2009)

Nonurinary: the production of low-molecular-weight proteinuria (dysproteinemias) or genital tract inflammation. Cystocentesis (contraindicated in pyometra) is indicated in order to reduce potential sample contamination. According to Marynissen S. J (2016), free catch urine provides a good alternative to cystocentesis for UPC in dogs.

Urinary: renal or nonrenal origin. Nonrenal proteinuria is often associated with lower urinary tract inflammation, hemorrhage. Renal proteinuria is caused by increased glomerular filtration of plasma proteins associated with intraglomerular hypertension, structural abnormalities of the glomerular capillary wall, the presence of immune complexes or vascular

inflammation of the glomerular capillaries, decreased resorption of filtered plasma proteins due to tubulointerstitial disease, inflammatory or infiltrative disorders of the kidney (neoplasia, pyelonephritis, leptospirosis). Pathologic proteinuria is a persistent finding in glomerular damage, whereas functional proteinuria is generally transient. Inflammation and neoplasia of the lower urinary tract can induce significant proteinuria, and urinary protein should always be evaluated in light of the urinary sediment and bacteriological examination and the clinical signs present. Non-glomerular renal diseases, such as pyelonephritis, severe chronic kidney disease or acute tubular necrosis may also cause proteinuria. Excessive protein delivery to the kidney ("pre-glomerular proteinuria") may lead to proteinuria, in conditions such as hemoglobinuria or multiple myeloma (Vaden S. L., 2005; Grauer G. F., 2009)

Clinicopathological evidence of PLN in dogs

PLN causes no clinical signs in the initial stages and is simply a laboratory diagnosis, but familial glomerulopathies should be taken into account. PLN's first laboratory sign, persistent proteinuria, may be occult initially, but eventually discovered along with hypoalbuminemia, hypercholesterolemia, and possibly azotemia, hyperphosphatemia, anemia, and/or isosthenuria, when dogs present with clinical signs due to progressive renal injury (decreased appetite, weight loss, dehydration, lethargy, vomiting, polyuria/polydipsia) or perhaps earlier with dramatic signs due to hypertension (such as blindness due to retinal detachment or hemorrhage), thromboembolic events, or nephrotic syndrome with cavity effusions or edema of the extremities (Goldstein. R. E. et al., 2013; Jacob F. et al., 2005; Littman M. P. et al., 2015). Most forms of proteinuric renal disease, however, are glomerular diseases and may coexist with azotemia. Thus an animal does not have to have elevated blood urea nitrogen or creatinine to demonstrate renal damage (Harley L. et al., 2012)

Diagnosis of PLN in dogs - methods to assess proteinuria

As the measurement and sampling procedures for proteinuria have not been standardized, it is

of clinical importance to take into account the different types of urinary proteins, albumins, laboratory techniques, and urine sampling methods in order to have the best approach for an individual patient (Tobilli J. E. et al, 2012). There are four tests to measure protein on a routine urinalysis: colorimetric reagent strip, sulfosalicylic acid precipitation test (SSA), microalbuminuria test and urinary protein-creatinine ratio (UPC) (Goanta A. M. et al., 2018).

The colorimetric reagent strip (dipstick) method is the the most common method that provides a semi-quantitative measurement of protein, which is a good screening test, but has many false positive results (Zatelli A., 2010; Nabity M. B., 2011). Even if in recent years the colorimetric reagent method has improved significantly, any positive dipstick result should be confirmed with sulfosalicylic acid testing, which is a highly specific test (Grauer G. F., 2009).

Sulfosalicylic acid precipitation test was used for confirmation of protein detected on urinalysis due to high specificity. However, the very low sensitivity (prone to false negatives) makes SSA unsuitable for use as a screening test for proteinuria. As mentioned above, because of recent improvements in the colorimetric reagent method, SSA is no longer routinely performed at most veterinary diagnostic laboratories (Vaden, S. L., 2016).

The microalbuminuria test is a very sensitive test for determining if albumin is present in the urine (1-30 mg/dl), a level that would not be detected by standard testing such as the urine dipstick or SSA test (Vaden, S. L., 2016). The microalbuminuria test is prone to false positives, and determining the clinical significance of a positive result requires follow-up testing with a urine protein:creatinine ratio (Whittemore J. C., 2006). Microalbuminuria is an important risk factor for cardiovascular disease in people and therefore is routinely measured in many patient groups. However, it does not appear to be a similar risk factor in dogs (Maniaki E., 2018).

Urine protein: creatinine ratio (UP/C) has become the gold standard test for proteinuria and should be run on any patient testing trace or greater on a urine dipstick or positive on SSA. The urine protein to creatinine ratio, performed on a single random urine sample, has a close correlation to the 24-hour urine protein quantification (Harley L. et al., 2012). In healthy dogs, the UPC is less than 0.5. Values over 1 are considered abnormal. Values between 0.5 and 1 are questionable, and should be monitored for persistence or worsening. A consensus statement recommends monitoring, investigating, or intervention depending on the level of proteinuria and the presence or absence of azotemia. In nonazotemic dogs a UPC>0.5 prompts monitoring, a UPC>1 prompts investigation, and a UPC>2 prompts intervention. In azotemic dogs, intervention is recommended at a UPC>0.5 (Monroe W.E. et al., 1989; Lees G. et al., 2005).

An urine protein: creatinine ratio >2 suggests a glomerular origin. If the sediment examination eliminates inflammatory urinary tract disease and hemorrhage as the source of proteinuria, then the degree of increase may help distinguish tubular proteinuria (typical ratio value of 0.5–2), glomerulonephritis (typical ratio value of 0.5–15), and glomerular amyloidosis (typical ratio value of 0.5–40). However, substantial overlap exists in these ranges, and a variety of glomerulopathies such as focal segmental glomerulosclerosis in dogs have yet to be well characterized. Further, the ratio tends to be low in the initial stages of a glomerulopathy, increases in severity as the disease progresses, and then decreases terminally in late stage of kidney disease, but the degree of proteinuria does not always correlate with the severity of the histopathological lesions (Jacob F. et al., 2005; Nabity M. B. et al., 2007; 2011)

According to the 2017 International Renal Interest Society (IRIS) staging guidelines for chronic kidney disease (CKD), stage 1 CKD includes persistent proteinuria of renal origin; therefore, dogs with PLN should be assessed for CKD. In cases with moderate to severe renal injury, this likely still holds true (IRIS Staging of CKD, modified 2017).

Renal biopsy is required when mildly increased UPC cannot differentiate glomerular from tubular damage. Renal biopsy is considered the gold standard for determining the type of renal damage, but it is an invasive procedure and is not feasible in every case because of financial constraints or animal health. Therefore, less invasive, inexpensive, sensitive and specific methods to evaluate the presence, character, and severity of kidney damage in dogs are needed (Salama A. D., 2011).

The World Small Animal Veterinary Association – Renal Standardization Study Group (WSAVA - RSSG) demonstrated that canine renal biopsies could be evaluated with LM (Light Microscopy), IF (Immunofluorescence) and TEM (Transmission Electron Microscopy) in a reasonable diagnostic workflow to provide timely and useful information to clinicians. In this purpose, two veterinary diagnostic renal pathology centers (in United States and Europe) were established to perform the evaluations and facilitate the collection of cases for prospective studies (Cianciolo R. E., 2013). According to Ciancolo R.E. et al. (2013), several potentially useful correlations between the magnitude of proteinuria (UPC value), degree of hypertension and histopathological findings were observed. The first is that dogs with the MPGN (membranoproliferative glomerulonephritis) pattern of injury had the most severe constellation of associated clinical abnormalities: their median UPC values were as high or higher and their median albumine values, as low or lower, than those of dogs in other clusters. Also, dogs with MPGN had higher median creatinine values and hypertension more often than dogs in any other clusters. Ciancolo states that dogs with glomerulosclerosis generally had the least severe constellation of clinical abnormalities: lower median UPC and creatinine values and higher median albumin values than those of dogs in other clusters, with hypertension only moderately often. Finally, dogs with amyloidosis were hypertensive less often than dogs in any other cluster, but they were otherwise comparable to dogs with membranous glomerulonephritis (Ciancolo R.E. et al., 2016).

Therapeutical approach

Clinicopathological manifestations of PLN as a glomerular disease marker in dogs varies in severity, therefore the therapeutic approach to glomerular disease in an otherwise healthy animal with proteinuria alone should be different from one with proteinuria and azotemia, hypoalbuminemia, hypertension and edematous extremities (Littman M. P. et al., 2013).

The therapeutical objectives in PLN should include serial measurements, identification and treatment of the underlying condition (if possible), reduction of proteinuria, management of hypertension, reduction of inflammatory mediators and thromboembolic tendency, and, if diagnosed, management of amyloidosis. There is no effective treatment for established amyloidosis. Colchicine (0.01-0.03 mg/kg PO q 24 hours) given during febrile episodes in Shar Peis may decrease amyloid deposition. There is no evidence of effectiveness once renal failure has occurred.

In order to reduce proteinuria, therapy typically involves a combination of drugs that inhibit angiotensin converting enzyme (ACE) and dietary changes (Bakris G. L., 2008).

A renal diet, containing a restricted quantity of high quality protein should be prescribed. Protein restriction decreases the amount of proteinuria and the protein trafficking in the renal tubules (Burkholder W. J. et al., 2000; Parker V. J. et al., 2012). The enhanced omega-3 to omega-6 polyunsaturated fatty acid ratio and restriction in salt and phosphorus found in canine renal diets can also be of benefit to dogs with glomerulopathies. Omega-3 fatty acid supplementation has been shown to be renoprotective in dogs with renal disease because it reduces the magnitude of proteinuria, mitigates hypertension and was shown to control serum triglyceride and cholesterol concentrations in humans with nephrotic syndrome (Brown S.A. et al., 1998; 2000). These positive effects are in part mediated through generation of prostaglandins. Sodium restriction is beneficial in the control of hypertension and fluid retention. Provision of adequate exercise may help reduce the formation of edema or ascites (Vaden S. L. et al., 2011).

With the advent of ACE inhibitors, survival in dogs with PLN without renal injury has been extended. ACE inhibitors have been proven to decrease proteinuria and delay onset of renal disease in dogs. Enalapril (0.25-0.5 mg/kg PO q 12-24 h) is a commonly used drug (Grauer G.F. et al, 2000). Benazepril also has been shown effective to reduce proteinuria in cats with CKD (King, J. N. et al., 2006; Tenhundfeld, J. et al., 2009). Because ACE inhibitors can decrease renal blood flow, reevaluation for azotemia one week after starting therapy or dose adjustment is advised (Ryan M.J. et al., 2008). These drugs can be used in normotensive patients as well as in hypertensive patients, although blood pressure should be monitored.

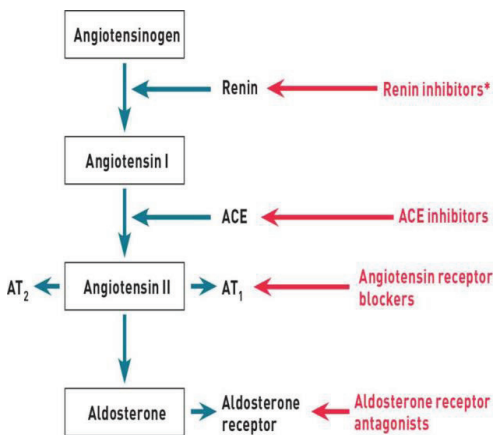


Figure 2. The renin-angiotensin-aldosterone system (RAAS) and its inhibitors. ACE inhibitors, angiotensin receptor blockers (ARB), and aldosterone receptor antagonists (ARA) have been used in the management of proteinuria in dogs. ACE, Angiotensin-converting enzyme; AT1, angiotensin II type 1 receptor; AT2, angiotensin II type 2 receptor (Vaden S., 2011)

Hypertension can lead to target-organ damage in the eyes, brain, cardiovascular system and kidneys. Untreated hypertension may cause worsening proteinuria and progressive renal injury. Many drugs are available to help control hypertension. In the setting of PLN, ACE inhibitors are the first choice, because of their combined antihypertensive and antiproteinuric effects. Inhibitors of RAAS are generally only weak antihypertensive agents, leading to a reduction in blood pressure by only about 10-15%. Ideally, systolic blood pressure should be

maintained at around 160 mm Hg while under RAAS inhibitor therapy; some animals may need additional antihypertensive therapy (Linas S. L., 2008). The first step is to increase the dose of the RAAS inhibitor. If this is ineffective when the upper end of the dosage range is being administered, the next step is to add a calcium channel blocker, typically amlodipine (0.25-0.5 mg/kg q 24 h). Systolic blood pressure should be maintained >120 mmHg in treated dogs (Atkins C. E. et al., 2007). If blood pressure is not adequately controlled by ACE inhibitors or calcium channel blockers and dose escalation is contraindicated, other agents can be added. Angiotensin receptor blockers (losartan, candesartan) are commonly used in conjunction with ACE inhibitors in people, but experience in veterinary medicine is limited. Because diuretics commonly cause volume depletion and hypokalemia, they are not routinely used, although spironolactone, an aldosterone antagonist diuretic, is used by some clinicians. Short term use until peripheral edema is controlled can be considered (Christ D. D. et al., 1994; Ovaert P. et al., 2010)

In order to prevent thromboembolism, which is recognized as complication of glomerular proteinuria, antithrombotic agents (aspirin or clopidogrel) are often indicated in dogs that have UPC>3. Aspirin at a dose of 0.5 mg/kg q 12-24 hours will inhibit platelet aggregation while decreasing the risk of side effects seen at standard doses. It has a wider safety margin than anticoagulants such as coumadin, which require meticulous monitoring to avoid serious hemorrhagic events. It is used to decrease the risk of thromboembolic complications, both systemically and locally, as platelet aggregation and fibrin deposition in the glomerulus may contribute to the pathogenesis of PLN (Littman M.P., 2011; Smith S.A., 2012).

In several studies, the increase in urinary protein excretion is correlated with the tendency of the renal disease to progress more than with the underlying renal disease itself. Whenever urinary protein excretion is reduced, the decline in the glomerular filtration rate slows or stops. Interstitial inflammation and progression of disease can be effectively limited by drugs that, by ameliorating the

glomerular permselective barrier to proteins, limit both proteinuria and filtered protein-dependent signaling for mononuclear cell infiltration and extracellular matrix deposition (Perico N. et al., 2005).

Immunosuppressive drugs may be used if immune-mediated processes are suspected. There are various protocols for various conditions, a topic too large to comprehensively cover here. In addition to corticosteroids, other drugs to be considered include: cyclosporine, azathioprine, mycophenolate, cyclophosphamide, and chlorambucil, among others. The IRIS Study Group recommends empirical application of immunosuppressive therapy for dogs with severe, persistent, or progressive glomerular disease in which there is evidence of an active immune-mediated pathogenesis on kidney biopsy and no identified contraindication to immunosuppressive therapy. For diseases associated with profound proteinuria, hypoalbuminemia, nephrotic syndrome, or rapidly progressive azotemia, single drug or combination therapy consisting of rapidly acting immunosuppressive drugs is recommended (Segev G. et al., 2013). There is no evidence of efficacy for immunosuppressive in dogs, and these drugs should be used with caution. Corticosteroids are associated with proteinuria and are not recommended in dogs unless underlying disease is steroid-responsive (systemic lupus erythematosus). Cyclosporine was not beneficial in controlled study of dogs with GN. Other immunosuppressive drugs, such as azathioprine (2 mg/kg PO q 24-48 hours in dogs only) or cyclophosphamide (50 mg/m² PO q 24 hours for 3 to 4 days, then off for 3 to 4 days) may be used but their benefit has not been proven. Mycophenolate mofetil (CellCept), a relatively new immunosuppressive agent used for human transplant recipients, is showing some promise in treating certain types of GN in people, most notably, lupus nephritis. No data is available for dogs with GN (Brown S.A. et al., 2013; Vaden S.L. et al., 2016).

CONCLUSIONS

In summary, many canine breeds have inherited glomerulopathies which are models for human disease, including glomerular basal membrane

defects analogous to Alport syndrome, focal segmental glomerulosclerosis and abnormal glomerular depositions of collagen III, amyloid, or immune complexes, as well as the nephrotic syndrome. Other underlying conditions such as glomerulonephritis and amyloidosis are associated with PLN in dogs.

Urinalysis for screening and monitoring proteinuria should be routine investigations in animals and a minimal urinalysis (dipstick and sediment) should be included in all examinations. Prompt intervention for diagnosis and treatment of proteinuria is recommended. Susceptible breeds should be biannually monitored for development of proteinuria and owners should be informed of the possible occurrence of kidney disease.

A thorough diagnostic work-up is needed to identify subsets of glomerular disease and their response to specific treatment protocols. After establishing a suspicion of PLN, standard tests to uncover potentially treatable causes should include a complete blood count, serum chemistry panel, urinalysis, urine culture, titers for common tick borne diseases (*Borrelia*, *Ehrlichia*, *Rickettsia*) and heartworm testing in dogs, thoracic radiographs to screen for neoplasia, and abdominal imaging (radiography or ultrasonography). Other tests would be dependent on individual case characteristics. If the disease suspected is of renal origin and the animal's condition permits it, biopsy is indicated for the definitive diagnosis and prognosis.

ABBREVIATIONS

CKD - Chronic Kidney Disease
IRIS - International Renal Interest Society
SSA - Sulfosalicylic Acid
UPC - Urinary Protein: Creatinine Ratio
USG - Urine Specific Gravity
PLN - Protein Losing Nephropathy
LM - Light Microscopy
TEM - Transmission Electron Microscopy
IF - Immunofluorescence
GN - Glomerulonephritis
MPGN - Membranoproliferative glomerulonephritis
MGN - Membranous glomerulonephritis
RAAS - The renin-angiotensin-aldosterone system

ACE - Angiotensin Converting Enzyme
ARB - Angiotensin Receptor Blocker
ARA - Aldosterone Receptor Antagonists

REFERENCES

- Atkins, C. E., Rausch, W. P., Gardner, S. Y., et al. (2007). The effect of amlodipine and the combination of amlodipine and enalapril on the renin-angiotensin-aldosterone system in the dog. *Journal of Veterinary Pharmacology and Therapeutics*, 30, 394-400.
- Bakris, G. L. (2008). Slowing nephropathy progression: Focus on proteinuria reduction. *Clinical Journal of the American Society of Nephrology*, 3, 3-10.
- Bernard, D. B. (1988). Extrarenal complications of the nephrotic syndrome. *Kidney International*, 33, 1184-1202.
- Brown, S. A., Brown, C. A., Crowell, W. A., et al. (1998). Beneficial effects of chronic administration of dietary omega-3 polyunsaturated fatty acids in dogs with renal insufficiency. *Journal of Laboratory and Clinical Medicine*, 131, 447-455.
- Brown, S. A., Brown, C. A., Crowell, W. A., et al. (2000). Effects of dietary polyunsaturated fatty acid supplementation in early renal insufficiency in dogs. *Journal of Laboratory and Clinical Medicine*, 135, 275-286.
- Brown, S. A., Elliot J, Francey T., et al. (2013). Consensus Recommendations for Standard Therapy of Glomerular Disease in Dogs. *Journal of Veterinary Internal Medicine*, 27, 27-43.
- Burkholder, W. J., Lees, G. E., LeBlanc, A. K., et al. (2004). Diet modulates proteinuria in heterozygous female dogs with x-linked hereditary nephropathy. *Journal of Veterinary Internal Medicine*, 18, 165-175.
- Carter, A. J., Van Heerden, J. (1994). Aortic thrombosis in a dog with glomerulonephritis. *Journal of the South African Veterinary Association*, 65(4), 189-192
- Center, S. A., Smith, C. A., Wilkinson, E., et al. (1987). Clinicopathologic, renal immunofluorescent, and light microscopic features of GN in the dog: 41 cases (1975-1985). *Journal of the American Veterinary Medical Association*, 190, 81-90.
- Christ, D. D., Wong, P. C., Wong, Y. N., et al. (1994). The pharmacokinetics and pharmacodynamics of the angiotensin II receptor antagonist losartan potassium (DuP753/MK 954) in the dog. *Journal of Pharmacology and Experimental Therapeutics*, 268, 1199-1205.
- Cianciolo, R. E., Brown, C. A., Mohr, F. C., et al. (2013). Pathologic evaluation of canine renal biopsies: methods for identifying features that differentiate immune-mediated glomerulonephritides from other categories of glomerular diseases. *Journal of Veterinary Internal Medicine*, 27, S10-S18.
- Cook, A. K., Cowgill, L.D. (1996). Clinical and pathological features of protein-losing glomerular disease in the dog: a review of 137 cases (1985-1992). *Journal of the American Animal Hospital Association*, 32(4), 313-322.
- Goanta, A. M., Ignatescu, (Timpau) R., Stanescu, A. M. A., Simion, V. A., Ionita, L. (2018). Current Knowledge On Urine Electrophoresis In Clinical Medicine. *Scientific Works. Series C. Veterinary Medicine*, 14(1), 47-54.
- Goldstein. R. E., Brovida, C., et al. (IRIS Glomerular Disease Study Group). harle(2013). Consensus recommendations for treatment for dogs with serology positive glomerular disease. *Journal of Veterinary Internal Medicine*, 27(1), 60-66.
- Grant, D. C., Forrester, S. D. (2001). Glomerulonephritis in dogs and cats: glomerular function, pathophysiology, and clinical signs. *Compendium on Continuing Education for the Practising Veterinarian*, 23, 739-747.
- Grauer, G. F, Greco, D. S, Getzy, D. M, et al. (2000). Effects of enalapril vs placebo as a treatment for canine idiopathic glomerulonephritis. *J Vet Intern Med.*,14, 526-533.
- Grauer, G. F. (2009). Proteinuria: Implications for management. In: Bonagura JD, Twedt DC, editors. *Kirk's Current Veterinary Therapy*. 14th ed. St Louis, Missouri: Saunders (Elsevier), 860-863.
- Haraldsson, B., Sorensson, J. (2004). Why do we not all have proteinuria? An update of our current understanding of the glomerular barrier. *News in Physiological Sciences*, 9, 7-10.
- Harley, L., & Langston, C. (2012). Proteinuria in dogs and cats. *The Canadian Veterinary Journal = La revue veterinaire canadienne*, 53(6). 631-638.
- International Renal Interest Society. IRIS 2017 staging of CKD. http://www.iris-kidney.com/pdf/IRIS_2017_Staging_of_CKD_09May18.pdf.
- Jacob, F., Polson, D. J., Osborne, C. A., et al. (2005). Evaluation of the association between initial proteinuria and morbidity rate or death in dogs with naturally occurring chronic renal failure. *Journal of the American Veterinary Medical Association*, 226, 393-400.
- King, J. N., Gunn-Moore, D.A., Tasker, S. et al. (2006). Tolerability and efficacy of benazepril in cats with chronic kidney disease. *Journal of Veterinary Internal Medicine*, 20, 1054-1064.
- Lees, G. E., Brown, S. A., Elliott, J., et al. (2005). Assessment and management of proteinuria in dogs and cats: 2004 ACVIM Forum Consensus Statement (Small Animal). *J Vet Intern Med.*, 19, 377-385.
- Linaz, S. L. (2008). Are two better than one? Angiotensin-converting enzyme inhibitors plus angiotensin receptor blockers for reducing blood pressure and proteinuria in kidney disease. *Clinical Journal of the American Society of Nephrology*, 3, 17-23.
- Littman, M. P. (2011). Protein-losing nephropathy in small animals. *Veterinary Clinics of North America: Small Animal Practice*, 41, 31-62.
- Littman, M. P. (2015). Emerging perspectives on hereditary glomerulopathies in canines. *Advances in Genomics and Genetics*, 5, 179-188.
- Littman, M. P., et al (2013). Glomerulopathy and mutations in NPHS1 and KIRREL2 in Soft-Coated Wheaten Terrier dogs. *Mammalian Genome* 24(3-4), 119-126.

- Littman, M. P., Daminet, S., Grauer, G., Lees, G., and Dongen, A. (2013). Consensus Recommendations for the Diagnostic Investigation of Dogs with Suspected Glomerular Disease. *Journal of Veterinary Internal Medicine*, 27, 19-26.
- Maaack, T. (2011). Renal handling of proteins and polypeptides. *Comprehensive Physiology*, 2039–2082.
- Maniaki, E., Finch, N. (2018). Chronic kidney disease in cats and dogs: managing proteinuria. In *Practice: Companion Animals*, 40, 266-280.
- Marynissen, S. J., Willems, A. L., Paepe, D., Smets, P. M., Picavet, P., Duchateau, L., & Daminet, S. (2016). Proteinuria in Apparently Healthy Elderly Dogs: Persistency and Comparison Between Free Catch and Cystocentesis Urine. *Journal of Veterinary Internal Medicine*, 31(1), 93–101.
- Monroe, W. E., Davenport, D. J., Saunders, G. K. (1989). Twenty-four hour urinary protein loss in healthy cats and the urinary protein-creatinine ratio as an estimate. *American Journal of Veterinary Research*, 50, 1906–1909.
- Nabity, M. B., (2011). Re-evaluating urine dipstick protein in dogs: when should you be concerned? *Advances in Small Animal Medicine and Surgery*, 24(11), 1–3.
- Nabity, M. B., Boggess, M. M., Kashtan, C. E. and Lees, G. E. (2007). Day-to-Day Variation of the Urine Protein: Creatinine Ratio in Female Dogs with Stable Glomerular Proteinuria Caused by X-Linked Hereditary Nephropathy. *Journal of Veterinary Internal Medicine*, 21: 425-430.
- Ovaert, P., Elliott, J., Bernay, F., Guillot, E., Bardon, T. (2010). Aldosterone receptor antagonists--how cardiovascular actions may explain their beneficial effects in heart failure. *The Journal of Veterinary Pharmacology and Therapeutics*, 33(2), 109-117.
- Parker, V. J., Freeman, L. M. (2012). Focus on nutrition: Nutritional management of protein-losing nephropathy in dogs. *Compendium on Continuing Education for the Practising Veterinarian*, 34, 1-5.
- Perico, N., Codreanu, I., Schieppati, A., et al. (2005). Pathophysiology of disease progression in proteinuric nephropathies. *Kidney International*, 67, 579–582.
- Rennke, H. G., Cotran, R. S., Venkatachalam, M. A. (1975). Role of molecular charge in glomerular permeability: tracer studies with cationized ferritins. *The Journal of Cell Biology*, 67, 638-646.
- Rivas, A. L., Tintle, L., Meyers-Wallen, V., Scarlett J. M., van Tassel, C. P., Quimby, F. W. (1993). Inheritance of renal I amyloidosis in Chinese Shar-pei dogs. *Journal of Heredity*, 84, 438-442.
- Ryan, M. J., Tuttle, K. R. (2008). Elevations in serum creatinine with RAAS blockade: Why isn't it a sign of kidney injury? *Current Opinion in Nephrology and Hypertension*, 17, 443–449.
- Salama, A. D., Cook, H. T. (2011) The renal biopsy In: Brenner and Rector's - The Kidney, 9th ed Philadelphia, PA: Elsevier Saunders, 1006–1015.
- Segev, G., Cowgill, L., Heiene, R., Labato, M. and Polzin, D. (2013). Consensus Recommendations for Immunosuppressive Treatment of Dogs with Glomerular Disease Based on Established Pathology. *Journal of Veterinary Internal Medicine*, 27, 44-54.
- Smith, S. A. (2012). Antithrombotic therapy. *Topics in Companion Animal Medicine*, 27(2), 88-94.
- Stockham, S. L., Scott, M. A. (ed.). (2008). *Veterinary Clinical Pathology Second Edition*. Blacwell Publishing USA, 416-423.
- Tenhundfeld, J., Wefstaedt, P., Nolte, J. A. (2009). A randomized controlled clinical trial of the use of benazepril and heparin for the treatment of chronic kidney disease in dogs. *Journal of the American Veterinary Medical Association*, 234, 1031-1037.
- Tobli, J. E., Bevione, P., DiGennaro, F., et al. (2012). Understanding the mechanisms of proteinuria: therapeutic implications. *International Journal of Nephrology*, 2012, 1–13.
- Tryggvason, K., Patrakka, J., Wartiovaara, J. (2006). Hereditary Proteinuria Syndromes and Mechanisms of Proteinuria. *The New England Journal of Medicine*, 354, 1387–1401.
- Vaden, S. L. (2005). Glomerular disease. In: Ettinger SJ, Feldman EC, editors. *Textbook of Veterinary Internal Medicine*. 6th ed. St Louis, Missouri: Saunders (Elsevier), 1786–1800.
- Vaden, S. L. (2011). Glomerular Disease. *Topics in Companion Animal Medicine*, Elsevier, 26(3), 128-134.
- Vaden, S. L., & Elliott, J. (2016). Management of Proteinuria in Dogs and Cats with Chronic Kidney Disease. *Veterinary Clinics of North America: Small Animal Practice*, 46(6), 1115–1130.
- Wehner, A., Hartmann K., Hirschberger, J. (2008). Associations between proteinuria, systemic hypertension and glomerular filtration rate in dogs with renal and non-renal diseases. *Veterinary Record.*, 162, 141-7.
- Whittemore, J. C., Gill, V. L., Jensen, W. A, et al. (2006). Evaluation of the association between microalbuminuria and the urine albumin-creatinine ratio and systemic disease in dogs. *Journal of the American Veterinary Medical Association*, 229, 958–963.
- Zatelli, A., Paltrinieri, S., et al. (2010). Evaluation of a urine dipstick test for confirmation or exclusion of proteinuria in dogs. *Journal of the American Veterinary Medical Association*, 71(2), 235-240.

RADIOGRAPHIC AND COMPUTED TOMOGRAPHY FINDINGS IN DOGS WITH FRAGMENTED MEDIAL CORONOID PROCESS

Andreea ISTRATE¹, Alexandra PETEOACA¹, Radu CONSTANTINESCU¹,
Giovanni ANGELI², Andrei TANASE¹

¹University of Agronomic Sciences and Veterinary Medicine of Bucharest, 59 Marasti Blvd,
District 1, Bucharest, Romania

²Università degli Studi di Perugia, Piazza Università 1, Perugia, Italy

Corresponding author email: andreeaistrate@gmail.com

Abstract:

Fragmented medial coronoid process is part of the triad of developmental lesions causing elbow dysplasia, amongst ununited anconeal process and osteochondrosis of the distomedial aspect of the humeral trochlea, being the most common clinical entity that generates elbow pain and osteoarthritis in dogs. In this study we compared computed tomography (CT) and radiological findings in 25 dogs presented with forelimb non-traumatic lameness, that were screened for elbow dysplasia and had a CT diagnosis of fragmented medial coronoid process. The radiographs were evaluated according to International Elbow Working Group guidelines and compared with CT images. A fragmented medial coronoid process was diagnosed in 6 dogs using radiographs and was visible in all dogs in the CT examinations. Because fragments are often poorly visualized on radiographic images, due to the fact that the medial coronoid process may remain cartilaginous, the fragment may not be completely detached or may superimpose on the radius, radiographic diagnosis is made mostly on secondary osteoarthritic changes. Thus, computed tomography examinations of the elbow joint have a much higher sensitivity in diagnosing this developmental lesion.

Key words: computed tomography; dog; elbow dysplasia; fragmented medial coronoid process; radiography.

INTRODUCTION

Elbow dysplasia is a developmental disorder, usually seen affecting young large breed dogs, with a complex genetic component involved, being a frequent cause of thoracic limb lameness (Hammond & McConnell, 2016).

Elbow dysplasia is a nonspecific term that encompasses a number of pathologic entities of the developing elbow, usually used for referring to a triad of developmental lesions that includes ununited anconeal process (UAP), fragmented medial coronoid process of the ulna (FMCP) and osteochondrosis or osteochondritis of the distomedial aspect of the humeral trochlea (OCD) (Pollard & Phillips, 2018).

Underlying causes for this disorder are not yet fully understood, but it is thought that genetics, nutrition, growth disturbances and trauma can all be part of the aetiologies of this condition (Wisner & Zwingenberger, 2015). One theory states that UAP, FMCP and OCD can be related to incongruity of the elbow joint (Wind, 1986).

Fragmentation of the medial coronoid process of the ulna is the most common disorder of the

elbow joint in growing dogs, being also the most common clinical lesion that generates elbow pain and osteoarthritis (Kirberger, 2016).

Fragmented medial coronoid process is a developmental disorder of the elbow joint, with clinical signs apparent as early as 4 to 6 months (La fond et al., 2002; Temwichitr et al., 2010).

In FMCP, some of the radiographic changes of the elbow joint can include flattening or rounding of the medial coronoid process, proliferation, distinct fragmentation or an ill defined margin in one or more projections (Hornof et al., 2000; Cook & Cook, 2009).

Due to the superimposition of the medial coronoid process on the radius, the fact that the fragment may still be cartilaginous, it may be fissured and not separated and there can be minimal or no fragment displacement the radiographic visualization of the fragmented medial coronoid process can be extremely difficult to detect (Pollard & Phillips, 2018).

Typically, a fragmented medial coronoid process is not seen as a separate fragment in radiographs. In fact, the absence of a normal appearing medial coronoid process on

mediolateral projections is a good indicator of affected MCP. In most instances actually, radiographic diagnosis of FMCP can be made indirectly, on the basis of secondary osteoarthritic changes, like sclerosis of the subchondral bone beneath the trochlear notch of the ulna and periarticular osteophyte formation of the distal humerus, proximal radius and proximal ulna (Berry, 1992; Hammond and McConnell, 2016).

The complexity of the elbow joint, the variation in radiographic appearance and the inability to directly assess articular pathology make radiography as a sole diagnostic modality incomplete, other modalities like computed tomography (CT), magnetic resonance (MRI), ultrasound and arthroscopy being necessary for a definitive diagnosis (Voorhout & Hazewinkel, 1987; Cook & Cook, 2009).

Studies regarding this condition that compare radiographic examinations with computed tomography show that CT has a sensitivity of 88.2%, compared with radiology, that has only one of 23.5% in identifying fragmented medial coronoid processes (Carpenter et al., 1993; Stickle & Hathcock, 1993; Braden et al., 1994; Reichle et al., 2000). There are multiple studies that state the value of CT for diagnostic imaging of the canine elbow (Reichle et al., 2000; De Rycke et al., 2002). This diagnostic imaging method allows for great delimitation and differentiation of the medial and lateral coronoid processes, the medial and lateral aspects of the humeral condyle and the radial incisure or head (Cook & Cook, 2009).

In CT, abnormalities of the medial coronoid process include abnormal shape, sclerosis, osteophytosis, fragments or fissures, hypo or hyperattenuation and associated radial irregularities or lucencies (Reichle & Snaps, 1999; Reichle et al., 2000).

MATERIALS AND METHODS

This study was made retrospectively, over the years 2015-2018. The medical records of twenty-five canine patients admitted to the Faculty of Veterinary Medicine in Perugia, Italy, diagnosed with fragmented medial coronoid process on CT examinations were reviewed. All dogs underwent, prior to the CT scan, clinical and radiological examinations.

On physical examination, lameness was detected in one or both elbow joints. In some dogs, clinical findings were supported by radiographic ones. Radiographic examination of both elbows was performed and neutral mediolateral, flexed mediolateral, craniocaudal and oblique craniolateral- 15° caudomedial views were obtained.

Afterwards, all dogs underwent general anesthesia and complete transverse CT examinations of both elbows. Patients were positioned in sternal recumbency, with the forelimbs parallel and pulled cranially. Acquisition of CT data was performed on a multislice helical CT scanner (SiemensTM), using a small field of view and a filter for bone and soft tissue reconstruction.

All examinations were reviewed by two different examiners and a consensus opinion was made. Normal elbow images in transverse and sagittal planes are shown in Figure 1A, B.

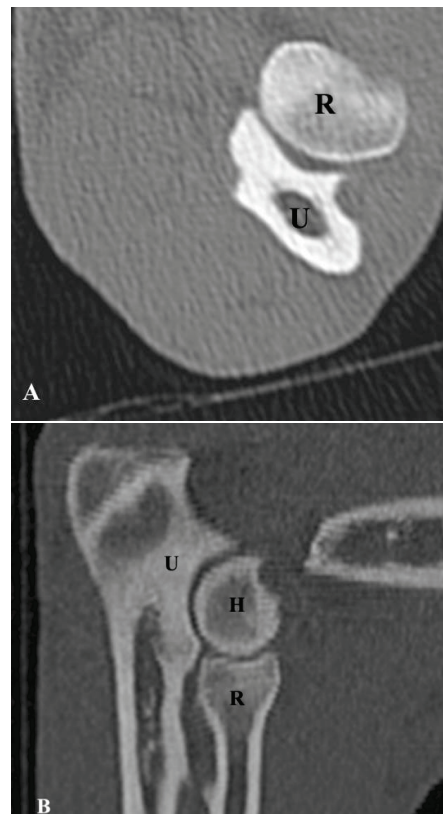


Figure 1. (A) Transverse CT image of a normal canine elbow at the level of the radius (R) and ulna (U). (B) Sagittal CT image of a normal canine elbow; R-radius, U-ulna, H-humerus.

RESULTS AND DISCUSSIONS

The breeds of the 25 dogs are represented in Table 1. Age at the time of the examination ranged between 6 months and 7 years, with a mean age of 2.24 years. There were examined 8 intact females, 5 neutered females, 10 intact males and 2 neutered males and a total of 50 elbows.

Table 1. Breed distribution and number of dogs that underwent radiologic and CT examinations due to lameness attributed to the elbow joint

Breed	Number
Labrador Retriever	6
German Shepherd	5
Golden Retriever	3
Bernese Mountain Dog	3
Border Collie	3
Irish Setter, Weimaraner, Bull Terrier, Dachshund, American Bulldog	1 each

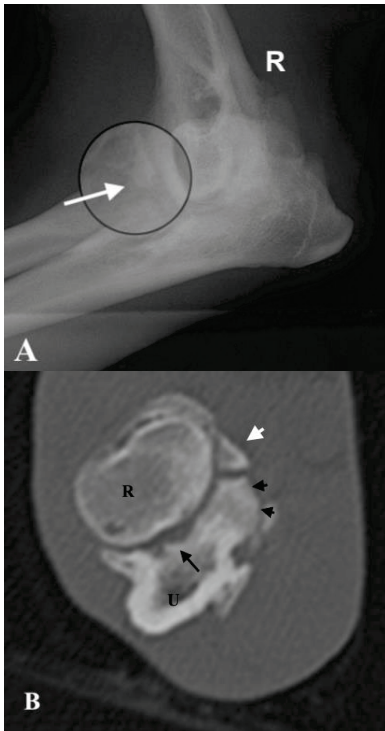


Figure 2. (A) Mediolateral right (R) elbow projection in which a fragment of the medial coronoid process can be seen (white arrow). (B) Transverse CT image of the same elbow through the radius (R) and the ulna (U); There is a distinctly separate fragmented MCP (arrowhead), abnormal shaped coronoid process (black arrowheads), sclerosis and radial incisure irregularity (black arrow)

Clinical orthopedic examination revealed lameness of one or both elbows for every dog. A number of 8 elbows (16%) presented slightly adducted and with a lateral rotation of the antebrachium. Twenty out of 50 elbows (40%) presented with pain on manipulation and palpation and in 9 elbows (18%) pain was elicited after maximal flexion of the elbow joint, combined with lateral rotation of the affected limb.

For all patients, the following changes were described as present or absent, in both CT and radiographic images: distinct fragment of medial coronoid process (Figure 2A and B), fissure or in situ fragmented MCP (Figure 3A, B and C), abnormally shaped MCP, sclerosis of the MCP and osteophyte of the MCP (Figure 4A and B). Radiographic fragments/fissures at the level of the MCP were identified only in 6 of the dogs examined (4 males and 2 females) (Figure 2A; Figure 3A).

For the remaining 19 dogs, the radiographic signs of fragmented or fissured MCP were not as visible and the diagnosis was suspicious considering observable secondary osteoarthritic changes, like sclerosis of the MCP or medial humeral condyle, presence of osteophytes at the site of the ulna, radius or humerus, irregularity or abnormal shape (blunting/flattening) of the MCP, making necessary the CT examination.

On the CT images, the MCP was considered affected if there were fragments, fissures or sclerosis present or if it had an abnormal shape. All dogs in this study had a diagnosis of fragmented or fissured medial coronoid process.

Fragments of the medial coronoid process have been divided in two groups (large fragments, > 5 mm and small fragments, < 5 mm) (Figure 5A, B, C, D). Fragments are observed at the top of the MCP, while fissures or in situ fragments are parallel to the radial incisure. Sclerosis of the MCP was observed in 27 (54%) of the 50 elbows examined, while osteophytes of the ulna were present only in 12 (24%) of them. Other abnormalities observable in CT examinations are represented in Table 2 (abnormalities of the MCP, of the radial incisure of the ulna, the medial aspect of the humeral condyle and osteophytes of the ulna, radius and humerus).

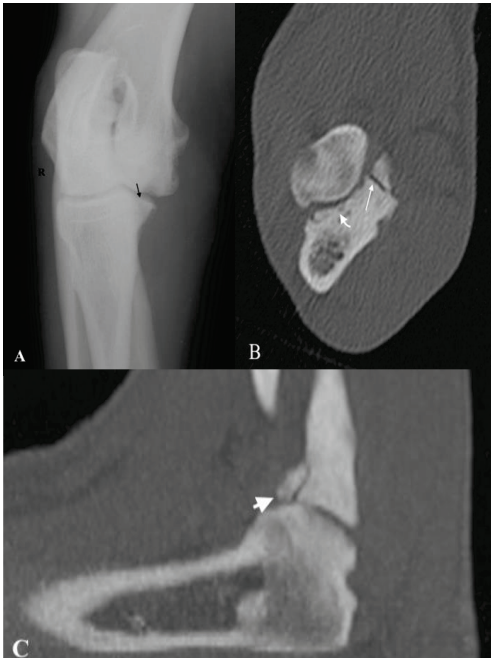


Figure 3. (A) Craniocaudal projection of the right elbow in a dog presenting with forelimb lameness; slightly visible MCP fissure line (black arrow). (B) Transverse CT image of the same elbow; visible fissure of the MCP (white arrow) and irregular radial incisure (curved arrow). (C) Sagittal CT image of the same elbow as in (A) and (B); visible fissure line of the MCP

Table 2. Abnormal CT findings and percentage of the affected limbs in 50 examined elbows of dogs with unilateral or bilateral forelimb lameness

Abnormal CT finding	Percentage of affected limbs (%)
MCP of the ulna	
Abnormal shape	77
Sclerosis	54
Osteophyte	24
Distinct fragment	75
Fissure/in situ fragment	25
Radial incisure of the ulna	
Irregularity	40
Medial aspect of the humeral condyle	
Sclerosis	55
Flattening	45
Osteophytes	
Ulna	24
Radius	22
Humerus	35

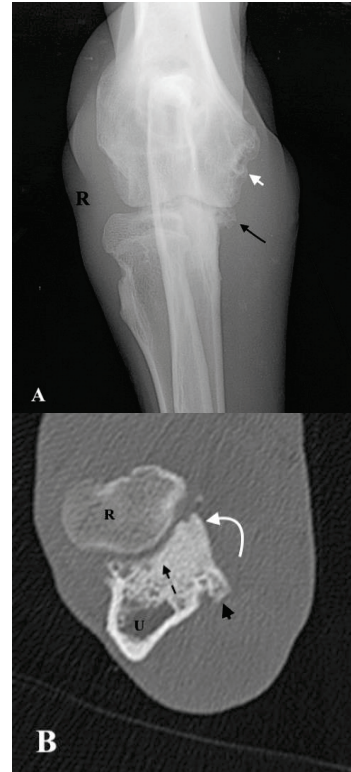


Figure 4. (A) Craniocaudal projection of the right elbow (R) in a dog presenting with mild forelimb lameness. Sclerosis and abnormal shape of the MCP (black arrow) and humeral condyle (white arrow) are present. (B) Transverse CT image at the level of the radius (R) and ulna (U) of the same elbow. Sclerosis (black arrowhead), abnormal shape (curved white arrow) of the MCP and irregular radial incisure (dotted black arrow) are present

In Table 3 are presented the main radiological changes associated with fragmented medial coronoid disease. Radiological diagnosis of the medial coronoid process is difficult, due to the fact that MCP can not be visualized without interference of bony structures (Cook & Cook, 2009). The presence of any of the signs from Table 3 is suggestive of elbow dysplasia, but identification of several changes increased the examiner's indirect diagnosis of FMCP. Sclerosis of the subchondral bone of the MCP, seen as an area of increased opacity at the trochlear notch, was the main sign of a possible fragmentation of the coronoid process, being present in 30 (60%) of the elbows examined (Figure 6A, B, C).

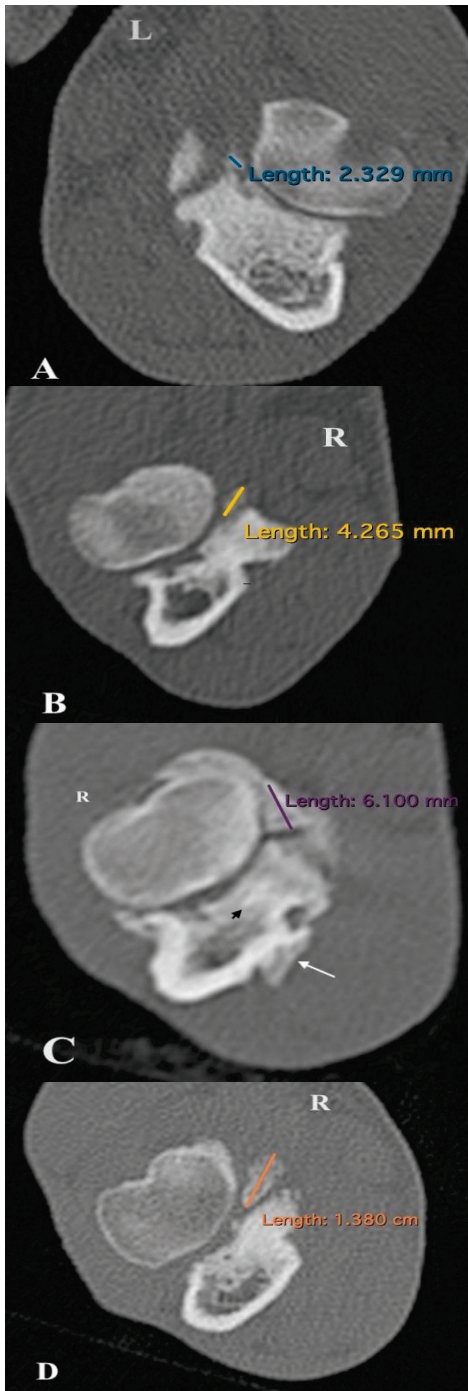


Figure 5. Transverse CT images of right (R) and left (L) elbows with different sizes of large and small fragments of medial coronoid processes. (A) Small FMCP fragment, of 0.23 cm; (B) Small FMCP fragment of 0.42 cm; (C) Large FMCP fragment of 0.61 cm; (D) Large FMCP fragment of 1.3 cm

Table 3. Abnormal radiological findings and percentage of the affected limbs in 50 examined elbows of dogs with unilateral or bilateral forelimb lameness

Main radiological sign	Percentage of affected limbs (%)
Sclerosis	60
Fragment of MCP	14
Articular incongruence	20
Blunted / convex shape of MCP	24
Periarticular osteophytes	30

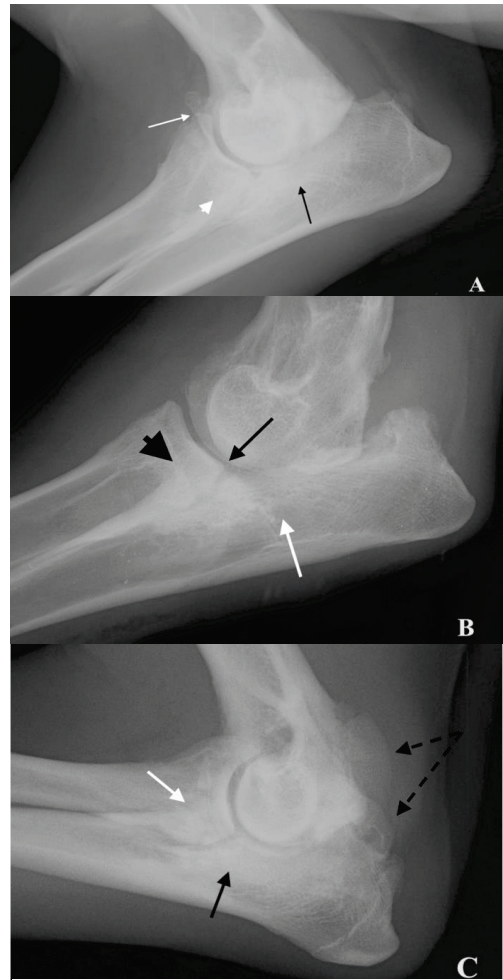


Figure 6. Changes associated with the medial coronoid process. (A) Subtrochlear sclerosis (black arrow), abnormally shaped MCP (white arrowhead) and periarticular osteophytes (white arrow); (B) Subtrochlear sclerosis (white arrow), abnormally shaped MCP (black arrowhead) and articular incongruence (black arrow); (C) Subtrochlear sclerosis (black arrow), abnormally shaped MCP (white arrow) and proliferation of the humeral condyle and anconeal process of the ulna (dotted black arrows)

CONCLUSIONS

The elbow joint is a complex articulation and diseases of the medial coronoid process of the ulna may be difficult to assess using only survey radiographs, until secondary changes are relatively marked.

A diagnosis of fragmented medial coronoid process was established after direct radiographic visualization of the fragment in 6 dogs and an equivalent of 14% of the elbows examined.

In fragmented medial coronoid disease, the most common radiographic sign of abnormality was sclerosis of the subchondral bone (in 60% of the examined elbows).

Computed tomography has the ability of evaluating the whole joint, highly differentiating and delimitating fragments or fissures of the medial coronoid process, making the establishing of a diagnosis possible before osteoarthritic changes become severe.

The most common CT findings in dogs with fragmented medial coronoid process were abnormal shape of the medial condyle, seen in 77% of the examined limbs and sclerosis of the subchondral bone, in 54% of them.

As a main conclusion, this retrospective paper shows confirms the fact that computed tomography offers visualization without superimposition, having a higher sensitivity for detecting fragmented medial coronoid process disease, compared with the radiological examination.

REFERENCES

Berry, C. R. (1992). Radiology Corner: Evaluation of the canine elbow for fragmented medial coronoid process. *Veterinary Radiology and Ultrasound*, 33: 273-276.

Braden, T., Stickle, R., Dejardin, L. (1994). The use of computed tomography in fragmented coronoid

disease: a case report, *Vet Comp Orthop Trauma* 7:40.

Carpenter, L. G., Schwarz, P. D., Lowry, J. E., Park, R. D., Steyn, P. S. (1993). Comparison of radiologic imaging techniques for diagnosis of fragmented medial coronoid process of the cubital joint in dogs. *J Amer Vet Med Assoc* 203:78-83.

Cook, C. R., Cook, J. L. (2009). Diagnostic imaging of the canine elbow dysplasia: a review. *Veterinary Surgery*, 38:144-153.

De Rycke, L. M., Gielen, IM, van Bree, H., Simoens, P. J. (2002). Computed tomography of the elbow joint in clinically normal dogs. *Am J Vet Res* 63:1400-1407.

Hammond, G., McConnell, F. (2018) - Radiology of the appendicular skeleton. In BSAVA (Ed), *Radiography and Radiology*, (pp. 276-279), Gloucester, UK.

Hornof, W. J., Wind, A. P., Wallack, S. T., Schultz, K. S. (2000). Canine elbow dysplasia. The early radiographic detection of fragmentation of the coronoid process, *Vet Clin North Am Small Anim Pract* 30(2):257-266.

LaFond, E., Beur, G. J., Austin, C. C. (2002). Breed susceptibility for developmental orthopedic disease in dogs. *Journal of the American Animal Hospital Association* 38, 467-477.

Pollard, R. E., Phillips, K. L. (2017) - Orthopedic diseases of young and growing dogs and cats. In Elsevier (Ed), *Textbook of Veterinary Diagnostic Radiology 7th edition* (pp. 348-350). St. Louis, Missouri.

Reichle, J. K., Park, R. D., Bahr, A. M. (2000). Computed tomographic findings of dogs with cubital joint lameness, *Vet Radiol Ultrasound* 41(2):125-130.

Reichle, J. K., Snaps, F. (1999). The elbow. *Clin Tech Small Anim Pract* 14:177-186.

Stickle, R. L., Hathcock, J. T. (1993). Interpretation of computed tomographic images. *Vet Clin of N Amer* 23:417-435.

Voorhout, G., Hazewinkel, H. A. W. (1987). Radiographic evaluation of the canine elbow with special reference to the medial humeral condyle and the medial coronoid process. *Veterinary Radiology*, 28: 158-165.

Temwichitr, J., Leegwater, P. A. J., Hazewinkel, H. A. W. (2010). Fragmented coronoid process in the dog: A heritable disease. *The Veterinary Journal*, 185: 123-139.

RADIOGRAPHIC RETROSPECTIVE STUDY OF THORACIC CAVITY ALTERATIONS IN DOGS AND CATS WITH RESPIRATORY DISEASES

**Alexandru Gabriel NEAGU¹, Mihai SĂVESCU¹, Giovanni ANGELI²,
Niculae TUDOR¹, Constantin VLĂGIOIU¹**

¹University of Agronomic Sciences and Veterinary Medicine of Bucharest,
59 Marasti Blvd, District 1, Bucharest, Romania

²University of Perugia, Faculty of Veterinary Medicine, Perugia, Italy

Corresponding author email: neagualex29@yahoo.ro

Abstract

The objective of this study was to identify disorders at the level of the thoracic wall as a determining factor in modified respiratory function in dogs and cats.

A number of 130 cases (79 dogs and 51 cats) with respiratory diseases and showed changes in the thoracic wall were examined. The cases were examined by clinical and paraclinical methods in the Faculty of Veterinary Medicine from Bucharest and Perugia clinics. At the thoracic wall bone tissue were recorded: 15 cases (13 dogs and 2 cats) with changes in the spine, 5 cases (3 dogs and 2 cats) with changes in the sternum and 12 cases (7 dogs and 5 cats) with changes at the ribs level. The soft tissues of the thoracic wall were affected by neoplastic processes in 26 cases (21 dogs and 5 cats) and post-traumatic injuries in 46 cases (24 dogs and 22 cats). Additionally, 26 cases (11 dogs and 15 cats) were identified with diaphragmatic disorders. The assessment found that post-traumatic injuries had the highest prevalence and the imaging examination allowed the localization of lesions.

Key words: *cat, dog, radiographic study, respiratory diseases, thorax.*

INTRODUCTION

Changes in respiratory function may result from disorders in the thoracic wall, which may be traumatic, neoplastic or congenital (Thrall, 2018). Thoracic changes include a wide variety of lesions, many of them being difficult to diagnose and manage. Car accidents, height falls, biting or shooting are the main causes of post-traumatic injury of the thoracic wall in dogs and cats. These lesions may be of interest in both thoracic soft tissues (skin, fat, muscles) and thoracic bone structures (ribs, sternum, spine) (Parry A. and Lamb C., 2010). Neoplastic processes of the thoracic wall can be found frequently in companion animals, raising great problems in diagnosis and treatment (Olsen et al., 2002).

In addition, congenital changes that may affect the spine, sternum and/or the ribs may be encountered at the thorax wall but not always accompanied by respiratory dysfunction, which causes these congenital abnormalities to be accidentally detected following the radiological examination. Sometimes severe sternum changes, such as those found in pectus

excavatum, can produce compressions on the internal organs inside the thorax, followed by changes in the respiratory function (Singh et al., 2013; Charlesworth Tim, 2017).

The purpose of this paper was to perform a retrospective imaging study on localized thoracic wall disorder in dogs and cats as a determining factor in modified respiratory function.

MATERIALS AND METHODS

The medical records of 130 cases presented in FMV Bucharest and FMV Perugia clinics, of which 79 dogs and 51 cats showing respiratory changes were examined by clinical and paraclinical methods.

For the collection of signs/symptoms, the general examination methods (inspection, palpation, percussion, listening of body noise and assessment of body temperatures) and complementary methods (radiography, CT scan, aspiration puncture and cytology) were used as previously described in the specialized works (Vlăgioiu C. and Tudor N., 2012).

The radiographic examination was performed from the latero-lateral, ventro/dorsal and dorso/ventral incidence with a Bucky Diagnost digital device from Philips and the images were taken with a 100 cm source-picture distance. The films were developed using a PCR ELEVA S apparatus. The CT scanner (Siemens Somatom Volume Zoom, with 4 slices) was performed only in cases where classical imaging methods did not have diagnostic value. The aspirational puncture was performed to detect the type of neoplastic process. The harvested sample was introduced into sterile containers and dispatched to the clinical laboratory. Microscope slides of harvested samples were made using the May-Grumwald-Giemsa (MGG) method, and subsequently examined under a microscope with objectives of different sizes.

RESULTS AND DISCUSSIONS

There were evaluated 79 dogs aged between 1 and 15 years, as well as 51 cats aged between 10 months and 13 years. Thoracic changes were represented by post-traumatic lesions, congenital anomalies and neoplastic processes, localized in the bone tissue (sternum and rib) and soft tissues (skin, fat, muscles, pleura and diaphragm). It should be noted that on the same animal it has been identified one or more lesion types.

At the bone tissue level were registered 15 cases (13 dogs and 2 cats) with changes in the spine (3 post-traumatic, 1 neoplastic process, 11 congenital anomalies), 5 cases (3 dogs and 2 cats) with changes in the sternum (1 post-traumatic and 4 abnormalities) and 12 cases (7 dogs and 5 cats) with changes in the ribs (2 post-traumatic, 3 neoplastic and 7 congenital abnormalities). Regarding the soft tissues of the thoracic wall, neoplastic processes were recorded in 26 cases (21 dogs and 5 cats) and post-traumatic injuries in 46 cases (24 dogs and 22 cats) represented by subcutaneous emphysema (17), hematomas (21) and contusions (23). In addition, in 26 cases (11 dogs and 15 cats) diaphragm changes were identified, representing congenital anomalies (2) and post-traumatic lesions (24).

Clinical and paraclinical assessments found that post-traumatic injuries had the highest

prevalence (76 cases), followed by neoplastic processes (30 cases) and congenital changes (24 cases).

Post-traumatic lesions recorded a wide range of changes, of which diaphragmatic rupture, contusions, haematomas of the soft tissue were predominant. In the study by Cabon et al. (2015) thoracic cavity disorders were represented by pulmonary contusions in 26 cases (23 dogs, 3 cats), followed by simple or multiple fractures at the rib level in 23 cases (21 dogs, 2 cats), pneumothorax in 17 cases (13 dogs, 4 cats) and liquid collections in 8 cases (7 dogs, 1 cat).

In the present study, post-traumatic injuries to the dog were caused by bite wounds (22 cases) or car accidents (17 cases), while in cats the most frequent cause was falling from height (37 cases). Thoracic wall injuries were represented by: haematomas, subcutaneous emphysema, rib fractures, to which were added gaseous pleural collections and pulmonary atelectasis (Figure 1). Our results were somewhat similar to those reported by Shaw et al. (2003), but found a more wider range of causes, identifying 36 cases (26 dogs and 10 cats) with trauma, of which 18 cases were produced by bite wounds, 13 cases following car accidents, 1 case by a trauma produced by hitting with the hoof by a horse and 4 cases with an unknown cause.

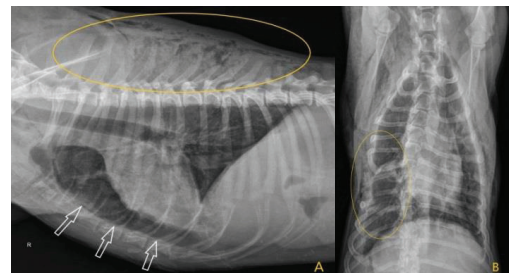


Figure 1 - Dog, 5 years, lateral incidence (A) and dorsoventral (B) - costal fractures, subcutaneous emphysema and pneumothorax following a car accident

Were recorded 4 cases (3 dogs and 1 cat) with neoplastic processes of the thoracic bone tissues, and 26 cases (21 dogs and 5 cats) were recorded at the level of thoracic soft tissues. Typically, on the radiographic image, were revealed outbreaks of lesions at the level of the bone structure in the thoracic wall, while in soft tissue were observed soft tissues densities with

variable dimensions (Figure 2). For accurate localization of thoracic skeletal masses, CT scan was performed in 4 cases. It allowed to determine the degree of involvement of both the bone tissue and the soft tissues in the disease lesions, revealing different degrees of bone lyses, as well as the involvement of adjacent soft tissues (Figure 3).

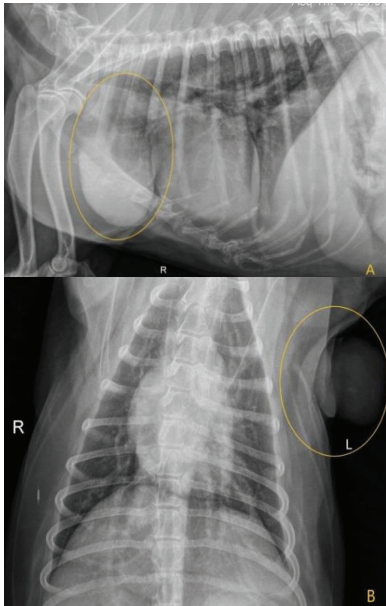


Figure 2 - Dog, 13 years old, right side view (A) and dorso-ventral view (B) – mass with soft tissue density localized at the thoracic soft tissue in the axillary area

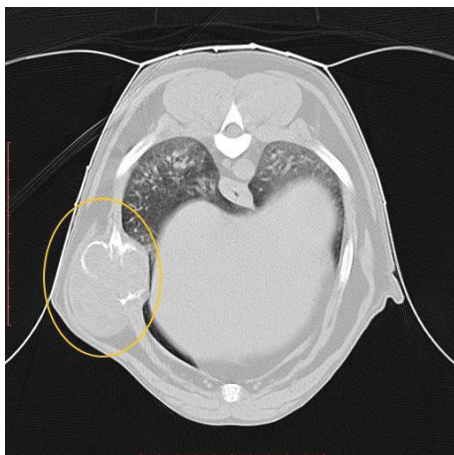


Figure 3 - Transversal, CT scan of a 10 years of dog at the level of 9 rib in a bone window. The lesion originates at the distal extremity of the ninth rib, observing bone lysis and a soft tissue mass associated with bone lysis

The cytological examination allowed the determination of the neoplastic type, revealing the presence of carcinomas and sarcomas (Figure 3) in 19 cases (located at thoracic mammary chains), lipoma in 5 cases, osteosarcoma in 4 cases (Figure 4), while 2 cases were metastases of primary neoplastic processes (soft tissues).

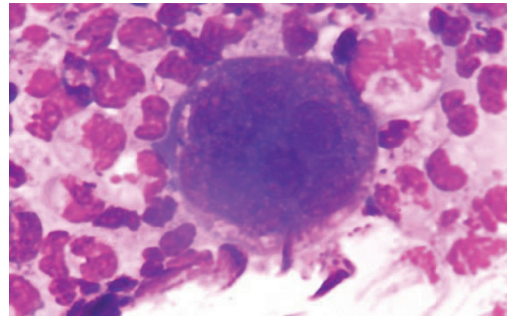


Figure 4 - Dog, 10 years, neoplastic cellularity (mammary histiocytic sarcoma), MGG staining, x1000

Previous studies indicate that subcutaneous lipomas are the most common neoplastic processes of thoracic soft tissue, may also be present fibrosarcomas, often localized in the interscapular area caused by vaccination (Thrall, 2018). In our study lipoma was identified in 5 of the evaluated cases, and most of the neoplastic processes (18 cases) were represented by mammary carcinomas. Sun and col. (2011) found that 41 evaluated females presented different morphological types of carcinoma in the thoracic wall, and Otoni et al. (2010) found that 13 cases were mammary carcinoma and 6 cases were mixt neoplastic processes.

Congenital abnormalities are encountered accidentally in dogs and cats, as a consequence of poor development of the ribs, sternum and/or spine. Most of the time these congenital anomalies do not affect respiratory function, but in individuals with severe changes in sternal conformation, respiratory dysfunctions have also been reported (Charlesworth Tim, 2017, Singh et al., 2013). In the present study, 4 cases of pectus excavatum (2 dogs and 2 cats) showed a moderate respiratory symptomatology (Figure 5). According to previous studies, if congenital anomalies do not put the animal's life at risk, surgical intervention is not necessary (Thrall, 2018).

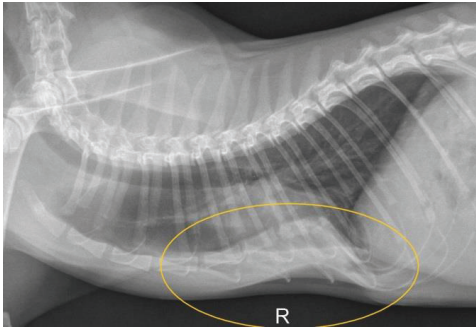


Figure 5 - Cat, 10 months, right lateral view - dorsal detachment of the sternum, masking the cardiac silhouette following the overlapping of the sternal structures and reduction of the size of the thoracic cavity

CONCLUSIONS

In conclusion, changes in the thoracic wall may be represented by a wide range of lesions, and the radiographic examination is an essential tool in the evaluation of patients who have had thoracic injuries or have developed neoplastic and congenital processes, and advanced imaging methods (such as CT scan) may allow a more detailed assessment of lesions that are radiographically identified.

REFERENCES

Cabon Q., Deroy C., Ferrand F.X., Pillard P., Cachon T., Faul D., Goy-Thollot I., Viguier E., Carozzo C. (2013). Thoracic bite trauma in dogs and cats: a

- retrospective study of 65 cases, *Vet. Comp. Orthop. Traumatol.* volume 28, 448–454.
- Charlesworth Tim (2017). Pectus excavatum: congenital thoracic deformity in cats. *In Practice*, volume 39, 73-78.
- Olsen D., Renberg W., Hauptman J. G., Waldron R., Monnet E. (2002). Clinical Management of Flail Chest in Dogs and Cats: A Retrospective Study of 24 Cases (1989-1999), *Journal of the American Animal Hospital Association*, volume 38, 315-320.
- Otoni Carolina., Rahal Sheila, Vulcano L., Ribeiro S. M., Hette K., Giordano Tatiana, Doiche Danuta, Amorim Renée (2010). Survey radiography and computerized tomography imaging of the thorax in female dogs with mammary tumors, *Acta Veterinaria Scandinavica*, volume 52, 20.
- Parry A., Lamb C. (2010). Radiology of thoracic trauma in the dog and cat. *In Practice*, volume 32, 238–246.
- Singh M., Parrah J., Moulvi B. A., Athar H., Kalim M. O., Dedmari F. H. (2013). A Review on Pectus Excavatum in Canines: A Congenital Anomaly, *Iranian Journal Of Veterinary Surgery*, volume 8(1), Serial No:18, 59-63.
- Shaw S. P., Rozanski Elizabeth A., Rush J. E. (2003). Traumatic Body Wall Herniation in 36 Dogs and Cats, *Journal of the American Animal Hospital Association*, volume 39, 35-46.
- Soare M., Dinescu Georgeta, Gubcea Elvira, Tudor N., Vlăgioiu C. (2011). Study concerning the prevalence of the pulmonary metastases and the clinical aspects in the bitches with mammary tumors. *Scientific Works C Series LVII (2)*, pp. 335-340.
- Thrall D. (2018). *Textbook Of Veterinary Diagnostic Radiology Seventh Edition*, Elsevier.
- Vlăgioiu C., Tudor N. (2012). *Semiologie veterinară și tehnici de examinare*. Editura Sitech, Craiova.

THERAPEUTIC APPROACH IN MANAGING DEGLOVING INJURIES OF THE FRONT LIMBS IN A DOG - A CASE REPORT -

**Alexandra PETEOACA, Andreea ISTRATE, Ana GOANTA,
Gina GIRDAN, Alina STEFANESCU, Andrei TANASE**

University of Agronomic Sciences and Veterinary Medicine of Bucharest,
59 Mărăști Boulevard, District 1, Bucharest, Romania

Corresponding author email: alexandra_peteoaca@yahoo.com

Abstract

The aim of this case report is to present an accessible therapeutic approach that facilitates the healing of extensive degloving wounds. A 3 months old dog was presented to the emergency room for traumatic injuries with extensive tissue necrosis and infection of the front limbs. The animal was recumbent, tachypneic and exhibited pain. The temperature, blood pressure, heart rate were in the normal range. Further investigation revealed no osseous implication and a moderate to severe anaemia. The emergency treatment was focused on pain management, fluid therapy and primary care of the wounds. The wound management followed this succession: wet-to-dry dressings for the first two days, surgical debridement, honey dressings, hydrocolloid dressings alongside supportive therapy. This approach promoted the healing process, resulting in a full reepithelialization of the affected area, eliminating the need for skin grafts or reconstruction techniques. The honey and hydrocolloid dressings have to be properly used in the correct phase to offer a good healing environment for reepithelialization. We concluded that wound management should be a global approach that combines systemic and nutritional support with topical healing promoters.

Key words: degloving wound, honey dressing, hydrocolloid, infected wound, traumatic injury.

INTRODUCTION

Wound management is one of the most discussed subjects in medical literature. There are numerous articles that argue the advantages and disadvantages of commercial dressings. Comparative studies and detailed articles discuss each step of the healing process and recommend several protocols to apply in extensive wounds and burns. An agreement about the best products and the sequence in which they should be applied was never reached, but several guidelines have been created (Woodlands, 2014; Abramo et al., 2008; Anderson, 1996).

A degloving or a shearing wound represents a severe type of soft tissue injury in which the skin loses attachments to the subcutaneous tissue. Most times the affected skin is not completely detached, from the surrounding skin, but is disconnected from the tissues underneath (Tsioliet et al., 2019).

The most common cause of degloving injuries in dogs is the motor vehicle accident, during which the limbs are sheared in contact with the ground.

Frequently the distal area of the limbs is affected, a low number of cases present with thoracic or abdominal degloving injuries are mentioned in the literature.

It is unanimously believed that all patients with degloving wounds should be first considered as emergencies due to the traumatic shock and receive proper care and therapy according to this status. Wound management comes second and should begin only after the patient is stable, except in patients with massive active bleeding. Since degloving injuries arise from traumatic events often the level of wound contamination is really high. Until a long-term plan is conceived, the wound should be cleaned, dressed and analgesia should be provided.

The wound healing process can be divided into 4 stages:

- Inflammatory phase;
- Debridement phase;
- Proliferation phase;
- Maturation phase (Rice, 2000).

The inflammatory phase begins immediately after the traumatic event and defines the short interval in which the wound bed is filled with blood and lymph, in which vasoconstriction

followed by clot formation and vasodilation occur. This is the beginning of a series of events involving inflammatory cells and mediators that prepare the wound for the following healing stages.

In the debridement phase, the necrotic tissue (the non-viable tissue impeding the healing process and being a good environment for bacterial proliferation) is removed by an autolytic process.

The proliferation phase is characterized by granulation based on two main elements: capillaries and fibroblasts.

Wound contraction represents the centripetal movement which pulls wound margins towards its centre and diminishes its extent. Wound contraction happens simultaneously with granulation and stops when the tension in the surrounding skin is too high or when the wound edges are in direct contact.

Epithelialization is the third process of the proliferative phase that consists of epithelial cells proliferation and migration from the wound edges towards the middle of the defect.

The maturation phase lasts up to 1-2 years after the traumatic event occurred. The initial collagen is replaced by a stronger form of collagen, which determines an increase in strength of the scar tissue. The mature scar tissue will only reach 80% of the strength of the original epithelium, this new tissue being weaker, less elastic, without pigmentation, without hair follicles and sweat or sebaceous glands (Pavletic, 2010).

The products used in wound vary according to the healing phase.

After an initial thorough assessment, the wound has to be re-evaluated periodically to decide if changes have to be made in the management protocol chosen for each particular case (Bowl & Friend, 2011).

From a functional point of view wound care products can be classified as follows:

- Wound protection products;
- Wound hydration products;
- Moisture retention products;
- Exsudate management products;
- Wound debridement products.

Most products existing on the market for wound management have two or more of these properties and multiple potential uses

(Campbell, 2006; Doughty, 2005; Morgan et al., 1994; Ramsey et al., 1995; Stashak et al., 2004).

In this context, we are describing a case in which we managed degloving wounds using a complex medical approach, that combines topical application of several products and systemic support.

MATERIALS AND METHODS

The patient was presented during the night shift at the emergency room, after being found by the side of the road. Due to the fact that the dog was a stray, there was no background information. After a first assessment of the case, it could be said that the dog preferred lateral recumbency, it had degloving wounds on both front limbs and severe pain was evident when trying to change its position. Its rectal temperature was in the normal range (38.9°C), it was tachypneic, with a normal heart rate frequency. At the time of admission, the dog weighed 6 kg and was approximately 2 to 3 months old.

A rapid assessment of haemoglobin and hematocrit was performed on a Hemo Vet Veterinary Hemoglobin Analyzer, with the following findings: Hb 9.3 g/dL, Hct 27%. An intravenous catheter was inserted into the saphenous vein for intravenous (IV) fluids, the animal was hospitalized and admitted to the intensive care unit.

Analgesia was provided first as a bolus (buprenorphine) and was continued as a constant rate infusion, as a pain-free animal is one of the main goals of emergency medicine and wound management. An IV antibiotic was used (ceftriaxone) considering the high level of contamination of the wound bed.

Due to the extensive wounds that involved both front limbs up to humerus, with great alteration of the soft tissue, it was clinically impossible to determine if the bones were affected in the unanesthetised patient. The extent of the injuries in the left front limb was larger compared to the right. The injuries presented with extensive oedema and necrotic tissue, along with foreign bodies, dirt, grass awns, vegetable debris were easily visible. The hair was clipped and a wound toilet was performed

with saline solution and a covering bandage was applied until the next day.

The next morning the radiographic examination (Fig. 1) revealed no osseous implication, although clinically there was a visible leg axis deviation, probably caused by the articular and soft tissue injuries and potential nutritional deficiency.

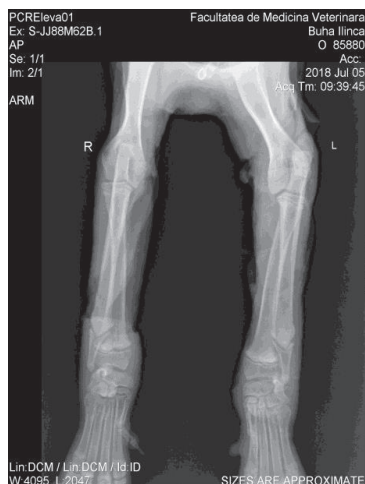

Figure 1. Antero-posterior X-Ray of the front limbs

Once a fracture was excluded, a carpal hyperextension syndrome was suspected, ligament injuries in the carpal region being a differential diagnosis.

A complete blood count and serum chemistry were performed. Low hematocrit and hemoglobin levels associated with low total protein were the most worrying laboratory findings. Due to the large area of skin loss, a great amount of plasma and implicitly protein was lost through extravasation similar to burn patients with extensive wounds.

To combat the protein loss and anaemia, a fresh blood transfusion was performed. IV fluids were given for several days alongside antibiotic and analgesic therapy. Due to the cost of the treatment and the good evolution of the wound healing, the owner declined the antibiogram. Malnutrition alters the healing process, thus nutritional support must be provided. Sometimes the animal is in too much pain to eat and simply addressing this issue will solve the lack of appetite.

More rigorous wound management was started on the second day of hospitalization. Although

analgesics were given, the animal exhibited a high level of pain and therefore sedation was required for mechanical debridement and dressing application. The dog was recumbent for the first few days.

At this point, some of the necrotic tissue that was clearly non-viable was removed. Grass awns that migrated and were visible on the surface of the wound and healthy skin were extracted. The soft tissue that remained intact on the front limbs was swollen.

On day 4 a surgical debridement under general anaesthesia was performed, removing all non-viable tissue and trying to preserve all questionable viable tissues for later re-evaluation (Fig. 2).

On the same day, a CBC (complete blood count) revealed decreased hemoglobin and hematocrit levels (Hb 7.7 g/dL, Ht 23%), and a second transfusion was done.

The autolytic debridement was really slow and a ring of necrotic tissue began to act as a tourniquet making it necessary to perform a surgical debridement to create clean and active wound edges to promote and facilitate healing. Although the left forelimb was covered with a flap of skin, there was no vascularisation and this tissue became necrotic and had to be removed. All tissue that seemed viable was preserved.

The wound appeared clean, but there was extensive exudation and more autolytic debridement was expected to occur.

During the first couple of days, the dressings were changed twice daily, using a dry-to-dry bandage technique at first and then using a silver sulfadiazine ointment as an antiseptic under the dry gauze.

Starting day 4 a honey dressing was chosen for this case, for the remaining of the debridement phase in order to promote granulation (Fig. 3).

The evolution was favourable, the dog started eating by itself, began to walk for short periods of time and exhibited less pain. Alongside the dressings, systemic support was provided with

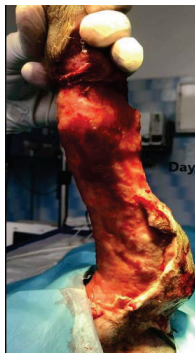

Figure 2. Aspect of the left front limb after the surgical debridement

pain medication, antibiotics, osteoarticular supplements and a balanced diet for growing dogs.

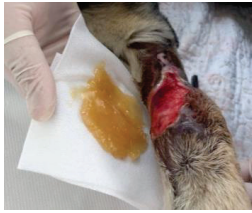

Figure 3. Applying a honey dressing over a wound

For the first week, the bandages were changed twice daily. At each bandage change, the wound was lavaged with a lactated Ringer's solution, removing all the dead tissue and exudate, leaving the wound bed clean and less susceptible to bacterial infection. The lavage was stopped as soon as the granulation started and the wound had a clean aspect (Buffa et al., 1997).

Honey dressings were used due to the multiple healing properties that honey offers and due to the low cost of this technique.

Honey was applied both directly on the wound or on the gauze, and we found it best to add the honey to the dressing and then apply it on the wound surface, rather than directly on the wound. When the exudation is more intense is better to use more fluid honey, at body temperature. When the granulation process begins and the exudation diminishes it is better to use a more solid form of honey, which is easier to apply, especially when large areas are involved and because it takes more time until it is absorbed by the gauze (Fig. 4).

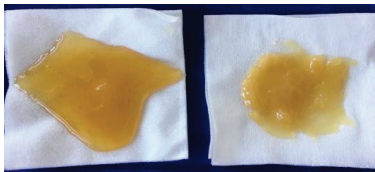


Figure 4. Honey dressings: liquid honey (left) and christalized honey

between the gauze and the wound, thus preventing the gauze to act as a wet to dry bandage.

For the first couple of days, we used a coarse woven gauze, recommended for the debridement stage. This type of dressing is not

intended for direct contact with the wound, as it leaves lint, is abrasive and not sufficiently absorbent. A non-woven gauze was used for the following days. The latter has superior absorbent capacity due to the fibres being tightly pressed together. This fabric is softer and more resistant to tear, leaves little to no fibres and adheres less to the wound bed. We found that having increased absorbency prevents the honey from reaching the outer layers of the bandage for a longer period of time (Fig. 5).

In order to facilitate the development of a healthy bed of granulation, the honey dressing was changed twice daily for the first week followed by a daily change of the dressings (Gethin, 2008).

The wound was reassessed daily as the patient was hospitalized. To prevent damage to the

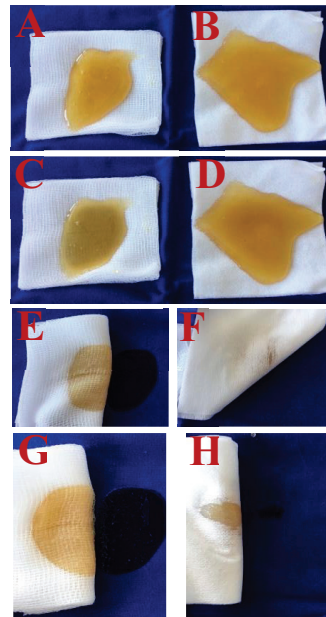


Figure 5. Absorbency difference between woven and non-woven gauze when used for honey dressings: A-honey application on a woven gauze; B-honey application on a non-woven gauze; C-aspect of the honey dressing after 30 minutes (woven gauze); D-aspect of the honey dressing after 30 minutes (non-woven gauze); E-honey absorbed into the woven gauze after 30 minutes; F-honey slightly absorbed into the non-woven gauze after 30 minutes; G-honey absorbed into the woven gauze after 120 minutes; H-honey slightly absorbed into the non-woven gauze after 120 minutes

bandages and perturbation of wound healing, the dog wore an Elizabethan collar during the entire treatment period.

The application of honey dressings was ceased on day 13 when the wound had a healthy granulation bed that allowed the second intention healing to occur and the epithelialization process started (Vyhlidalova et al., 2018).

From this point, hydrocolloid dressing was used (Fig. 6). The hydrocolloid dressing was changed every other day for the first week and then at every 3-4 days (Gouletsou et al., 2016), (Thomas, 2008).

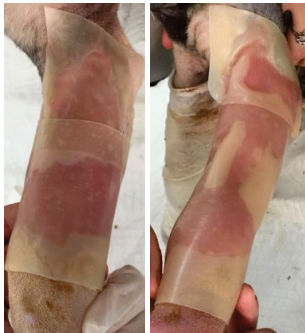

Figure 6. Hydrocolloid dressing applied of the left and right leg starting day 13

The patient was discharged after 39 days.

The wound bed shrunk considerably on the left leg, while the wounds on the right leg were closed at the time of the discharge.

The owner had to bring the dog to bandage change twice per

week, the evolution under the hydrocolloid dressing being satisfactory (Hess, 1999).

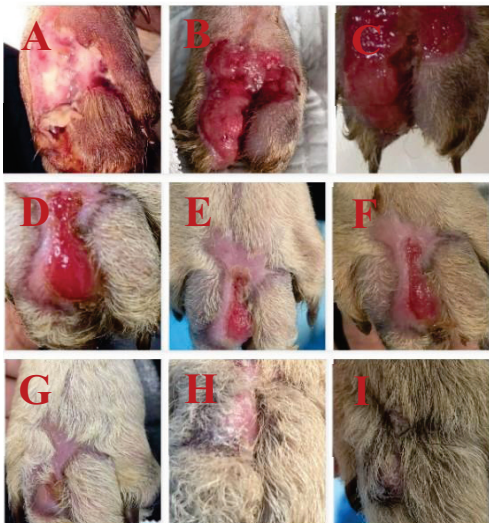


Figure 7. Right front leg digital wound aspect (A-day 2; B-day 11; C-day 13; D-day 26; E-day 29; F-day 31; G-day 37; H-day 45; I-day 52)

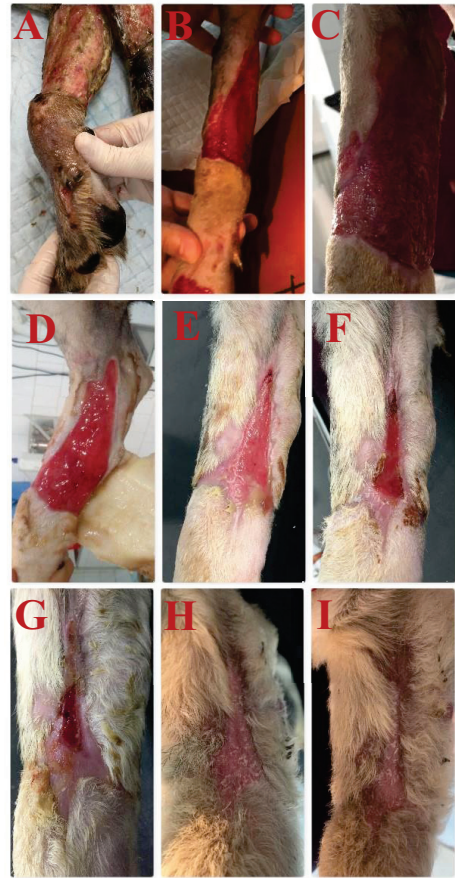

Figure 8. Right front limb wound healing aspect (A-day 2; B-day 9; C-day 11; D-day 15; E-day 29; F-day 34; G-day 37; H-day 45; I-day 52)

The evolution of the wound healing process during the first 52 days is presented in Figures 7, 8 and 9.

The owner stopped bringing the dog for bandage change for almost 3 weeks, doing this procedure in a different clinic. The dog left unsupervised and without the E-collar for a couple of days. The dog was brought back to the clinic on day 80 with a contaminated wound on the left leg, larger than the defect that it had on the last follow-up (day 52). The dog was rehospitalized and the wound management was reconsidered. After the wound regained a clean aspect, using lavage and a hydrocolloid paste, we went back to the Hydrocolloid dressings, which we changed every 2-3 days.

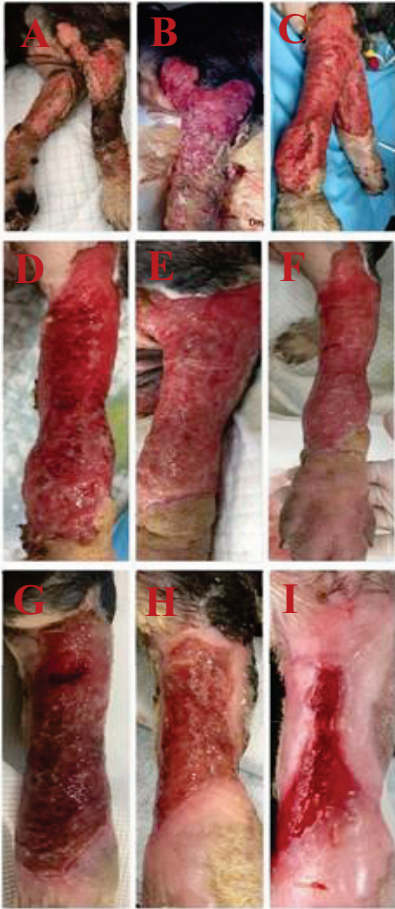

Figure 9. Left front limb wound healing aspect (A-day 2; B-day 5; C-day 6; D-day 10; E-day 12; F-day 13; G-day 27; H-day 39; I-day 52)

A complication that we encountered using only the hydrocolloid dressing was hypergranulation, a process which stops the healing process by pausing it during the granulation phase (Fig 10).

The new epithelium that is forming, can't slide over the granulation bed, which makes the wound contraction also impossible.

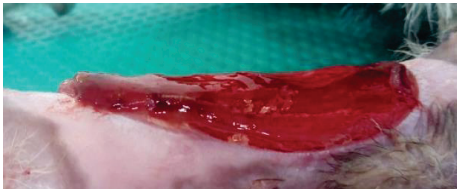


Figure 10. Hypergranulation aspect of the wound. A rim of granulation tissue developed, interfering with the epithelialization and wound contraction

To solve this problem we changed the dressing again, using the honey dressing with a daily change for the following period.

The patient remained hospitalized until the primary healing process occurred, with full wound closure. The left leg, that had more extensive wounds, has fully re-epithelialized at day 170 (Fig. 11).

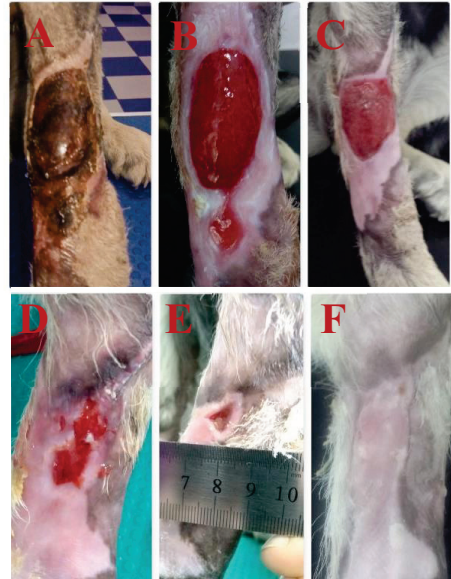


Figure 11. Left front limb wound aspect during the second hospitalization period (A-day 80; B-day 94; C-day 116; D-day 136; E-day 164; F-day 170)

The recommendation for these cases is to proceed with as much caution as before the wound is closed, due to the fact that the new epithelium is really thin and fragile, gaining strength slowly over a long period, which can extend up to 1.5 years.

If the dog is restless, tends to excessively lick the wound area and is prone to reopen the wound, it should continue to wear the e-collar and/or some sort of protective bandage over the newly re-epithelialized area.

The dog was discharged with fully healed front limbs, at almost 7 months of age, and a weight of 23 kg (Fig. 12). A slight lameness of the front




Figure 12. Full re-epithelialization of the shearing wounds (day 200)

left leg could be observed after excessive effort, but with no pain exhibited on the orthopaedic examination.

RESULTS AND DISCUSSIONS

Using this complex approach we obtained full epithelization of these shearing wounds located on the front limbs, with medium scarring and with hair regrowth over a significant area.

Often a lingering foreign body is a common cause for delayed healing, in this case, several grass awns were found in the soft tissue surrounding the wound, once the inflammation started to diminish.

Due to the anatomical characteristics of the affected area, where the muscular structures are poor and the skin is less elastic than in other areas, and tightly covers the limbs, the wounds couldn't be closed with sutures (Budras et al., 2007). Tension sutures weren't a choice either, the peri-wound tissues were not healthy enough to hold the sutures.

A surgical approach that could've been considered in this case, was the use of a skin graft, but this reconstruction technique was impossible as the lesion had intense exsudation and oedema, low vascularization, and thin edges of uncertain viability. The wounds characterised by these elements are best left to heal by second intention.

A dog with anaemia suffers delayed wound healing due to the fact that less oxygen reaches the affected tissues, and addressing this problem implicitly helps with the healing process.

Although at first, we preferred to apply tight bandages to help diminish local oedema, the other layers of bandage should be applied looser, to allow the oxygen to reach the wound, oxygen is one of the essential elements a wound needs to heal.

The bandage had to cover the paw, as the distal extremity was prone to swelling due to the damaged venous and lymphatic system of the limbs.

A properly made bandage has to have a layer that is in direct contact with the wound called the dressing (different types as described in the article), a second absorptive layer and an outer protective layer, each of these having an important role in wound management (Fig. 13).

While the honey has to extend its coverage beyond the wound edges, the hydrocolloid dressing should only cover the wound bed, as it may lead to maceration of the skin when left in contact with the healthy tissue for several days.

There is a lot of controversy around honey dressing and which type is best for topical medical use (Malone & Tsai, 2016; Mathews et al., 2001; Medhi et al., 2008; Ruiter et al., 2007; Bergman et al., 1983). From our experience the crystallized form is better from a technical point of view, being easier to apply and remaining longer on the wound surface until it is absorbed into the bandage.

We used crystallized acacia honey from a local producer, not a store brand. The only FDA (Food and Drug Administration) approved honey is the Manuka Honey, but a lot of articles on wound management both in humans and animals, mention other types of honey being used, especially raw honey, with the main concern being clostridial contamination (Bischofberger et al., 2011; Grego et al., 2016). There are commercial honey ointments but they are recommended for less extensive injuries. The topical application of honey offered a physical barrier against contamination because of its viscosity, and through its antiseptic properties.

Under the honey dressing, the wound underwent an autolytic debridement, removing all necrotic tissue in a couple of days. The honey deodorized the wound, promoted angiogenesis and granulation by providing a moist, nutritional, antimicrobial environment.

Using honey as a dressing choice is more messy and difficult to handle compared with the more modern wound dressings, but these technical difficulties can be easily overcome (Bose, 1982; Yaghoobi et al., 2013).

The hydrocolloid dressing provided a moist environment, by promoting epithelialization and wound contraction under a gel-like layer, held within an adhesive outer layer that is

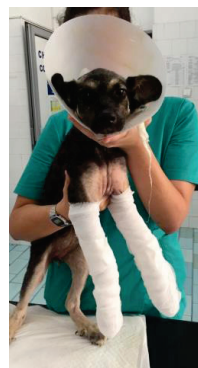

Figure 13. The aspect of the covering bandage

hydrophobe and impermeable to other contaminants (Singh et al., 2004). The wound remained hydrated while the mild drainage was absorbed by the hydrocolloid dressing. These dressings do not require frequent changes and are less painful to change, allowing the wound to heal undisturbed. The hydrocolloid allowed the healing to move forward because if the repair phase, during which granulation occurs, persists, the epithelization will be stopped or delayed, as it was the case during the second hospitalization.

CONCLUSIONS

This case illustrates that the honey dressing is a good choice for the first stages of the healing process until epithelialization starts; the hydrocolloid dressing offers a good environment for wound healing during the proliferation phase; the efficacy of the combined use of honey and hydrocolloid dressings should be proved in a complex study on multiple dogs with various wound types; There is not a single dressing that works in all the healing phases and each wound has to be assessed individually and re-evaluated periodically and the bandage changed in accordance with the healing process. Proper care and monitoring are easier if the animal is hospitalized at least for the first period. Systemic support should be provided, the case should be approached globally and focus should not remain solely on wound management. Several complications should be expected as wound healing is a complex and time-consuming process, these often being slow to heal injuries.

REFERENCES

- Abramo, F., Argiolas, S., Pisani, G., Vannozi, I. and Miragliotta, V. (2008). Effect of a hydrocolloid dressing on first intention healing surgical wounds in the dog: a pilot study. *Australian Veterinary Journal*, 86(3), pp.95-99.
- Anderson, D. (1996). Wound management in small animal practice. *In Practice*, 18(3), pp.115-128.
- Bergman, A., Yanai, J., Weiss, J., Bell, D. and David, M. (1983). Acceleration of wound healing by topical application of honey. *The American Journal of Surgery*, 145(3), pp.374-376.
- Bischofberger, A., Dart, C., Perkins, N. and Dart, A. (2011). A Preliminary Study on the Effect of Manuka Honey on Second-Intention Healing of Contaminated Wounds on the Distal Aspect of the Forelimbs of Horses. *Veterinary Surgery*, p.n/a-n/a.
- Bose, B. (1982). HONEY OR SUGAR IN TREATMENT OF INFECTED WOUNDS?. *The Lancet*, 319(8278), 963.
- Bowl, K. and Friend, E. (2011). Small animal wound management: Options for wound closure. *Companion Animal*, 16(5), pp.13-18.
- Budras, K., McCarthy, P., Fricke, W., & Richter, R. (2007). *Anatomy of the Dog* (pp. 16-28). London: Manson Pub.
- Buffa, E., Lubbe, A., Verstraete, F. and Swaim, S. (1997). The Effects of Wound Lavage Solutions on Canine Fibroblasts: An In Vitro Study. *Veterinary Surgery*, 26(6), pp.460-466.
- Campbell, B. (2006). Dressings, Bandages, and Splints for Wound Management in Dogs and Cats. *Veterinary Clinics of North America: Small Animal Practice*, 36(4), pp.759-791.
- Doughty, D., (2005). Dressings and More: Guidelines for Topical Wound Management. *Nursing Clinics of North America*, 40(2), pp.217-231.
- Gethin G. (2008). Efficacy of honey as a desloughing agent: overview of current evidence. *EWMA J* 8:31–35
- Gouletsou, P., Galatos, A., Psalla, D., Lymperis, A., Papazoglou, L., Karayannopoulou, M., Tsioli, V. (2016). Effects of two occlusive, hydrocolloid dressings on healing of full-thickness skin wounds in cats. *Veterinary And Comparative Orthopaedics And Traumatology*, 29(04), 298-305.
- Grego, E., Robino, P., Tramuta, C., Giusto, G., Boi, M., & Colombo, R. et al. (2016). Evaluation of antimicrobial activity of Italian honey for wound healing application in veterinary medicine. *Schweiz Arch Tierheilkd*, 158(7), 521-527.
- Hess, C. (1999). When to use hydrocolloid dressings. *Nursing*, 29(11), 20-21.
- Kirpensteijn, J., & Haar, G. (2013). *Reconstructive Surgery and Wound Management of the Dog and Cat* (1st ed.). Manson Publishing Ltd, pp.21-44.
- Malone, M., and Tsai, G., (2016). Wound healing with Apitherapy: A Review of the Effects of Honey. *Journal of Apitherapy*, 1(1), p.29.
- Mathews, Karol, Binnington, G., Allen. (2001). Wound Management Using Honey. *Compendium on Continuing Education for the Practising Veterinarian -North American Edition*.
- Medhi, B., Puri, A., Upadhyay, Sujata, Kaman, Lileswar. (2008). Topical Application of Honey in The Treatment of Wound Healing: A Metaanalysis. *JK Science: Journal of Medical Education & Research*.
- Morgan, PW, Binnington, AG, Miller, CW et al. (1994). The effect of occlusive and semi-occlusive dressings on the healing of acute full-thickness skin wounds on the forelimbs of dogs. *Vet Surg*, 23:494–502.
- Pavletic, M. (2010). *Atlas of small animal wound management and reconstructive surgery* (pp. 11-153). Hoboken: Wiley Blackwell.
- Ramsey, DT, Pope, ER, Wagner-Mann, C, Berg, JN, Swaim, SF. (1995). Effects of three occlusive

- dressing materials on healing of full-thickness skin wounds in dogs. *Am J Vet Res*;56:941–949.
- Rice, J. (2000). Secondary Intention Wound Healing-Pathophysiology and Management. *Collegian*, 7(3), 40-41.
- Ruiter, M., Rijkenhuizen, A. (2007). Topical application of honey: An alternative way of treating wounds in veterinary medicine?. *Pferdeheilkunde Equine Medicine*, 23(1), 70-76.
- Singh, A., Halder, S., Chumber, S., Misra, M., Sharma, L., Srivastava, A. and Menon, G. (2004). Meta-analysis of Randomized Controlled Trials on Hydrocolloid Occlusive Dressing Versus Conventional Gauze Dressing in the Healing of Chronic Wounds. *Asian Journal of Surgery*, 27(4), pp.326-332.
- Stashak, T., Farstvedt, E. and Othic, A. (2004). Update on wound dressings: Indications and best use. *Clinical Techniques in Equine Practice*, 3(2), pp.148-163.
- Thomas, S. (2008). Hydrocolloid dressings in the management of acute wounds: a review of the literature. *International Wound Journal*, 5(5), 602-613.
- Tsioli (B. ΤΣΙΩΛΗ), V., and Dermisiadou (E. ΔΕΡΜΙΣΙΑΔΟΥ), E. (2019). *Management of distal limb skin defects in dogs and cats*.
- Vyhlídalová, D., Kozáková, R., & Zeleníková, R. (2018). Management of non-healing wounds with honey dressings: a literature review. *Central European Journal Of Nursing And Midwifery*, 9(3), 880.
- Woodlands, C. (2014). Wound management in veterinary practice. *Veterinary Nursing Journal*, 29(3), pp.83-86.
- Yaghoobi, R., Kazerouni, A., Kazerouni, O. (2013). Evidence for Clinical Use of Honey in Wound Healing as an Anti-bacterial, Anti-inflammatory Anti-oxidant and Anti-viral Agent: A Review. *Jundishapur Journal Of Natural Pharmaceutical Products*, 8(3), 100-104.

REVERSAL OF CARDIAC PATHOLOGY BY ECHOCARDIOGRAPHY IN A DOG WITH SEVERE PULMONARY HYPERTENSION SECONDARY TO HEARTWORM DISEASE - CASE REPORT

Alice RADULESCU¹, Beatrice CRISTESCU¹, Pamela HARRIGAN², Lucian IONITA¹

¹University of Agronomic Sciences and Veterinary Medicine of Bucharest, Faculty of Veterinary
Medicine, Bucharest, Romania, alice@medicalvet.ro

²Pet Animal Ultrasound Services, Hanson, Massachusetts, USA, 4paus@comcast.net

Corresponding author email: alice@medicalvet.ro

Abstract

Canine pulmonary hypertension is a common complication secondary to Heartworm disease. Pulmonary artery occlusion with adult worms, secondary endarteritis, and thromboembolism lead to increased pulmonary pressure and right ventricular pressure with severe consequences on the structure and function of the right heart. Although new advanced diagnostic techniques and new drugs are useful in diagnosis and management, pulmonary hypertension is often an irreversible and progressive disorder. This case report documents the resolution of pulmonary hypertension and subsequent cardiac changes in a dog diagnosed with severe pulmonary hypertension associated with Heartworm disease by 2D, M-mode, and Doppler echocardiography. Comparative echocardiographic assessments performed before and after treatment revealed a rapid reduction in pulmonary pressure and a significant improvement in echocardiographic parameters. Follow-up echocardiographic assessments confirmed the resolution of cardiac changes more than four years after confirmation of the diagnosis.

Key words: Doppler, echocardiography, Heartworm disease, pulmonary hypertension.

INTRODUCTION

Pulmonary hypertension is a complex syndrome with multifactorial etiology characterized by the increase of pulmonary artery pressure above normal values. In veterinary medicine, pulmonary hypertension is defined as an estimated pulmonary arterial systolic pressure greater than 30 mmHg or pulmonary arterial diastolic pressure greater than 19 mmHg (Johnson et al., 1999; Kellihan and Stepien, 2010). Currently, diseases related to the development of pulmonary hypertension in humans are classified into 5 groups: 1) pulmonary hypertension due to pulmonary arterial vascular disease; 2) pulmonary hypertension due to left heart disease; 3) pulmonary hypertension associated with chronic respiratory disease or hypoxemia; 4) pulmonary hypertension caused by thrombotic or embolic disease and 5) pulmonary hypertension with multifactorial and unclear mechanisms (Galie et al., 2015). These categories have been adapted for use in dogs (Kellihan and Stepien, 2010); however, the number of diseases in each category is much

lower, either because the parallel condition does not occur in dogs or because it is not yet recognized in dogs (Poser and Guglielmini, 2016). Induced by the nematode *Dirofilaria immitis*, Dirofilariosis or Heartworm disease is a common cause of pulmonary hypertension in dogs (Johnson, 1999; Schober and Baade, 2006; Serrano-Parreno et al., 2017). A long-term occlusion of pulmonary arteries leads to pulmonary vascular proliferation, irreversible structural lesions, inflammation, and vascular dysfunction, typical changes for group 1. Conversely, worm death can cause pulmonary embolism and acute signs of pulmonary hypertension, and these are associated with pulmonary hypertension group 4 (Hirano et al., 1992).

The "gold standard" method for measuring pulmonary artery pressure in both humans and animals is right heart catheterization (Kellihan and Stepien, 2010; Galie et al., 2015). In veterinary medicine, catheterization of the heart is an expensive procedure available in a limited number of centers and usually requires deep sedation or anesthesia considered at high risk for unstable patients. Therefore, in veterinary

practice, echocardiography (available and non-invasive) is the standard method used for the diagnosis and monitoring of pulmonary hypertension (Kelliham and Stepien, 2010). Most information is obtained using 2D, M-Mode and Doppler echocardiography. Doppler evaluation of tricuspid regurgitation and pulmonic insufficiency provides an estimation of systolic and diastolic pulmonary arterial pressure, allowing diagnosis and quantification of pulmonary hypertension.

Pulmonary hypertension has been regarded in the past as a rare and incurable condition. In recent years, a better understanding of pathophysiological mechanisms, remarkable technical progress, and new drugs have led to better diagnosis and treatment; however, pulmonary hypertension often remains an irreversible and progressive disorder (Poser and Guglielmini, 2016). In veterinary literature, very few documented echocardiographic cases have been reported about the resolution of cardiac pathology in cases of severe pulmonary hypertension, and these are related to *Angiostrongylus* infection (Esteves et al., 2004), associated with Ehrlichiosis (Den Toom et al., 2016), or with indeterminate causes (Mc Mahon and Saelinger, 2015) but not secondary to Heartworm disease. This case report documents the resolution of pulmonary hypertension and subsequent cardiac changes in a dog diagnosed and treated with severe pulmonary hypertension associated with Heartworm disease by 2D, M-mode, and Doppler echocardiography.

MATERIALS AND METHODS

Sara, an eight-year-old female spayed Labrador Retriever presented for consultation with a history of intolerance to a minimal effort, dyspnoea, cough and one episode of syncope. Physical examination revealed: weight=32 kg, the rectal body temperature=39.0°C, heart rate=130 bpm and respiratory rate=50 rpm with an abdominal breathing pattern. Pulmonary auscultation showed mild, diffuse crackles. Cardiac auscultation revealed the presence of a grade IV/VI systolic murmur over the tricuspid area. The blood sample was tested serologically with a rapid immunochromatographic test (Snap 4Dx; IDEXX Laboratories), and it was

positive for *D. immitis*. In addition, the microscopic examination found circulating microfilaria which, in the Knott test, were identified as *D. immitis*. Hematology, biochemistry, and urinalysis showed mild eosinophilia, 1.6 K/uL (0.1–1.49 K/uL), mild proteinuria (100 mg/dl) and no other modifications. Electrocardiogram revealed deep S waves in leads II and aVF, right axis deviation and respiratory sinus arrhythmia. Thoracic radiographs showed moderate to severe increase in the size of the pulmonary artery branch, tortuous pulmonary artery branches, enlarged main pulmonary artery, right heart enlargement and moderate to severe patchy perivascular infiltration throughout the lungs. The abdominal ultrasound examination revealed hepatomegaly and liver vein enlargement, no ascites.

After performing the initial tests (physical examination, laboratory investigations, chest radiographs, and abdominal ultrasound), the dog was diagnosed with Heartworm disease class 2. Due to suspected secondary pulmonary hypertension, an echocardiogram was recommended for confirmation, severity, observation of the secondary structural and functional changes, and to assess for the presence of worms in the main pulmonary artery, right ventricle, and/or right atrium. The examination was performed by the same operator with a Logiq P6 ultrasonic machine (General Electric, New York, USA) equipped with a multifrequency array transducer (3 to 5.5 MHz). The dog was not sedated and was positioned in lateral recumbency, being examined in both the right and the left-sided views. Multiple echocardiography methods such as 2D, M-Mode, Color Doppler and Spectral Doppler were used in the evaluation.

2D and M-Mode echocardiographic findings

There was a moderate to severe right ventricular dilatation. The average size ratio of right and left ventricular chambers is about 1:3 (Boon 2011). In Sara's case, the right ventricle was markedly dilated, dwarfing the left ventricle. The left ventricular chamber appeared to be smaller than normal, and the free wall and septum were thick, possibly secondary to reduced preload. There was moderate right atrial enlargement and a

curvature of the interatrial septum toward the left atrium consistent with right atrial pressure overload. The right ventricular wall was found to be mildly thickened. Interventricular septal flattening and paradoxical motion consistent with right ventricular pressure overload were present.

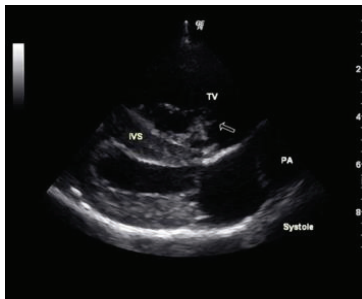
The interventricular septum curved into the left ventricular chamber on long axis view during both phases of the cardiac cycle. (Figure 1A, and 1B), and the flattening of the interventricular septum changed the left ventricular chamber from a circular shape to a triangular or “D”- shaped chamber on short axis view.

Paradoxical septal motion was evaluated using the eccentricity index. Normal eccentricity index during systole and diastole is 1 (one), in that the ventricle maintains its round shape throughout the cardiac cycle (Boon, 2011). In

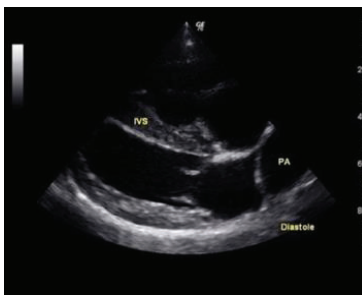
the subject case the eccentricity index was increased in both systole (1.72) and diastole (1.61) (Figure 2A, and 2B). The main pulmonary artery and left and right branches were dilated. The normal relationship between the pulmonary artery diameter and the aortic root diameter in the dog is less than 0.98 (Serres et al., 2007). In Sara's case, the ratio was 1.33 (Figure 3).

Pulmonic stenosis was ruled out by visualizing pulmonary valve structure and right ventricular outflow tract. Although the parasites can be often visualized echocardiographically in the right heart, pulmonary trunk or right pulmonary branch, in this case, no worms were observed.

The M-Mode measurements (Figure 4) were obtained and compared with M-Mode measurements in healthy Labradors Retrievers (Gugjoo et al., 2014).

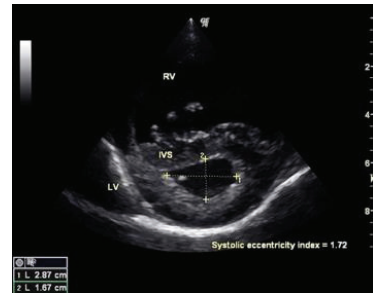


A

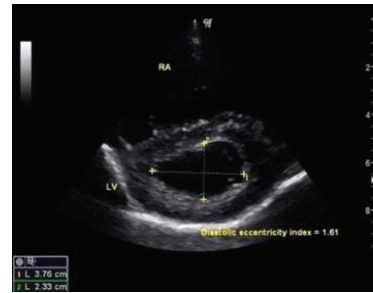


B

Figure 1. Right parasternal long axis four-chamber view in systole (A) and diastole (B). Severe right ventricular dilation and moderate right atrial enlargement, as well as displacement of the interventricular septum (IVS) and interatrial septum were observed. Right pulmonary artery dilatation (PA) and tricuspid valve (TV) prolapse were noted



A



B

Figure 2. Right parasternal short axis view in systole (A) and diastole (B). The left ventricle (LV) chamber has the shape of "D". The systolic and diastolic eccentricity index, calculated by dividing the width at the left ventricular chamber height, were increased (EI sys. = 1.72, EI dias. = 1.61)

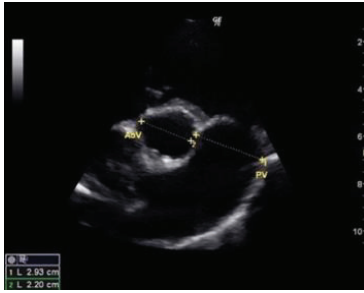


Figure 3. Right parasternal short axis view. The main pulmonary artery (PV) is dilated and the ratio between main pulmonary artery diameter and aortic root (Aov) was increased (MPA:Ao = 1.33)

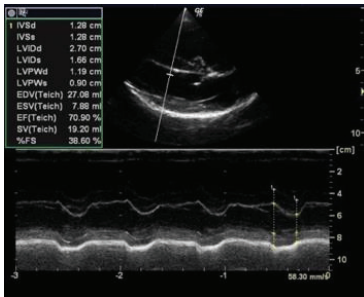


Figure 4. Right parasternal long axis four-chamber view M-Mode measurements. There was a reduced left ventricular diastolic diameter (LVDd = 27.0 mm, normal 37.58±1.05 mm), a reduced left ventricular systolic diameter (LVDs = 1.66 mm, normal 23.9±0.97 mm), a thickened interventricular septum in diastole (IVSd = 12.8 mm, normal 9.06±0.37 mm) and a thickened left ventricular free wall in diastole (LVPWd = 11.9 mm, normal 8.75±0.26 mm).

Doppler assessment of systolic pulmonary arterial pressure

Tricuspid regurgitation was present, secondary to the annular stretch and changes in right ventricular geometry. Tricuspid valve regurgitation occurred during ventricular systole and was viewed in the right parasternal and left apical views. The tricuspid regurgitation jet was assessed by using Color Doppler (Figure 5). CW Doppler was placed over the tricuspid regurgitation jet to obtain tricuspid velocity profiles. To achieve an accurate reading of the velocity, care was taken to have proper alignment of the CW Doppler cursor on the regurgitant jet direction. In our case, the best alignment was found in the right parasternal view and maximum velocity of the tricuspid regurgitant jet measured as $v=4.52$ m/s (Figure 6). By using the maximum

tricuspid regurgitation velocity, the pressure across the tricuspid valve was calculated, which approximated the pressure between the right ventricle and right atrium. This pressure gradient is calculated by applying the measured maximum tricuspid regurgitation velocity to the modified Bernoulli equation as follows: $pressure\ gradient = 4 \times 4.52^2 = 81.84\ mmHg$. The right ventricular pressure was estimated by adding to the calculated pressure gradient the estimated right atrial pressure. Right atrial pressure was estimated based on subjective assessment of the right atrium size. Because in our case the right atrium was moderately increased, an estimated right atrial pressure of 10 mmHg was used. The right ventricular systolic pressure which is normally equal with pulmonary systolic pressure calculated to be 91.84 mmHg, markedly elevated (normal pulmonary artery systolic pressure is approximately 20-25 mmHg).

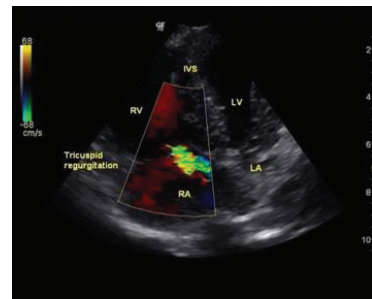


Figure 5. Left apical four-chamber view Color Doppler. The presence of eccentric tricuspid regurgitation jet was visualized

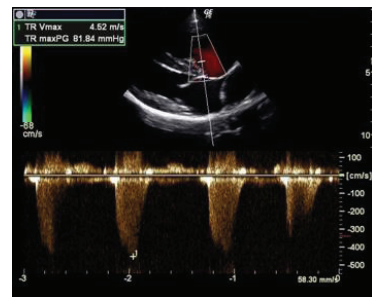


Figure 6. Right parasternal long axis four chamber view CW Doppler. The maximum tricuspid regurgitation velocity measured 4.52 m/s

Doppler assessment of diastolic pulmonary arterial pressure

Pulmonary valve insufficiency occurred in diastole and was best observed in the right parasternal short axis view. In this view, the pulmonary insufficiency jet assessed by Color Doppler. CW Doppler was placed over the pulmonary insufficiency jet to obtain pulmonary insufficiency velocity profiles. The pulmonary insufficiency velocity was measured to be $v=3.08$ m/s (Figure 7). Applying the modified Bernoulli equation, the pressure difference between the pulmonary artery and right ventricle was calculated: $pressure\ gradient = 4 \times 3.08^2 = 38.05\ mmHg$. The right ventricular pressure in diastole was assumed to be 0 mmHg; thus, the pressure gradient across the pulmonary valve in diastole was considered equal with diastolic pulmonary artery pressure. In this case, the calculated diastolic pulmonary artery pressure was 38.05 mmHg, which is high compared to the normal pulmonary artery pressure at the end of diastole of about 6-10 mmHg.

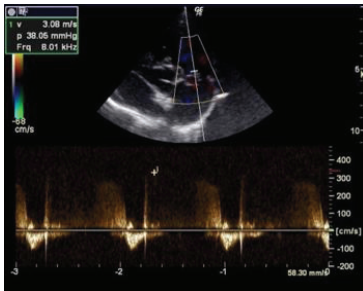


Figure 7. Right parasternal short axis view at the level of aorta and pulmonary artery. The pulmonic insufficiency velocity measured with CW Doppler was increased at 3.08 m/s

Doppler assessment of pulmonary flow profile

The pulmonary flow velocity profile was subjectively assessed and classified as type III (asymmetric profile and notching appears in the ascending section of the envelope) suggestive for severe PH (Boon, 2011).

Diagnosis and Treatment

Based on Sara's echocardiographic examination, the diagnosis of severe pulmonary hypertension secondary to *D. immitis* infection was confirmed. The initial established

therapeutic protocol was as follows: Prednisolone 1 mg/kg/day (the dose gradually reduced, and administration interval increased) for the reduction of inflammatory reactions and the treatment of allergic pneumonia; Doxycycline 10 mg/kg/day four weeks to eliminate the endosymbiont *Wolbachia*; Sildenafil 1.5 mg/kg twice daily for reducing vascular resistance and pulmonary pressure; Ivermectin 6 mcg/kg every three weeks to kill immature larvae and microfilaria; Benazepril 0.25 mg/kg twice daily and Furosemide 1 mg/kg twice daily for right heart failure symptoms. Oxygen supplementation and cage rest recommended. After one and a half months of treatment, Sara presented for reassessment. She was reported to be very well at home with regular activity, normal appetite, and normal breathing.

Physical examination revealed the resolution of right-sided murmur, a normal respiratory pattern and normal bronchovesicular sounds. Echocardiography showed a significant reduction in pulmonary hypertension and a marked improvement in cardiac changes that had been observed initially. 2D and M-Mode examination showed mild right ventricular and right atrial dilation, normal left ventricular dimension with normal left ventricular and interventricular septum wall thickness (Figure 8), resolution of normal septal configuration without septal flattening, normal eccentricity index (EI) both in systole and diastole (Figure 9), normal main pulmonary artery to aorta ratio (MPA: Ao).

The M-Mode measurements obtained were compared to normal M-Mode values in healthy Labradors (Gugjoo et al., 2014), and found to be normal (Figure 10). The Color Doppler examination revealed the presence of a trivial tricuspid regurgitation jet (Figure 11), as well as a trace pulmonary insufficiency jet (Figure 12) with a low-velocity flow that could not be accurately measured. In the absence of tricuspid regurgitation and pulmonary insufficiency, in order to detection and grading of pulmonary hypertension were used systolic time intervals (AT, ET, AT:ET) (Figure 13) (Schober and Baade, 2006), right pulmonary artery distensibility index (RPAD Index) (Figure 14) (Venco et al., 2014), and tricuspid annular plane systolic excursion (TAPSE)

(Figure 15) (Pariat et al., 2012); all these indicators were found to be normal.

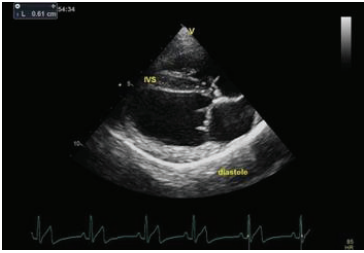


Figure 8. Right parasternal long axis-four chamber view. Mild right ventricular dilatation; no septal flattening

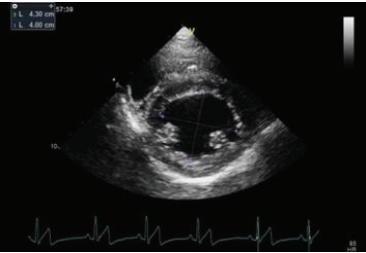

Figure 9. Right parasternal short axis view at the level of papillary muscles in diastole. The left ventricle has a normal circular shape; eccentricity index normal EI diastolic = 1.07

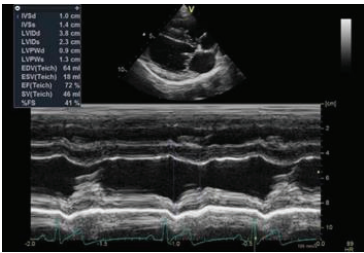


Figure 10. Right parasternal long axis four-chamber view M-Mode. There was a normal left diastolic diameter (LVDd = 3.8 cm) and a normal wall thickness (LVWd = 0.9 cm). No septal flattening observed

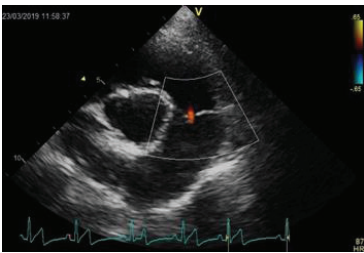


Figure 11. Right parasternal short axis view at the level of aorta and pulmonary artery. By using Color Doppler, the presence of trace pulmonic insufficiency with low velocities visualized

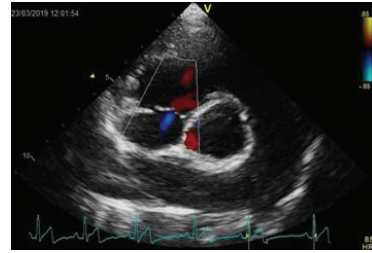


Figure 12. Right parasternal short axis view at the level of tricuspid valve. By using Color Doppler, the presence of tricuspid regurgitation with low velocities visualized

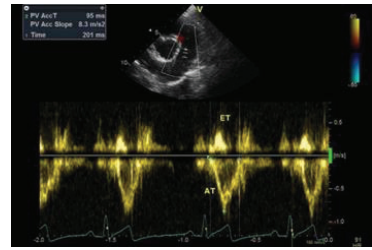


Figure 13. Right parasternal short axis view at the level of pulmonary artery PW Doppler. The pulmonary outflow acceleration time (AT), ejection time (ET) measured, and the ratio AT:ET calculated. The values are normal; ET =201 ms, AT =95 ms, AT:ET = 0.47

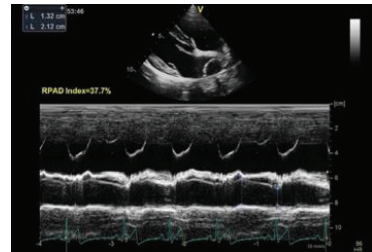


Figure 14. Right parasternal long axis view adapted for right pulmonary artery M-Mode. The Right Pulmonary Artery Distensibility Index (RPAD Index) calculated and normal value was found RPAD Index = 37.7%

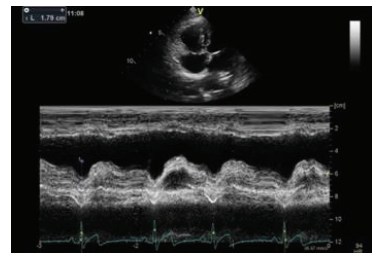


Figure 15. Left apical four chamber adapted for lateral tricuspid annulus M-Mode. Tricuspid annular plane systolic excursion (TAPSE) was acquired. Normal value was found TAPSE = 1.79 cm

With the resolution of right heart failure symptoms and significant reduction in pulmonary artery pressure, the treatment for right heart failure was discontinued and the dose of Sildenafil was reduced at 1mg/kg twice daily. According to AHS (American Heartworm Society) and ESDA (European Society of Dirofilariosis and Angiostrongylosis) recommendation, after patient preparation with Ivermectin and Doxycycline, adulticide protocol was initiated. The Melarsomine was administered as a deep intramuscular injection in dorsal lumbar musculature. One injection (2.5 mg/kg) was administered to kill the most sensitive adult worms. After one month from the first injection with Melarsomine, two more injections were administered 24 hours apart. For the entire period, Sara was in strict cage rest. About six months after Melarsomine treatment, the dog showed a negative result to the Heartworm antigen test. Following the adulticide protocol, the pulmonary damage did not aggravate, and the signs of pulmonary hypertension did not recur. The subsequent echocardiographic assessments over a four-year period confirmed the resolution of pulmonary hypertension and secondary cardiac changes.

RESULTS AND DISCUSSION

By correctly interpreting Doppler measurements and integrating 2D and M-mode echocardiographic results, pulmonary hypertension can be more accurately evaluated, leading to a better understanding of the pathophysiology of the disease. In our case, based on tricuspid regurgitation and pulmonary insufficiency, pulmonary arterial systolic pressure was estimated to be approximately 91.84 mmHg and pulmonary arterial diastolic pressure of about 38.05 mmHg, these values being very high compared to normal. The presence and severity of pulmonary hypertension were also assessed indirectly by identifying two-dimensional (2D) and time-motion (M-Mode) echocardiographic abnormalities, confirming pulmonary hypertension with significant cardiac pathology. Observed were: severe right ventricular dilatation with mild right ventricular wall thickness, moderate right atrial dilatation, severe interventricular septal flattening and paradoxical motion, moderate to

severe pulmonary arterial dilatation and decrease left ventricular volume with subjective thickening of the walls.

The structural characteristics of the right ventricle allow for good adaptation to large increases in blood volume (preload), but not to a rapid increase in arterial resistance (afterload).

Typically, the increase in pulmonary arterial resistance results in increased right ventricular contractility and subsequent concentric hypertrophy. If the size or rate of increase in pulmonary arterial pressure is too high, this mechanism fails and leads to an increase in the internal diameter of the right ventricle (eccentric hypertrophy) (Gaynor et al., 2005). The degree of concentric hypertrophy compared to eccentric hypertrophy can give information about chronicity and the possible causes of pulmonary hypertension. Severe concentric right ventricular hypertrophy is particularly common in chronic conditions, whereas severe eccentric right ventricular hypertrophy, is usually seen in acute conditions (Roberts and Forfia, 2011). In the subject case, there were no findings of compensatory hypertrophy, and in consequence, the assumption was that Sara had a poor compensatory response due to the acute increase in pulmonary pressure.

Comparative clinical and echocardiographic evaluations before and after treatment showed rapid resolution of the clinical signs and a marked improvement in the echocardiographic parameters. There were found: normal right ventricular and right atrial chamber, normal septal configuration both in diastole and systole, normal flow profile in the right ventricular ejection tract, and trace tricuspid regurgitation and pulmonic insufficiency with low velocities flow that could not be accurately measured.

In the absence of tricuspid regurgitation and pulmonic insufficiency, indicators such as Tricuspid Annular Plane Systolic Excursion (TAPSE), Acceleration Time (AT) and its ratio to pulmonary artery Ejection Time (AT:ET), and Right Pulmonary Artery Distensibility Index (RPAD Index), were used to assess pulmonary hypertension and were found to be normal. In dogs, one study showed that TAPSE was correlated with the severity of pulmonary

hypertension with different causes (Pariat et al., 2012). In another study, AT and AT: ET were useful indicators for predicting pulmonary hypertension in West Highland White Terriers with chronic pulmonary disease (Schober and Baade, 2006). The RPAD Index was predictive of pulmonary hypertension and very correlated with invasively measured pulmonary arterial pressure in dogs with Heartworm disease

(Venco et al., 2014). In our case, the RPAD Index was found at the normal upper limit, and the Windkessel effect characteristic of normal pulmonary artery morphology was not clearly, suggesting, however, the loss of elasticity of the arterial wall. Subsequent evaluations for about four years did not reveal recurrence, and the dog continued to be clinically healthy and normal echocardiographically. (Table 1).

Table 1. Echocardiographic measurement

Echocardiographic examination	First examination	1.5 months after	6 months after	1.5 year after	4 years after	Normal echocardiographic parameters
M-Mode parameters						
RVWd (mm)	6.7	6.5	6.2	6.1	6.1	
IVSd (mm)	12.8	10.0	10.0	11.0	10.0	9.06±0.37 (Gugjoo et al., 2014)
LVWd (mm)	11.9	10.0	10.0	10.0	9.0	8.75±0.26 (Gugjoo et al., 2014)
LVDd (mm)	27.0	38.0	38.0	36.0	38.0	37.58±1.05 (Gugjoo et al., 2014)
LVDs (mm)	16.6	22.0	22.0	20.0	23.0	23.98±0.97 (Gugjoo et al., 2014)
FS %	38.6	42	42	45	41	35.89±1.56 (Gugjoo et al., 2014)
B Mode Parameters						
EI dias.	1.61	1.1	1,14	1,07	1,07	Aprox 1.0 (Ryan et al., 1985)
EI sys.	1.72	1.2	1.14	1.10	1.18	Aprox 1.0 (Ryan et al., 1985)
MPA (mm)	29.3	27.5	24.1	23.7	23.3	
Ao (mm)	22.0	23.3	24.2	23.9	24.2	23.71±0.48 (Gugjoo et al., 2014)
MPA/Ao	1.33	1.18	0.99	0.99	0.96	<0.98 (Serres et al., 2007)
CW Doppler						
vTR (m/s) PASP (mmHg)	4.52 91.84	2.8 36.36	Trivial jet -	Trivial jet -	Trivial jet -	<2.8 (Kellihan and Stepien, 2010) <30
vPI (m/s) PADP (mmHg)	3.08 38.05	1.83 13.39	1.81 13.10	1.59 10.11	Trivial jet -	<2.2 (Kellum and Stepien, 2007) <19
PW Doppler						
vPAmx (m/s)	1.19	1.04	0.94	0.86	0.91	<1.3 (Boon, 2011)

RVWd: right ventricular wall in diastole; IVSd: interventricular septum in diastole; LVWd: left ventricular wall in diastole; LVDd: left ventricular diameter in diastole; LVDs: left ventricular diameter in systole; FS: fractional shortening; EI dias.: diastolic eccentricity index; EI sys.: systolic eccentricity index; MPA: main pulmonary artery; Ao: aorta; MPA/Ao: main pulmonary artery to aorta ratio; vTR: tricuspid regurgitation velocity; PASP: pulmonary artery systolic pressure; vPI: pulmonic insufficiency velocity; PADP: pulmonary artery diastolic pressure; vPAmx: maximum velocity through the pulmonary artery.

The aim of the treatment was first to stabilize the patients and then treat the causes. The acute onset of clinical signs has been attributed to the recent natural death of one or more parasites, dead worms, along with inflammation and platelet aggregation, leading to pulmonary thromboembolism, a sudden increase in pulmonary pressure, and development of acute signs of right heart failure. Although the initial therapeutic protocol was complex and each drug had its role; it was assumed that treatment with Prednisolone resulted in a significant reduction in the inflammatory response and contributed to the control of clinical signs of thromboembolism (Atwell and Tarish, 1995). Doxycycline, used to eliminate *Wolbachia*, was also an essential part of the treatment, this endo-symbiotic bacteria being an important factor in the occurrence of severe inflammatory response (Frank and Heald, 2010). Recent studies have shown a decrease in gross and microscopic pathology of pulmonary parenchyma in experimental Heartworm disease pretreated with Doxycycline before Melarsomine administration (Nelson et al., 2017). It was also appreciated that in this case, Sildenafil played an important therapeutic role, contributing to the reduction of pulmonary pressure and was associated with improvement in clinical signs. Studies conducted in canine models with pulmonary thromboembolism have shown that Sildenafil produces selective pulmonary vasodilation resulting in attenuation of pulmonary hypertension (Souza-Silva et al., 2005; Dias-Junior and Tanus-Santos, 2006). In some studies on the efficacy of Sildenafil in the treatment of pulmonary hypertension in dogs, pulmonary pressure reduction has been demonstrated (Bach et al., 2007; Brown et al., 2010), solving syncopal events, increasing exercise tolerance and improving quality of life (Kellum and Stepien, 2007; Toyoshima et al., 2007). Although, in Heartworm disease, therapeutic management involves certain risks, in our case, after adulticide treatment, no recurrence of pulmonary hypertension has been revealed. Otherwise, in a recent study of Heartworm disease in dogs, echocardiographic parameters were followed before and after adulticide treatment recommended by the American Heartworm Society, and no

worsening was observed (Serrano-Parreno et al., 2017).

In this case, the reasons for the significant improvement in clinical signs and resolution of the structural and functional changes of the heart, remain speculative. We can assume that a number of factors have contributed, including the degree of cardiopulmonary compromise (although severe, cardiac changes were acute, and therefore, perhaps, reversible) and patient response to therapy, both for cause and effect. Due to the potential for rapid and irreversible damage to pulmonary vasculature and right heart, pulmonary hypertension is a disease that needs to be investigated, recognized and treated appropriately. Although remarkable progress has been made in the diagnosis and therapy of the disease, more time and further studies are necessary for a better approach to this condition.

REFERENCES

- Atwell R., Tarish JH., 1995. *The effect of oral low-dose prednisolone on the extent of pulmonary pathology associated with dead Dirofilaria immitis in a canine lung model*. Proceedings of the heartworm symposium '95, pp.103–111 ref.28, American Heartworm Society, Batavia.
- Bach JF., Rozanski EA., MacGregor J., Betkowski JM., Rush JE., 2006. *Retrospective evaluation of sildenafil citrate as a therapy for pulmonary hypertension in dogs*. J Vet Intern Med. 20(5): 1132-5.
- Boon J.A., 2011. *Veterinary echocardiography second edition*. Ed. Wiley-Blackwell, Ames, Iowa.
- Brown AJ., Davison E., Sleeper MM., 2010. *Clinical efficacy of sildenafil in treatment of pulmonary arterial hypertension in dogs*. J Vet Intern Med. 24(4): 850-4.
- Den Toom ML., Dobak TP., Broens EM., Valtolina C., 2016. *Interstitial pneumonia and pulmonary hypertension associated with suspected ehrlichiosis in a dog*. Acta Vet Scand 58:46.
- Dias-Junior CA., Tanus-Santos JE., 2006. *Hemodynamic effects of sildenafil interaction with a nitric oxide donor compound in a dog model of acute pulmonary embolism*. Life Sci. 2006 Jun 27;79(5):469-74.
- Estèves I., Tessier D., Dandrieux J., Polack B., Carlos C., Boulanger V., Muller C., Pouchelon JL., Chetboul V., 2004. *Reversible pulmonary hypertension presenting simultaneously with an atrial septal defect and angiostrongylosis in a dog*. J Small Anim Pract. 45:206–9.
- Frank K., Heald R.D., 2010. *The emerging role of Wolbachia species in heartworm disease*. Compend Contin Educ Vet. 32(4):E4.
- Galie N., Humbert M., Vachiery JL., Gibbs S., Lang I., Torbicki A., Simonneau G., Peacock A., Noordegraaf

- AV., Begheti M., Gaynor SL., Maniar HS., Bloch JB., Steendijk P., Moon MR., 2005. *Right atrial and ventricular adaptation to chronic right ventricular pressure overload*. *Circulation* 112 (9 Suppl): 1212-8.
- Ghofrani A., Sanchez MAG., Hansmann G., Klepetko W., Lancellotti P., Matucci M., McDonagh T., Pierard LA., Trindade PT., Zompatori M., Hoepfer M., ESC Scientific Document Group., 2015. *Guidelines for the diagnosis and treatment of pulmonary hypertension*. *European Heart Journal*. 37(1): 67-119.
- Gugjoo MB., Hoque M., Saxena AC., Schamsuz MM., Dey S., 2014. *Reference values of M-mode echocardiographic parameters and indices in conscious Labrador Retriever dogs*. *Iranian Journal of Veterinary* 15(4): 341-346.
- Hirano Y., Kitagawa H., Sasaki Y., 1992. *Relationship between pulmonary arterial pressure and pulmonary thromboembolism associated with dead worms in canine heartworm disease*. *J Vet Med Sci* 54(5): 897-904.
- Johnson L., 1999. *Diagnosis of pulmonary hypertension*. *Clin Tech Small Anim Pract*. 14(4): 231-6.
- Johnson L., Boon J., Orton EC., 1999. *Clinical characteristics of 53 dogs with Doppler-derived evidence of pulmonary hypertension: 1992-1996* *J Vet Intern Med* 13(5): 440-7.
- Kelliham HB., Stepien RL., 2010. *Pulmonary hypertension in dogs: diagnosis and therapy*. *Vet Clin North Am Small Anim Pract*. 40(4): 623-41.
- Kellum HB., Stepien RL., 2007. *Sildenafil citrate therapy in 22 dogs with pulmonary hypertension*. *2007 J Vet Med* 21(6) 1258-64.
- Mc Mahon P., Saelinger C., 2015. *Reversal of echocardiographic right-sided heart pathology in a dog with severe pulmonary hypertension: a case report*. *Vet Med: Research and Reports* 6: 211-218.
- Nelson CT., Myrick ES., Nelson TA., 2017. *Clinical benefits of incorporating doxycycline into a canine heartworm treatment protocol*. *Parasites & Vectors* 10 (2):515.
- Pariaut R., Saelinger C., Strickland KN., Beaufre H., Reynolds CA., Vila J., 2012. *Tricuspid annular plane systolic excursion (TAPSE) in dogs: reference values and impact of pulmonary hypertension*. *J Vet Intern Med* 26(5): 1148-54.
- Poser H., Guglielmini C., 2016. *Pulmonary Hypertension in the dog* *Acta Veterinaria-Beograd* 66(1): 1-25.
- Roberts DJ., Forfia PR., 2011. *Diagnosis and assessment of pulmonary vascular disease by Doppler echocardiography*. *Pulmonary Circulation* 1(2) 160-181.
- Schober KE., Baade H., 2006. *Doppler echocardiographic prediction of pulmonary hypertension in West Highland white terriers with chronic pulmonary disease*. *J Vet Intern Med* 20(4): 912-20.
- Serrano-Parreno B., Carreton E., Caro-Vadillo A., Falcon-Cordon S., Falcon-Cordon Y., Montoya-Alonso JA., 2017. *Pulmonary hypertension in dogs with heartworm before and after the adulticide protocol recommended by the American Heartworm Society*. *Vet Parasitol*. 236:34-37.
- Serres F., Chetboul V., Gouni V., Tissier R., Sampedrano CC., Pouchelon JL., 2007. *Diagnostic value of echo-Doppler and tissue Doppler imaging in dogs with pulmonary arterial hypertension*. *J Vet Intern Med*. 21(6):1280-9.
- Souza-Silva AR., Dias-Junior CA., Uzuelli JA., Moreno H Jr., Evora PR., Tanus-Santos JE., 2005. *Hemodynamic effects of combined sildenafil and L-arginine during acute pulmonary embolism-induced pulmonary hypertension*. *Eur J Pharmacol*. Nov 7;524(1-3):126-31.
- Toyoshima Y., Kanemoto I., Arai S., Toyoshima H., 2007. *A Case of Long-Term Sildenafil Therapy in a Young Dog with Pulmonary Hypertension*. *Journal of Veterinary Medical Science* 69(10): 1073-5.
- Venco L., Mihaylova L., Boon JA., 2014. *Right Pulmonary Artery Distensibility Index (RPAD Index). A field study of an echocardiographic method to detect early development of pulmonary hypertension and its severity even in the absence of regurgitant jets for Doppler evaluation in heartworm-infected dogs*. *Vet Parasitology* 15;206 (1-2): 60-6.

SURGICAL TREATMENT OF A TRAUMATIC DIAPHRAGMATIC HERNIA IN A CAT USING STRATAFIX™ BARBED SUTURE: CASE REPORT

**Bogdan SICOE, Roxana DASCĂLU, Larisa SCHÜSZLER, Daniel BUMB,
Cristian ZAHA, Cornel IGNA**

Banat's University of Agricultural Sciences and Veterinary Medicine
"King Michael I of Romania" from Timisoara, Faculty of Veterinary Medicine,
119 Calea Aradului, Timișoara, România

Corresponding author email: ignacornel@gmail.com

Abstract

A diaphragmatic hernia occurs when organs from the abdominal cavity migrate into the thoracic cavity, through a discontinuity of the diaphragm. Traumatic diaphragmatic hernia occurs secondary to car accidents, falling from different heights, kicks or animal fights. There is no breed nor sex predisposition. Time-lapse of diaphragmatic hernia ranges from a few hours to years. Barbed sutures, used especially in human surgery, have certain advantages over traditional sutures: shorter suturing time, better tissue coaptation and better tension holding in the surgical wound due to evenly distributed barbs along the thread. This study describes the history, clinical signs, clinical and paraclinical investigations, surgical treatment, as well as post-operative care and follow-up of a feline patient with a traumatic diaphragmatic hernia. The suture material used in this case provided excellent tension in the surgical wound, leading to a full recovery of the patient within 10 days.

Key words: cat, diaphragmatic hernia, Stratafix™.

INTRODUCTION

In a traumatic diaphragmatic hernia, abdominal organs are displaced within the thoracic cavity through a disruption in the diaphragm (Fossum, 2013). The most common cause that leads to a traumatic diaphragmatic hernia is represented by car accidents (Fossum, 2013; Hunt & Johnson, 2003; Hunt & Johnson, 2012; Igna, 2017). A rapid increase in intra-abdominal pressure associated with a blunt trauma to the abdominal wall leads to lung deflation and increased pleuroperitoneal pressure gradient, which may result in diaphragmatic tears that usually result in its weakest points (the muscular portions) (Fossum, 2013). Duration from occurrence to clinical presentation may range from a few hours to years (Fossum, 2013; Hunt & Johnson, 2012). Clinical signs may include dyspnoea (Fossum, 2013; Garson et al., 1980; Hunt & Johnson, 2012; Igna, 2017; Minihan et al., 2004), shock-associated signs (tachypnea, tachycardia, cyanotic mucous membranes, arrhythmias) or may be system-dependent (gastrointestinal, respiratory, cardiovascular) (Fossum, 2013). Animals with

chronic hernias may even be asymptomatic, but clinical signs are either respiratory or gastrointestinal related, or may be non-specific (Fossum, 2013). The most commonly herniated organs are the liver (Besalti et al., 2011; Fossum, 2013; Garson et al., 1980; Hunt & Johnson, 2003; Hunt & Johnson, 2012; Hyun, 2004) stomach, small intestines, spleen and pancreas; colon, omentum (Besalti et al., 2011; Hunt & Johnson, 2012), and kidneys (Katic et al., 2007; Störk et al., 2003). The aspect of the disruption may be circumferential, radial or mixt (Garson et al., 1980). Diaphragmatic hernias may also be associated with hemothorax, hydrothorax, chylothorax, lung contusions and pneumonia (Baines, 2016). Standard radiography is the simplest way to confirm a diaphragmatic hernia (Hunt & Johnson, 2012). Complete or partial loss of diaphragmatic line, loss of cardiac silhouette, lung displacement and presence of abdominal organs inside the thoracic cavity are commonly seen (Dascălu, 2012; Fossum, 2013; Igna et al., 2006; Igna, 2017). Thoracocentesis may aid in diagnosis (Fossum, 2013). Oral administration of contrast mediums and positive contrast

celiography may also aid in diagnosis, but may also give false negative results (Dascălu, 2012; Fossum, 2013; Hunt & Johnson, 2012). Ultrasonography is another diagnostic method that may be useful, especially when radiographs are not diagnostic or pleural effusion is present. Laboratory findings are uncommon, unless herniation of liver is present (elevated serum alanine aminotransferase and serum alkaline phosphatase) (Fossum, 2013). Medical management consists in oxygen therapy, thoracocentesis and shock therapy. Surgical therapy should be applied as soon as the patient is stabilized and not be delayed unnecessarily. Certain cases, however, such as gastric herniation, should be treated as emergencies, due to the fact that gastric distension may lead to rapid, fatal respiratory failure (Fossum, 2013).

MATERIALS AND METHODS

A 4-year old European domestic short hair neutered female cat was presented in the Surgery Clinic of the Faculty of Veterinary Medicine from Timișoara regarding a non-healing wound on its caudo-ventral abdomen and a 4 day duration mild dyspnoea. The patient was an indoor-outdoor cat and was neutered in a private practice 10 days prior to presentation in our clinic; hence the non-healing wound was a ventral midline celiotomy. The patient received a combination of Ampiplus (ampicillin and sulbactam 20 mg/kg IV q8h) and Metronidazole (10 mg/kg IV q12h) for the last 3 days prior to presentation. Clinical examination was unremarkable, except for a mild dyspnoea and slightly obvious abdominal breathing, and a 4 cm long non-healing wound.

On auscultation, heart sounds were muffled on the right side and more intense on the left side; hyporesonance of the right thoracic wall was also noted. Blood work was unremarkable, and radiographic examination was pursued. Right lateral (Figure 1) and ventro-dorsal (Figure 2) radiographs of the thorax and abdomen were performed and the following were noted: on the lateral view, the diaphragmatic line is visible only in its most dorsal portion, the cardiac silhouette is difficult to visualise and appears elevated, the trachea is elevated, there is

generally increased soft tissue opacity within the central, ventral and caudal thorax, with only the cranial and caudal lung lobes being clearly visualised and a moderate interstitial to alveolar pattern located primarily perihilar.

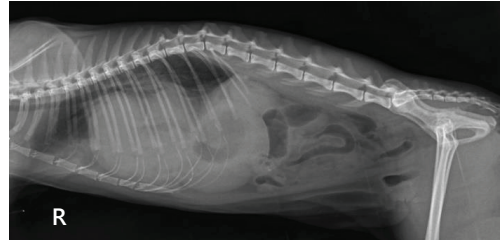


Figure 1. Right lateral view of the thorax and abdomen

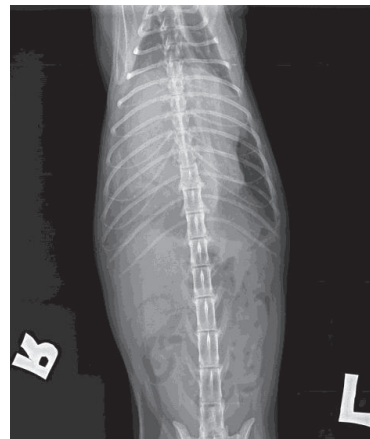


Figure 2. Ventro-dorsal view of the thorax and abdomen

Within the abdomen, the gastric gas bubble is abnormal in shape and abnormally located, and in the caudal portion of the ventral abdominal wall, free air/gas and some granular radio-opaque material is present between the *rectus abdominis* muscle and subcutaneous tissue and skin; on the ventro-dorsal view: the diaphragmatic line is visible in a small portion on the left side, there is collapse of the right middle lung lobe and part of the right cranial lung lobe, there is increased soft tissue opacity in the right middle-caudal and center of the thorax, masking the cardiac silhouette. Within the abdomen, the distal extremity of the spleen appears to be enlarged and rounded, and on both radiographs, there is overall mild loss of serosal detail and the liver also appears enlarged and rounded. No musculoskeletal abnormalities were noted on either radiograph. A diagnosis of traumatic diaphragmatic hernia

was established. The prognosis in this case was guarded.

The surgical procedure was performed under general anaesthesia, which consisted of premedication with Xylazine (0.05 mg/kg IV) and Ketamine (8 mg/kg IV) followed by induction with Isoflurane 5% and maintained on Isoflurane 2% vaporized in oxygen using intermittent positive pressure ventilation throughout the surgery. Postoperative analgesia was provided with one dose of Butorphanol (0.4 mg/kg SQ) administered 15 minutes before recovery. Ampiplus (ampicillin and sulbactam 20 mg/kg IV q8h) was administered 30 minutes preoperative and immediate postoperative. Dexamethasone (0.1 mg/kg IV) was also given to prevent reperfusion injuries of herniated organs and of the collapsed lung lobes.

The surgical site was aseptically prepared. The patient was placed in dorsal recumbency. A ventral midline celiotomy was performed, extending from the xyphoid process to the non-healing wound and the edges of the non-healing were excised. Celiotomy revealed herniation of the liver, stomach, spleen, omentum and falciform ligament inside the thoracic cavity (Figure 3), through an approximately 2.5 cm long central linear disruption of the diaphragm, extending from its most ventral portion towards the tendinous center (Figure 4).

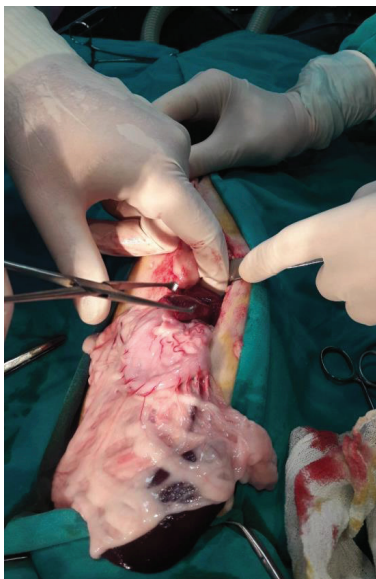


Figure 3. Removing the liver, stomach, spleen, omentum and falciform ligament from the thorax

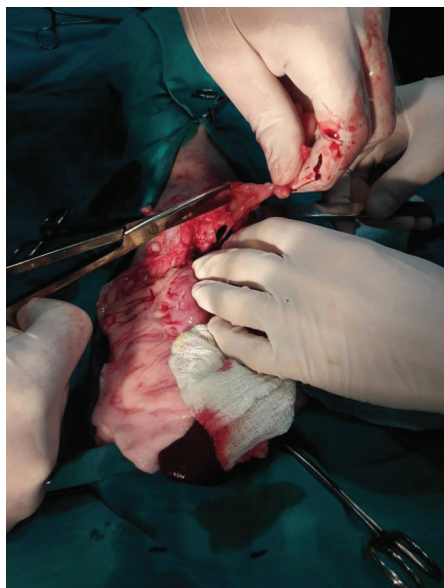


Figure 4. Intraoperative view of the diaphragmatic wound and beginning of the suture

Adherences were present between the two edges of the diaphragm and between the liver and diaphragm; these were severed using sharp dissection. Herniated organs were all viable and withdrawn from the thoracic cavity.

The liver and spleen were mildly enlarged, but viable. Lavage of the thoracic cavity was performed with warm sterile saline. Closure of the diaphragm was performed using unilateral Stratifix™ 2-0 Spiral PDS Plus (Ethicon™) (Figure 5).




Figure 5. Unilateral Stratifix™ 2-0 Spiral PDS Plus (Ethicon™) used for herniorrhaphy

The time required to close the rupture in the diaphragm was 1 min 52 sec, partly due to a quite large needle. The suture was started by passing the needle through the wound edges, in its most dorsal end, and then through the prefabricated loop on its other end, and was

continued in a simple continuous pattern. Suturing was interrupted to allow placing of a Foley catheter, and after reaching the ventral end of the wound, 2 more passes were made in the ventral abdominal wall. The Foley catheter was placed from the thoracic cavity into the abdominal cavity, and exteriorized through a stab incision performed cranio-dorsally in the right abdominal wall (Figure 6).

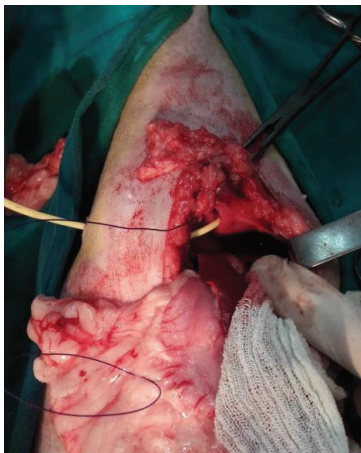


Figure 6. Placement of the Foley catheter

Lungs were not completely inflated as to prevent reexpansion edema and reperfusion injury; a small amount of warm sterile saline was left inside the thoracic cavity to aid in this purpose. Closure of the celiotomy incision was routine.

RESULTS AND DISCUSSIONS

Although some authors prefer to leave small amounts of air inside the chest in order to prevent reexpansion edema (Hunt & Johnson, 2012), we preferred to leave a small amount of warm sterile saline. During surgery, standard monitoring of the cardiovascular (blood pressure, heart rate, CRT) and respiratory (capnogram, respiratory rate after diaphragm closure, pulse oximetry) systems was performed and all parameters were within normal limits. Closure was airtight. In the immediate postoperative period, the patient did not require assisted ventilation. The cat was no longer dyspnoeic after recovery; hence, there was no need for oxygen supplementation. Nevertheless, the patient was managed in-house for the following 10 days, receiving

Ampiplus (ampicillin and sulbactam 20 mg/kg IV q8h) daily. An Elizabethan collar was also applied and maintained through-out hospitalization. On the first postoperative day, 4 ml of serohemorrhagic fluid was aspirated via the Foley catheter, clinical examination was unremarkable, dyspnoea resolved completely and the cat had eaten. On the second postoperative day, 1 ml of serous fluid was aspirated via the Foley catheter, clinical examination was unremarkable, and the catheter was removed. The remainder of the 8 days were uneventful; skin sutures were removed on the 10th day and the patient was discharged. Until publication of this case report, no complications were reported by the owner and follow-ups were unremarkable.

Tension in the suture was excellent, due to even distribution of the barbs along the thread. Edges of the wound were perfectly apposed; during suturing, there was no need for an assistant to maintain tension in portions that were already apposed, but only to hold the thread in such a manner that the surgeon had a proper view of the surgical field.

Postoperative survival rates differ according to several authors: 89.7% (Gibson et al., 2005), 50-90% (Igna, 2017), 88.4% (Igna et al., 2014) and 81.3%, respectively (Legallet et al., 2017). Complications after diaphragmatic herniorrhaphy include pneumothorax and reexpansion edema (Fossum, 2013; Igna et al., 2014), tachypnea and dyspnoea (Schmiedt et al., 2003), ascites, recurrence of the hernia, hiatal hernia, megaesophagus, gastric ulceration and esophagitis (Hunt & Johnson, 2012); none of these were observed during follow-ups nor were reported by the owner.

CONCLUSIONS

Stratafix™ unidirectional barbed suture provided an airtight closure of the diaphragmatic disruption, excellent apposition of wound edges and proper tension, with no signs of recurrence on a long-term follow-up.

ACKNOWLEDGEMENTS

This study was realised using the support and infrastructure project "Dezvoltarea infrastructurii de cercetare, educație și servicii în domeniile

REFERENCES

- Baines, S. J. (2016). Diaphragmatic Herniorrhaphy. In: Griffon, D., Hamaide, A., *Complications in small animal surgery*. (pp 375-382). Wiley Blackwell.
- Besalti, O., Pekcan, Z., Çalışkan, M., Aykut, Z. G. (2011). A retrospective study on traumatic diaphragmatic hernias in cats. *Veteriner Fakültesi dergisi.*, 58(3). 175-179.
- Dascălu, R. (2012). *Diagnosticul radiografic la animalele de companie*. Timișoara, RO: Editura BrumaR.
- Fossum, T. W. (2013). Surgery of the lower respiratory system. In: Fossum, T. W., *Small Animal Surgery*. 4th ed. (pp 1002-1007). St. Louis, USA: Mosby Elsevier.
- Garson, H. L., Dodman, N. H., Baker, G. J. (1980). Diaphragmatic hernia. Analysis of fifty-six cases in dogs and cats. *J. Small Anim. Pract.*, 21. 469-481.
- Gibson, T. W., Brisson, B. A., Sears, W. (2005). Perioperative survival rates after surgery for diaphragmatic hernia in dogs and cats: 92 cases (1990-2002). *J Am Vet Med Assoc*, 227(1). 105-109.
- Hunt, G.B., Johnson, K. A. (2003). Diaphragmatic, Pericardial, and Hiatal Hernia. In: Slatter, D., *Textbook of small animal surgery*. 3rd ed. (pp 471 – 480). Philadelphia, USA: Saunders.
- Hunt, G. B., Johnson, K. A. (2012). Diaphragmatic Hernias. In: Tobias, K. M., Johnston, S. A., *Veterinary surgery: small animal*. (pp 1380 – 1391). Missouri, USA: Elsevier.
- Hyun, C. (2004). Radiographic diagnosis of diaphragmatic hernia: review of 60 cases in dogs and cats. *J. Vet. Sci.*, 5(2). 157-162.
- Igna, C., Schüzler, L., Sala, A., Dascălu, R. (2006). Radiographic diagnosis of diaphragmatic hernia in dogs. *Lucr. Șt. USAMVB Timișoara, Med. Vet.*, XXXIX. 92-96.
- Igna, C., Schüzler, L., Sala, A., Bumb, D., Proteasa, A., Dascălu, R. (2014). Diaphragmatic hernia in dogs and cats: A report of 43 cases (2001-2013). *Lucrări Științifice Medicină Veterinară*, XLVII(4). 48-53.
- Igna, C. (2017). *Clinică chirurgicală și prelegeri clinice pe specii - curs universitar*. Timișoara, RO. Agroprint.
- Katic, N., Bartolomeaus, E., Böhler, A., Dupré, G. (2007). Traumatic diaphragmatic rupture in a cat with partial kidney displacement into the thorax. *J Small Anim Pract*, 48(12). 705-708.
- Legallet, C., Thiemann Mankin, K., Selmic, L. E. (2017). Prognostic indicators for perioperative survival after diaphragmatic herniorrhaphy in cats and dogs: 96 cases (2001-2013). *BMC Vet Res*, 13(1). 16.
- Minihan, A. C., Berg, J., Evans, K. L. (2004). Chronic diaphragmatic hernia in 34 dogs and 16 cats. *J Am Anim Hosp Assoc.*, 40(1). 51-63.
- Schmiedt, C. W., Tobias, K. M., Stevenson, M. A. (2003). Traumatic diaphragmatic hernia in cats: 34 cases (1991-2001). *J Am Vet Med Assoc*, 222(9). 1237-1240.
- Störk, C. K., Hamaide, A. J., Schwedes, C., Clercx, C. M., Snaps, F. R., Balligand, M. H. (2003). Hemiurothorax following diaphragmatic hernia and kidney prolapse in a cat. *J Feline Med Surg*, 5(2). 91-96.

HEMILAMINECTOMY FOR T11-T12 MEDULLAR COMPRESSION - PERIANAESTHETIC MANAGEMENT OF A GERIATRIC DOG

Ruxandra TUDOR, Andra DEGAN, Alexandru Gabriel NEAGU,
Luigi CARSTINOIU, Gabriel PREDOI

University of Agronomic Sciences and Veterinary Medicine of Bucharest,
59 Marasti Blvd, District 1, Bucharest, Romania

Corresponding author email: tudor_ruxandra89@yahoo.com

Abstract

This case report presents the perianaesthetic management of a geriatric dog that underwent a hemilaminectomy surgery for T11-T12 medullar compression. A 10-year-old crossbreed male was presented at the Faculty of Veterinary Medicine in Bucharest for neurological investigation of acute onset of right posterior unilateral paresis. The magnetic resonance investigation revealed T11-T12 medullar compression, with surgery indication (hemilaminectomy). The patient was premedicated with Fentanyl 3 mcg/kg and Midazolam 0.2 mg/kg administered intravenously (IV). Induction was made with Propofol 4 mg/kg intravenously. Afterwards, the patient was intubated and maintained with Isoflurane along with the administration of a constant rate infusion (CRI) with Fentanyl (3 mcg/kg/h) and Ketamine (1 mg/kg/h) and an epidural anaesthesia with Lidocaine (2 mg/kg). Postoperatively, the patient received a multimodal analgesia management to help her not to exhibit any pain levels.

Key words: geriatric dog anaesthesia, hemilaminectomy, perianaesthetic management.

INTRODUCTION

Perianaesthetic management of a patient for hemilaminectomy surgery is extremely important. Anaesthesia protocols should focus on a good management plan combined with the selection of the appropriate drugs. Management includes stabilization of the patient and a very careful handling. The most important part is represented by a good pain approach so that the patient actually wakes up more comfortable.

MATERIALS AND METHODS

A 10-years-old male crossbreed was presented at the Faculty of Veterinary Medicine in Bucharest for neurological investigation of acute onset of right posterior unilateral paresis. Complete physical examination and blood exams were performed. Following neurological examination, a medullar compression at the level of thoracic vertebrae T11-T12 was suspected. Magnetic resonance imaging was performed under general anesthesia and continuous monitoring (Tudor R.G., 2018). Surgical intervention was recommended so, a dorsal hemilaminectomy was performed. Patient premedication was made with Fentanyl

3 mcg/kg and Midazolam 0.2 mg/kg administered intravenously (IV). Anaesthesia was induced with Propofol 4 mg/kg IV. The patient was intubated and maintained with Isoflurane and Oxygen. A constant rate infusion (CRI) of Fentanyl (3 mcg/kg/h) and Ketamine (1 mg/kg/h) was given intravenously along Normal Saline 0.9%, at a total maximum rate of 5 ml/kg/h (Costea R., 2017).

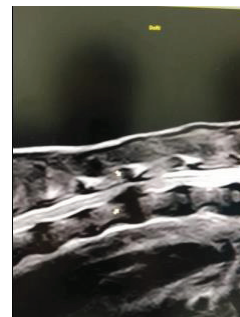


Figure 1. Magnetic resonance image
Medullar compression at the level of thoracic vertebrae
T11-T12

An epidural anaesthesia block with Lidocaine (2 mg/kg) was added in the protocol, to approach a multimodal analgesia. Monitoring during anesthesia included arterial blood

pressure non-invasively, heart rate, electrocardiography, haemoglobin saturation with oxygen (SpO₂), body temperature (measured with oesophageal temperature probe) and end tidal carbon dioxide. At the end of the surgery, the patient was moved in the intensive care unit for recovery and further monitorization. The patient was evaluated after the procedure using the Glasgow Composite Pain Scale (Tudor R, 2018) and the analgesia protocol adapted to it (Tudor, 2018). A continuous rate infusion of Lidocaine (50 mcg/kg/min) was initiated along with Buprenorphine (20 mcg/kg IV) administration. A urinary catheter was also placed because many patients with loss of motor control are unable to urinate and often suffer from an 'overflow bladder' or dribbling as the bladder reaches capacity and this can be distressing for the patient. This anxiety, frustration can compound the pain level and pain scoring of the patient and we had to take it into consideration. It is known that dogs with paraplegia before surgery had a higher frequency of urinary or fecal incontinence (Aikawa T., 2012).

RESULTS AND DISCUSSIONS

Anaesthesia in the critically ill patient can be challenging due to the multiple complications and the possibility of decompensation at any time.

A comprehensive pre-anaesthetic examination along with an appropriate protocol selection, regular attention and monitoring will lead to an early assessment of complications and a better outcome for the critically ill patient. A multimodal approach is recommended as this helps minimize the side effects that may occur (Costea R., 2016).

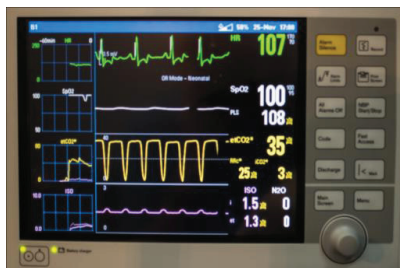

Figure 2. Continuous monitoring during anaesthesia

During the surgical procedure the patient was in a steady plane without any pain manifestations according to Glasgow Composite Pain Scale (Rheid J., 2007). A multimodal analgesic plan which included in premedication and maintenance Fentanyl, Ketamine and epidural anesthesia, combined postoperatively with Lidocaine and Buprenorphine has been proven to be a good approach for preventing acute pain following hemilaminectomy surgery.

CONCLUSIONS

A good perianaesthetic management during hemilaminectomy in dogs is mandatory to achieve a steady anaesthetic and analgesia level during the procedure and a good recovery of the patient. It is important to provide postoperative pain control protocols. Multimodal analgesia protocols for acute pain during the recovery period, will improve the prognosis and the evolution of the patient.

REFERENCES

- Aikawa, T., Fujita, H., Kanazono, S., Shibata, M., & Yoshigae, Y. (2012). Long-term neurologic outcome of hemilaminectomy and disk fenestration for treatment of dogs with thoracolumbar intervertebral disk herniation: 831 cases (2000–2007). *Journal of the American Veterinary Medical Association*, 241(12), 1617-1626.
- Buvanendran A, Kroin JS (2009). Multimodal analgesia for controlling acute postoperative pain. *Curr Opin Anesthesiol*; 22:588-93.
- Costea R. Anesthesia considerations for critically ill patients. *EJCAP volume 26* (3), 2016
- Costea, R., Degan, A., & Tudor, R. (2017). Crystalloids/colloids ratio for fluid resuscitation during anesthesia. *Scientific Works. Series C. Veterinary Medicine*, 63(1), 65-66.
- Reid, J., Nolan, A. M., Hughes, J. M. L., Lascelles, D., Pawson, P., & Scott, E. M. (2007). Development of the short-form Glasgow Composite Measure Pain Scale (CMPS-SF) and derivation of an analgesic intervention score. *ANIMAL WELFARE-POTTERS BAR THEN WHEATHAMPSTEAD-*, 16, 97.
- Tudor, R. G., Degan, A., Ivascu, C., Neagu, A., Costea, R., & Predoi, G. (2018). Monitoring geriatric dogs after intravenous gadolinium-containing contrast media administration for magnetic resonance imaging. *Journal of Biotechnology*, 280, S73.
- Tudor, R., Degan, A., Costea, R., & Predoi, G. (2018). Postoperative analgesic management of geriatric dogs that underwent soft tissue surgery. *Scientific Works. Series C. Veterinary Medicine*, 64(2), 82-87.

ENCEPHALITIS: CLINICAL APPROACH TO DIAGNOSIS AND A CASE SERIES REPORT

Raluca Mihaela TURBATU, Cristina FERNOAGĂ, Nicolae TUDOR, Constantin VLĂGIOIU

University of Agronomic Sciences and Veterinary Medicine of Bucharest, Faculty of Veterinary
Medicine, Department of Clinical Sciences,
105 Splaiul Independentei, Bucharest, Romania

Corresponding author email: raluca@yahoo.com

Abstract

Encephalitis represents inflammation of the brain tissue and is a common disease that affects especially the small-breed dogs. For a proper diagnostic, the patient history accompanied by a general and neurological examination are important elements. If neurological signs specific for forebrain localization are present, then a suspicion of an inflammatory lesion should be taken into consideration for the differential diagnostic list. For encephalitis, the list of differential diagnostic includes meningoencephalites of unknown origin (necrotizing meningoencephalitis, granulomatous meningoencephalitis, eosinophilic encephalitis) and infectious meningoencephalites (bacterial, fungal, rickettsial and viral). In 2018, more than 200 cases presenting neurological disorders were diagnosed in the Faculty of Veterinary Medicine of Bucharest. Considering the fact that encephalitis was a common diagnostic among these cases, this paper includes a presentation of predisposition factors and also clinical aspects that we used for a proper diagnostic approach.

Key words: neurological examination, sterile encephalitis, infectious encephalitis, forebrain disease.

INTRODUCTION

Encephalitis represents inflammation of the brain tissue and is one of the most common finding included in the forebrain pathology among the patients presented in the Clinic of the Faculty of Veterinary Medicine of Bucharest with neurological signs.

The etiology of encephalitis includes an infectious type (viral, bacterial, protozoal, rickettsial and fungal) and a noninfectious or autoimmune type (granulomatous meningoencephalitis, necrotizing meningoencephalitis, necrotizing leukoencephalitis, eosinophilic meningoencephalitis) (de Lahunta et al., 2015).

Considering the fact that clinical signs are rarely specific, elements like history and physical examination succeeded by a correct and complete neurological examination were performed for every patient and the neuroanatomic diagnosis was established. In patients with forebrain lesions, we performed the differential diagnosis using acronym „VITAMIND” (vascular, inflammatory/infectious, traumatic, anomaly, metabolic, idiopathic, neoplastic, degenerative) and we have established the paraclinical investigations

required in order to establish an etiological diagnosis (Dewey & da Costa, 2016).

Considering these facts, this paper aims to present a detailed analysis of the cases diagnosed with encephalitis (both infectious and sterile) during the year 2018: the diagnostic approach and the factors that were correlated with the disease onset.

MATERIALS AND METHODS

In order to perform a correct analysis of the cases consulted during the year 2018, a consultation protocol has been implemented. The protocol included certain stages, whose order has been strictly followed: animal signalment, history, physical and neurological examination, neurolocalisation of the disease, differential diagnosis, recommendations of paraclinical investigations and, in the end, etiological diagnosis (or a suspicion diagnosis when the etiological diagnosis could not be established).

The period analysed in this study was 1 of January 2018-31 of December 2018.

All cases have been registered in the Consultation Register and the collected data

have been statistically analysed, so the conclusions reflect the most important factors that are correlate with encephalitis in our clinic.

RESULTS AND DISCUSSIONS

Among the 1900 cases that were diagnosed in the Clinic of the Faculty of Veterinary Medicine of Bucharest, for this study we have chosen 209 cases with predominant neurological signs specific for a certain region of the brain (10.96 % from the total number of cases). For a better understanding of the diagnostic protocol, we will present in detail every stage of the neurological examination protocol.

I. Animal signalment

Regarding the fact that encephalitis with unknown origin is specific for small dog breeds, while viral encephalitis is more common in young, unvaccinated dogs - species, breed, age and gender are important elements for this stage of the examination.

For the 130 cases diagnosed with encephalitis, the results for the factors includes in the signalment of the animal are shown in Table 1.

Table 1. The distribution of cases by species, breed, age and gender

CRITERIA	NUMBER OF ANIMALS				
SPECIES	Canine 120			Feline 10	
DOG BREEDS	Small purebred dogs 54		Large purebred dogs 23	Mixed breed dogs 43	
AGE	Under 1 year 11	1 to 5 years 60	6 to 10 years 30	Above 10 years 19	
GENDER	Male 73			Female 47	

Considering the species, the number of examined dogs with forebrain lesions was significantly larger than the number of cats: 92.3% dogs and 7.7% cats.

It is widely known that the reported cases of cats with encephalitis are fewer than dog cases. Furthermore, in cats the etiology of encephalitis implies, most of the time, an infectious agent (Bradshaw et al., 2004; Georgescu et al., 2009; Singh et al., 2005).

The number of small purebred dogs was higher than large purebred dogs or mixed breed dogs: 45% small purebred dogs, 36% mixed breed

dog and 19% large purebred dogs, as is shown in Chart 1.

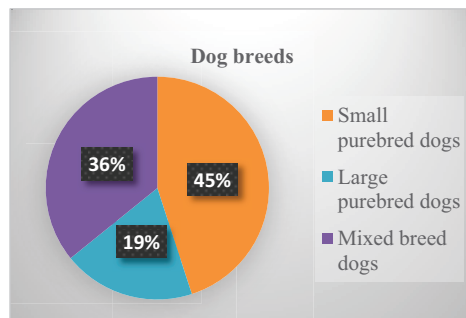


Chart 1. Distribution of dogs according to their breed

The breeds includes in small purebred dogs were: Bichon Maltese - 18 cases, Shih-Tzu - 9 cases, Chihuahua - 7 cases, Pug - 6 cases, French Bulldog - 6 cases, West Highland white terrier - 3 cases, Yorkshire Terrier - 2, Basset Hound, Beagle, Cocker Spaniel - 1 case of each.

The explication for the large number of small purebred dog affected is that they have a genetic predisposition for developing meningoencephalitis of unknown origin (Greer et al., 2010; Schrauwen et al., 2014).

According to the age, the juvenile dogs were more affected than older dogs (59.16% dogs of age 1-5 year old).

The distribution of cases according to the gender was: 60.83% males and 39.17% females.

II. History

The history of the animal included the group of signs that led the owner to the consultation. In addition, we used a template in order to obtain important details in a logical order, with a series of essential questions:

- If vaccination and deworming schedule was complete;
- The time when the animal was last normal and the progression of signs (improving, stabilizes, worsening);
- If there was an interaction with other animals before the onset of the disease;
- Is there was a history of other body systems conditions;
- If any medication was administered until the moment of examination;

- If there was a travel history in order to rule out vector-borne, parasitic or saprophytic exposure.

The most common elements of the history for the patients with encephalitis were: a sudden onset of disease, with progressive clinical signs (from days to weeks) and epileptic seizures (out of 130 patients, 48 patients had seizures – 36.92%).

III. Physical and neurological examination

Physical examination included inspection, palpation, auscultation, body temperature and the assessment of the respiratory movements, pulse, coat, skin and mucous membranes aspect, as it already have been described (Vlăgioiu & Tudor, 2012).

Physical examination before neurological examination was mandatory for every case, because it helped us to exclude a systemic disease that could have evolve with neurological signs.

Neurological examination included assessment of the: mental status and behaviour, posture, cranial nerves, proprioception, gait and other abnormal movements, spinal reflexes, panniculus and perianal reflex.

The most common neurological deficits present in patients with encephalitis were: a depressed/confused mental status, head turn ipsilateral to the forebrain lesion, head pressing, abnormal movements like circling in large circles, dromomania, and contralateral blindness with normal pupillary light reflex, cranial nerve abnormalities and proprioception deficits in contralateral limbs. In cases with diffuse or multifocal lesions, the neurological signs were unspecific and common for the affected regions of the brain (Figures 1 and 2).



Figure 1. A young dog with the head turn on the left side and depression. The PCR was positive for Distemper

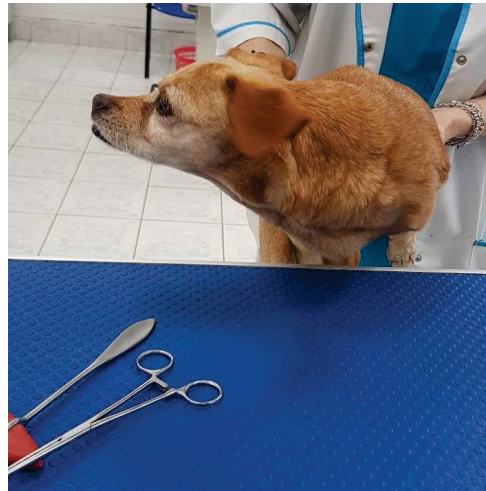


Figure 2. A dog with depression, head turn on the right side and lack of response at the proprioception tests

IV. Neurolocalisation of the disease

After the physical and neurological examination was completed, all the findings were correlated in order to localise the lesion in one of the four regions of the brain: forebrain, cerebellum, brain stem and vestibular apparatus (Figure 3) (Turbatu et al., 2018).

From the 209 cases included in the study, in 130 cases the lesion was localised in the forebrain, in 22 cases the localisation was in the vestibular apparatus, 8 cases had a cerebellar localisation and 3 cases a brain stem localisation. The rest of the patients - 46 were diagnosed with diseases that affect the peripheral nervous system and are not the subject of this study.

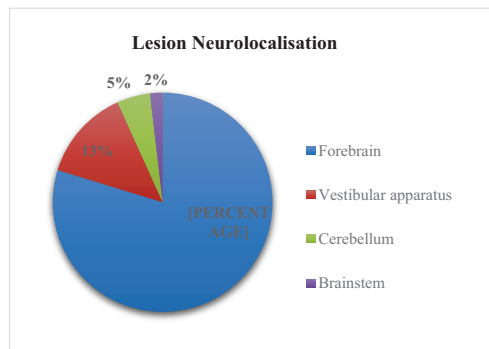


Figure 3. Distribution of cases according to the neuroanatomical localisation

V. Differential diagnosis and paraclinical investigations

For every patient, after the precise localisation of the lesion, a list of differential diagnoses has been taken into consideration using the acronym VITAMIND (Vascular, Inflammatory, Trauma, Anomaly, Metabolic, Idiopathic, Neoplasia and Degenerative).

The vascular pathology implied for the differential diagnosis the stroke and the brain hypoxia, but usually both have a sudden onset and specific clinical and neurological signs.

The inflammatory pathology was the main suspicion for cases with subacute-chronic and progressive onset, asymmetric or multifocal signs and often pain (vocalisations).

Trauma was revealed from the anamnesis and was characterised by a sudden onset, rarely progressive, with a specific localisation of the lesion. Often, acute injury of the brain was associated with oedema and fulminant symptoms (Fernoagă, Codreanu & Cornilă, 2013).

Anomalies are development disorders and are usually slow progressive. The main anomaly that could have been taken into consideration for the differential diagnosis list was hydrocephaly. However, hydrocephalus occurs early in life the animal and involves significant morphological changes.

For the metabolic aetiology, differential diagnosis implied disorders like hepatic encephalopathy, congenital portosystemic shunt, organic acidaemias or hypoglycaemia. (Fitzmaurice, 2010). In this case, the neurological signs were symmetric and there were multiple signs of a systemic involvement. The idiopathic differential list included specific diseases like Horner syndrome or idiopathic epilepsy. However, the idiopathic aetiology was suspected in cases in which no other underline cause of the illness could be found.

The neoplasia was always on the list because of the asymmetric, progressive evolution of the neurological sign. In order to rule out the neoplasia, we always perform the MRI.

The degenerative aetiology implied deposition diseases, which do not appear often in the brain. The clinical manifestation was always symmetric.

For our cases, after establishing the list of differential diagnoses, the next step was to

perform a series of paraclinical investigation in order to establish the correct diagnosis, and when was possible, the etiological diagnosis.

In all patients, we recommended: cardiologic and ophthalmologic examination, tests of the blood that included hematology, serum biochemistry and bile acids, thoracic/abdominal imaging, urine PCR for infectious diseases, MRI and cerebrospinal fluid analysis in order to confirm inflammation.

Due to the high financial costs these investigations involve, many times we had to choose to perform the ones that are the most sensitive and that offer a quick answer.

From the 130 cases with forebrain diseases, we confirm Distemper Virus (CDV) in 15 cases (11.53% from the total number of cases) using urine PCR (Saito et al., 2006).

The patients with Distemper were younger dog (less than one year old) with signs of acute encephalitis and myoclonus.

CONCLUSIONS

To establish the diagnosis of encephalitis, all stages of the diagnostic protocol should be strictly followed.

The number of cases with neurological signs diagnosed during the year 2018 had a significant percentage from the total number of cases (10.96%).

Considering the species, the number of examined dogs with forebrain lesions was significantly larger than the number of cats: 92.3% dogs and 7.7% cats

The number of small purebred dogs was higher than large purebred dogs or mixed breed dogs: 45% small purebred dogs, 36% mixed breed dog and 19% large purebred dogs

According to the age, the juvenile dogs were more affected than older dogs (59.16% affected dogs 1-5 year old).

The distribution of cases according to the gender was: 60.83% males and 39.17% females.

From the 130 cases with lesions localised in the forebrain (80%), Distemper Virus (CDV) was confirmed in 15 cases (11.53%) using PCR.

REFERENCES

Bradshaw, J.M., Pearson, G.R., & Gruffydd-Jones, T.J. (2004). A retrospective study of 286 cases of

- neurological disorders of the cat. *J Comp Pathology*, 131(2-3), 112-120. doi: 10.1016/j.jcpa.2004.01.010
- De Lahunta, A., Glass, E., & Kent, M. (2014). *Veterinary Neuroanatomy and Clinical Neurology, 4th Edition*. London: Elsevier Health Sciences
- Dewey, C.W., & da Costa, R.C. (2015). *Practical Guide to Canine and Feline Neurology, 3rd Edition*. New Jersey: Wiley-Blackwell
- Fernoagă, C., Codreanu M., Cornilă M. (2013). CEREBRAL EDEMA/OEDEMA. *Scientific Works. Series C. Veterinary Medicine*, Vol. 19, ISSUE 4.
- Fitzmaurice, S.N. (2010). *Small Animal Neurology*. London: Saunders ELSEVIER
- Georgescu, G., Tudor P., Tudor N., Grosu F., Ionescu A. (2009). A clinical case of toxoplasmic encephalitis in a cat. *Scientific Works. Series C. Veterinary Medicine*, LV (2), 222-225
- Greer, K.A., Wong, A.K., Liu, H., Famula, T.R., Pedersen, N.C., Ruhe, A.,... Neff, M.W. (2010). Necrotizing meningoencephalitis of Pug dogs associates with dog leukocyte antigen class II and resembles acute variant forms of multiple sclerosis. *Tissue Antigens*, 76(2), 110-118. doi: 10.1111/j.1399-0039.2010.01484
- Saito, T.B., Alfieri, A.A., Wosiacki, S.R., Negrão, F.J., Morais, H.S., & Alfieri, A.F. (2006). Detection of canine distemper virus by reverse transcriptase-polymerase chain reaction in the urine of dogs with clinical signs of distemper encephalitis. *Res Vet Sci.*, 80(1), 116-119. doi: 10.1016/j.rvsc.2005.03.002
- Schrauwen, I., Barber, R.M., Schatzberg, S.J., Siniard, A.L., Corneveaux, J.J., Porter, B.F.,... Huentelman, M.J. (2014). Identification of novel genetic risk loci in Maltese dogs with necrotizing meningoencephalitis and evidence of a shared genetic risk across toy dog breeds. *PLoS One*, 9(11), 1-7. doi:10.1371/journal.pone.0112755
- Singh, M., Foster, D.J., Child, G., & Lamb, W.A. (2005). Inflammatory cerebrospinal fluid analysis in cats: clinical diagnosis and outcome. *J Feline Med Surg.*, 7(2), 77-93. doi: 10.1016/j.jfms.2004.07.001
- Turbatu, R.M., Fernoagă, C., Tudor, N., Vlăgioiu, C. (2018). A review of neurological examination-differential diagnosis for intracranial diseases in cats and dogs. *Scientific Works. Series C. Veterinary Medicine*. Vol. LXIV (2), 88-94
- Vlăgioiu, C., & Tudos, N. (2012). *Semiologie veterinară și tehnici de examinare*. Craiova: Sitech.

TREATMENT OF THE EXUBERANT GRANULATION TISSUE IN HORSE USING ELASTIC LIGATURE: CASE REPORT

**Cristian ZAHA, Raluca DASCALU, Larisa SCHUSZLER, Bogdan SICOE,
Daniel BUMB, Cornel IGNA**

Banat's University of Agricultural Sciences and Veterinary Medicine
"King Michael I of Romania" from Timisoara, Faculty of Veterinary Medicine,
119 Calea Aradului, 300645, Timisoara, Romania

Corresponding author email: ignacornel@gmail.com

Abstract

Wounds that occur on the horse distal limb may evolve with the appearance of an exuberant granulation tissue that causes discomfort both to the animal and to the owner. Granulation tissue usually appears in the healing phase, but it evolves in excess due to the area prone to infection, with low blood supply, difficult to suture and in continuous movement. This case report describes the treatment of an exuberant granulation tissue in a mixed Romanian horse breed by histiotripsy using an elastic ligature. The success of the treatment consisted in gradual ablation of exuberant tissue given by the suppression of blood circulation, limited the local infection and subsequent stimulation of scarring. During the treatment, episodes of mild lameness and localized edema may occur, and in case of unexpected elimination of the exuberant mass a massive haemorrhage will occur.

Key words: exuberant granulation tissue, healing phase, histiotripsy.

INTRODUCTION

In horses, the frequent causes of appearance of the exuberant granulation tissue - EGT is represented by the unsutured wound and inappropriate local treatment. Large-breed horses are at higher risk than ponies or smaller breeds (Varasano et al., 2018; Bertone, 1989). Wounds localized at the trunk region have less complications and faster heal rate than wounds located at the distal part of the limb.

The anatomical characteristics of the distal limb (absence of the panniculus carnosus muscle) and an inappropriate hygiene with development of a local infection are some of the most common and frustrating complications that disturb the healing and develop a fibroproliferative disorder known as Exuberant Granulation Tissue (EGT) (Naldaiz-Gastesi et al, 2018).

The clinical presentation of EGT is similar to that of human keloid and these conditions have a number of pathophysiologic and histopathologic aspects in common.

In particular, chronic inflammation, aberrant angiogenesis, and defect of wound epithelialisation and contraction are observed (Theoret et al., 2013)

In clinical practice, suture of the skin wound in area as distal limb may encounter difficulties because of the factors that include loss of tissue, excessive skin tension, old wounds. In this case, when the wound can not be sutured to have an evolution for primary healing, the wound will take the direction for secondary intention healing with the development of the granulation tissue (Theoret, 2009). In secondary intention healing, the inflammatory response becomes chronic and alterations appear in cytokine profiles that lead to high levels of pro-fibrotic mediators and reduce levels of cells for differentiation of fibroblast into the myofibroblast necessary for wound contraction. Fibroblasts can contribute to chronic inflammation, and reciprocally, inflammatory cytokines promotes fibroblast to myofibroblast transition, facilitating fibrosis (Hacket, 2011).

Because of the vascular disruption and high oxygen consumption by metabolically active cells, the area of the early wound is depleted of oxygen and become hypoxic. Hypoxia can induce cytokine and growth factor production from macrophages, keratinocytes, and fibroblasts (Celeste et al., 2011; Bishop, 2008). Also, in the absence of effective

decontamination, the inflammation may be prolonged. Both bacteria and endotoxins can lead to the prolonged elevation of pro-inflammatory cytokines such as interleukin-1 (IL-1) and TNF- α and elongate the inflammatory phase (Guo & DiPietro, 2010; Hacket, 2011.). If this continues, the wound may enter a chronic state and fail to heal. The chronic inflammatory response activates macrophages and lymphocytes which lead to the release of growth factors and cytokines which intensifies collagen synthesis. EGT is more likely to develop in wounds with foreign material, chronic infection or chronic inflammation (Hacket, 2011; Guo & DiPietro, 2010, Theoret et al., 2016).

Once developed and protruding over the wound margins, the EGT affect the epithelialisation and wound contraction, and predisposes the wound to infection and more traumas. Some theories say that the best current therapy remains surgical excision of the protruding tissue opposite to topical applications of corticosteroids and local administer of caustic agents are not recommended and must be avoided as much as possible in order not to maintain a chronic inflammation (Stastak et al., 2008; Hacket, 2011).

The administration of the steroid anti-inflammatory drugs are known to inhibit wound restoring because of anti-inflammatory effects and suppression of cellular wound responses, including fibroblast proliferation and reduced wound contraction. (Franz et al., 2007)

The method of treatment that we have chosen consists in applying an elastic ligature constriction around the EGT, at its base to the limit of the skin in order to stop the blood circulation and following this necrosis of the excess tissue.

MATERIALS AND METHODS

The Surgery Clinic of the Faculty of Veterinary Medicine from Timișoara was requested for an examination of a mixed Romania horse breed mare with age of 5 years old. The horse belonged to a farm located in another county. Following the trip to the farm, at clinical examination, the horse presented an exuberant mass localized on the medial part of the limb

dorsal to the fetlock. The owner described that 6 months ago, the animals cut itself into a metal wire and did not benefit from a medical consult and was treated with antibiotic spray only.

The physiological constants indicate a normothermic animal (37.6⁰C), heart rate of 38 bpm, respiratory rate of 16 breaths/minute. The animal presents a discomfort while walking, which occurs after touching the formation with the other limb. Besides this, the mare was in good shape, alert and responsive.

At the first examination, the mass had the size of 15x20 cm and the prominent mass had 10 cm, pus and swelling of the tissue were observed around the base of the mass (Figure 1). At the touch there was no pain.



Figure 1. First examen of the Exuberant granulation tissue - Dorso-medial to the fetlock

The animal was restrained using a combination of chemical solution and physical method. The chemical restrain was obtain after administering xylazine (0.5 mg/kg i.v.) and for physical restrain two ropes were applied individually on the pastern area and then was knotted together over the withers. Local anaesthesia was accomplished by subcutaneous infiltration of 10 ml of 2% lidocaine around the mass.

With the animal restrained in patrupodal position, a local antiseptic such betadine was applied at the base of the exuberant tissue and on the surrounding skin. An elastic material was applied around the base of the tissue and in

intimate contact with the skin. The elastic material surrounded the exuberant tissue once and after that was tightened up as closely as possible (Figure 2).

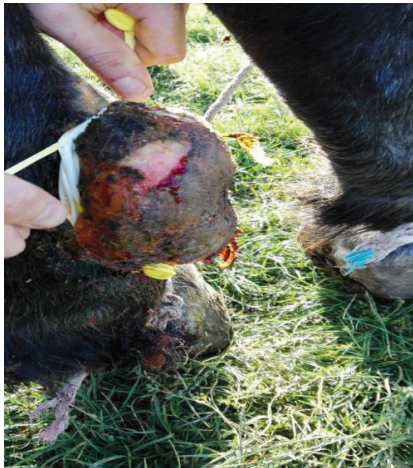

Figure 2. Applying the elastic constriction ligature

After this procedure, the owner would apply a local antiseptic daily. This procedure was made on 27.10.2017. Until the next visit the owner did not report that the animal manifested any pain or local bleeding.

On the second visit, the procedure was repeated, and within 2 weeks after this application, the formation was eliminated as a result of crushing and vasoconstriction. After the mass of tissue was removed a significant haemorrhage occurred which was stopped by thermal cauterization using a metallic object which was initially heated and after that a bandage was applied. The remaining tissue did not exceed the margins of the wound, the colour was pink and red and bled a lot when it was touched. The indication for the owner was to change the bandage at 2-days interval for a week and then let the wound uncovered.

The following weeks of treatment consisted in applying a local antiseptic, and the wound edges were buffered with a mixture of Herba-sol solution and Epitelin unguent.

On the third visit, on 16.04.2018 the presence of a scarring area beginning at the edges of the initial wound margins and a new exuberant tissue centrally positioned was observed. The presence of the exuberant tissue Figure 3 that had the following size 5x5 cm, required application of a new elastic ligature.

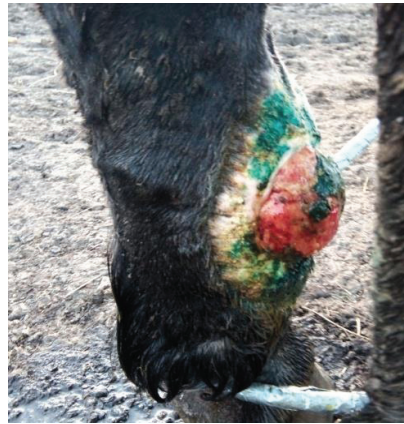

Figure 3. Third examen - center - presence of a new exuberant granulation tissue

This time the formation fell after 3 days and the haemorrhage was minimal and was stopped after applying a compressive bandage. The indication for the owner consisted in changing the bandage at 2-days interval for a week and then let the wound uncovered. The recommendations consisted in applying a local antiseptic and Herba-sol solution and Epidermin unguent over the defect. The defect has healed within 6 months with scar tissue development (Figure 4).

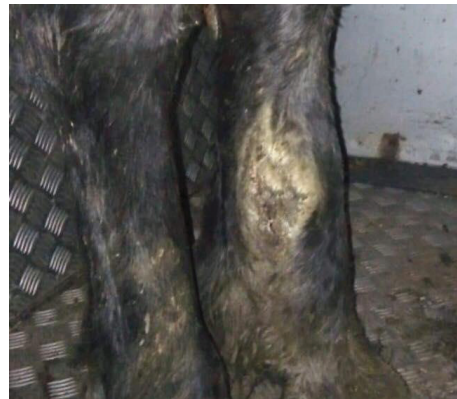

Figure 4. Cured plaque (only scar tissue)

During the treatment, the mare was kept in a separate box with dry bedding from straw.

RESULTS AND DISCUSSIONS

The elastic ligature constriction method has the effect of stopping blood circulation and mechanical crushing of the tissue.

After the exuberant granulation tissue was eliminated, the treatment consisted in stimulation of wound margins contraction and scar tissue formation. It also aimed the preventing of local infection and keeping the animal in a dry environment.

During the secondary intention healing the appearance of exuberant granulation tissue in the centre of the defect was noticed and a scar tissue developed at the periphery. During the healing phase, there was no local infection.

A major complication occurred following the detachment of the formation and was resolved by thermal cauterization with a metallic object which was initially heated.

Within 6 months of secondary wound treatment scar tissue was developed the entire surface.

There exist a variety of methods of treatment for exuberant granulation tissue.

For the treatment of the skin tumours, since antiquity the application of a ligature that surrounds the formation has been used and in time it was known that they would be eliminated (Papavramidou et al., 2010).

A method of treatment for the exuberant granulation tissue consisted in intralesional injection of 4% formaldehyde and after 3 administrations the tissue had decreased in dimension and a crust has appeared on the surface (Varasano et al., 2018).

Another method consisted in intralesional injection of corticosteroid and had suppressive effects on the inflammatory process in the wound and secondarily from reduced collagen and glycosaminoglycan synthesis and inhibition of the fibroblast (Gauglitz, 2013). Also, the use of a topical application of a corticosteroid can have a certain effect against relapse (Theoret, 2016).

Surgical resection is preferred by some authors because it is easy to perform, provides tissue for histologic exam, and preserves the skin margin (Bertone, 1989).

After the mass was removed, to prevent the formation of a new exuberant tissue, the wounds have to be left open to the air and eliminate the all the irritant mechanical factor (Bertone, 1989; Hacket, 2011).

A silicone gel wound dressing it is applied on the wound surface and gradually it will decrease oxygen tension in the tissues until the point of anoxia, when fibroblasts can no longer

function and undergo apoptosis (Hacket, 2011; Celeste et al., 2011).

A complex method of treatment to increase the healing consists in using the skin graft (Bristol, 2005). Free skin grafts are categorized by thickness and type. Full-thickness grafts include epidermis and the entire dermis (Toth et al., 2010). Split-thickness grafts include epidermis and a portion of dermis. Full- and split-thickness grafts can be either sheet grafts or island grafts. Island graft techniques include punch, pinch, tunnel and modified meek grafts. The advantage of island grafts is that the failure or loss of only graft does not affect other grafts in the wound (Schumacher & Hanselka, 1989). The limit of the treatment was due to the impossibility of transporting the horse to the clinic.

CONCLUSIONS

The elastic ligature constriction represents a solution for removal the exuberant granulation tissue.

Secondary intention healing was successful after removing the excessive tissue and applying local treatment.

ACKNOWLEDGEMENTS

This study was realised using the support and infrastructure project “*Dezvoltarea infrastructurii de cercetare, educație și servicii în domeniile medicinei veterinare și tehnologiilor inovative pentru RO 05*”, cod SMIS-CSNR 2669.

REFERENCES

- Bertone, Al. (1989). Management of exuberant granulation tissue. *Vet Clin North Am Equine Pract.* 1989 Dec;5(3):551-62.
- Bishop, A. (2008). Role of oxygen in wound healing. *J Wound Care.* 17(9):399-402.
- Bristol, DG. (2005). Skin grafts and skin flaps in the horse. *Vet Clin North Am Equine Pract.* 21(1):125-44.
- Celeste, C. J., Deschene, K., Riley, C. B., Theoret, C. (2011). Regional differences in wound oxygenation during normal healing in an equine model of cutaneous fibroproliferative disorder. *Wound Repair Regen.* 19(1):89-97.
- Franz, M. G., Steed, D. L., Robson, M. C. (2007). Optimizing healing of the acute wound by minimizing complications. *Curr Probl Surg.* 44(11):691-763.

- Gauglitz, G. (2013). Management of keloids and hypertrophic scars: current and emerging options. *Clin Cosmet Investig Dermatol.* 6: 103–114.
- Guo, S., DiPietro, L. A. (2010). Factors affecting wound healing. *J Dent Res*, 89(3): 219–229.
- Hackett, R. (2011). How to prevent and treat exuberant granulation tissue. Wound & Orthopedic management. *AAEP Proceedings*. Vol. 57:367-373.
- Naldaiz-Gastesi, N., Bahri, O., Lopez-de-Munain, A., Mccullagh, K. (2018). The panniculus carnosus muscle: an evolutionary enigma at the intersection of distinct research fields. *Journal of Anatomy.* 233(2):1-8.
- Papavramidou, N., Papavramidis, T., Demetriou, T. (2010). Ancient Greek and Greco–Roman Methods in Modern Surgical Treatment of Cancer. *Ann Surg Oncol.* 17(3): 665–667.
- Schumacher, J., Hanselka, D. V. (1989). Skin grafting of the horse. *Vet Clin North Am Equine Pract.* 1989 Dec;5(3):591-614.
- Theoret, C. (2009). Tissue Engineering in Wound Repair: The three “R”s—Repair, Replace, Regenerate. *Proceedings of the European Society for Veterinary Orthopedics and Traumatology.* 38(8):905-913.
- Theoret, C., Wilmink, J. (2016). Exuberant granulation tissue. *Equine Wound Management.* Third Edition. (pp.369-384) Philadelphia: Saunders Elsevier.
- Theoret, C. L., Olutoye O. O., Parnell, L. K., Hicks, J. (2013). Equine exuberant granulation tissue and human keloids: a comparative histopathologic study. *Vet Surg.* 42(7):783-789.
- Toth, F., Schumacher, J., Castro, F., Perkins, J. (2010). Full-thickness skin grafting to cover equine wounds caused by laceration or tumor resection. *Vet Surg.* 39(6):708-14.
- Varasano, V., Marruchella, G., Petrizzi, L. (2018). Exuberant granulation tissue in a horse: successful treatment by the intralesional injection of 4% formaldehyde solution. *Veterinaria Italiana.* 54 (2): 155-159.

ANIMAL PRODUCTION,
PUBLIC HEALTH
AND FOOD QUALITY
CONTROL

FUNCTIONAL SET UP STAGES OF AQUAPONIC EXPERIMENTAL MODEL

Elena Camelia GAVRILĂ¹, Neculai PATRICHE², Marian BOGOESCU³,
Dorin SORA¹, Mădălina DOLTU¹, Maria CRIVINEANU⁴

¹ Institute of Research and Development for Processing and Marketing of Horticultural Products - Horting Bucharest, Romania

² Institute of Research and Development for Aquatic Ecology, Fishing and Aquaculture Galați

³ Academy of Agricultural and Forest Sciences "Gheorghe Ionescu-Șișești",
IRDPMHP-HORTING, Bucharest, Romania

⁴ University of Agronomic Sciences and Veterinary Medicine of Bucharest, Faculty of Veterinary Medicine, Bucharest, Romania

Corresponding author email: dragomirelenacamelia@gmail.com

Abstract

The aquaponic sistem is giving by concomitant application of hydroponia (plant culture without soil) and aquaculture (culture of fish). To set up a aquaponic system more stages are necessary. The environment for aquaponic sistem should be attently chosen to avoid pollution factors. Taking in consideration cold regime in our country aquaponic sistem was settled down inside of micro greenhouse belongs to Institute of Research and Development for Processing and Marketing of Horticultural Products Bucharest. Fishponds were building using 0.8 mm OSB panel covered with polyethylene wrap. Water physico- chemical analyzes was performed as following: temperature, oxygen dissolved (DO), nitrate, nitrite, ammonia, calcium, magnesium and phosphorus. The studies performed showed the maintenance of aquaponic sistem

Key words: fish, lettuce, aquaponia, hydroponia, RAS.

INTRODUCTION

Aquaponia is a bio-integrated system whose link RAS (culture of fish) by hydroponia (plant culture without soil). (James E. et al., 2004), (Masser P.M., 2006). Aquaponia combine both systems (RAS and hydroponia) in a close recirculation system (Rakocy J.E. et al., 2006). To utilize fish manure for plant culture is an ancient practice. The most well known examples are from Central America (Aztecs 1150-1350 BC), South Asia rice culture together with fishes 1500 years ago. (Turcios A.E. et al., 2014; Coche A.G., 1967).

At the beginning, the studies were conducted to use fish manure for plant culture. Nowadays, commercial aquaponic systems should be develop in controlled spaces or natural favorable climate using high tech equipment. To set up an aquaponic system free emissions and pollution environment should be chose. (Resh, H.M., 1995; Adler P.R., 2000).

Aquaponia can be useful indifferent of country economic development, with large population and week agricultural resources (Renee E.,

2011, Mchunu et al., 2018) beeing valuable by offering good quality animal and vegetal proteine. In rural or city regions (Liang & Chien, 2013).

Fish meat, besides other animal meat, represent an important human food category (Petcu C.D., 2013). Aquaponic fish roe must respect specific food demand parameters allled in authorised conditions (Petcu et al., 2008). Fish manure represent an ecological plants food, plants which are filtering fish water environment (Figure 1).

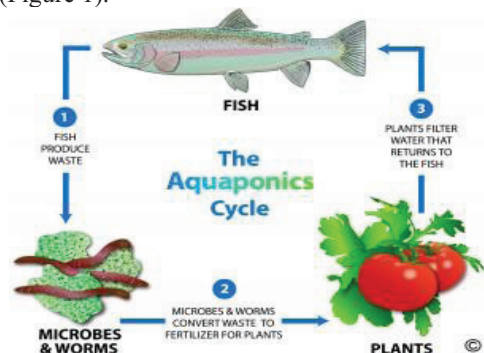


Figure 1. Aquaponics Cycle
(www.theaquaponicsource.com)

MATERIALS AND METHODS

The aquaponic system was settled down inside of micro greenhouse belongs to Institute of Research and Development for Processing and Marketing of Horticultural Products Bucharest using three plants callusing tunnels Figure 2 and 3. Two of them were re - built special for plants growing (*Lactuca sativa*) each one being 7.4 x 1.8 x 0.3 M, and the third one for fishes 7.4 x 1.8 x 0.4 M was divided in eight equal tanks. Fish tanks were populated with 140 pieces of *Cyprinus carpio* 200 g, body weight average (Figures 4 and 5).



Figure 2. Aquaponic system carps tanks



Figure 3. Aquaponic system carps tanks



Figure 4. *Cyprinus carpio* 200g, body weight average



Figure 5. *Cyprinus carpio* 200 g, body weight average

To control aquaponic system functioning, Water physico- chemical analyzes was performed in two critical points fish tanks feeding and hydroponia water exhausting.

To increase filtration plants system was continuously loading. Water physico-chemical parameters were assayed at the Institute of Research and Development for Processing and Marketing of Horticultural Products Bucharest (temperature, DO, nitrate, nitrite, ammonia, calcium, magnesium and phosphorus).

D.O., pH, temperature were determined by AZ 86031 multiparameter device (Figure 6).



Figure 6. AZ 86031 multiparameter device

Calcium, magnesium and phosphorus were determined by Photometer HI 83225 device (Figure 7).



Figure 7. Photometer HI 83225 device

Nitrate, nitrite and ammonia were determined by LAMBDA 25, Perkin Elmer, molecular absorption device (Figure 8).




Figure 8. LAMBDA™ 25/35 Series UV/Vis Spectrophotometers, PerkinElmer

RESULTS AND DISCUSSIONS

To the aquaponia experiments *Lactuca sativa* was chosen being a tested plant with a good yield and good demand on the market. *Lactuca sativa* also is resistant during the cold season and consumes more ammonia.

The *Lactuca sativa* necessary for the system were prepared 20 days before being populated in the experimental system (Figure 9).



Figure 9. *Lactuca sativa*, 20 days before being populated in experimental system

Lettuce was populated on a 10 cm water level in containers. Population was started with 3 pieces/container, in final being 8 pieces/container (Figures 10 and 11).



Figure 10. *Lactuca sativa* in experimental system



Figure 11. *Lactuca sativa* in experimental system

To increase DO in water a special plastic separator was installed to avoid growth disturbance of lettuce (Figure 12).



Figure 12. Water a special plastic separator

Aeration system Hailea HAP/120 was installed too (Figure 13).



Figure 13. Aeration system Hailea HAP/120

Carp (*Cyprinus carpio*) 140 pieces, 200 g, body weight average were populated after three days of running system. Carps were provided from research farm of Institute of Research and Development for Aquatic Ecology, Fishing and Aquaculture Galați.

Carp (*Cyprinus carpio*) is a very resistant fish species well known to be growth and also very popular on the national market.

During December-February 2019 water physico-chemical analyzes was performed, monitoring fish population adaptation to environment condition by increasing lettuce plants pieces.

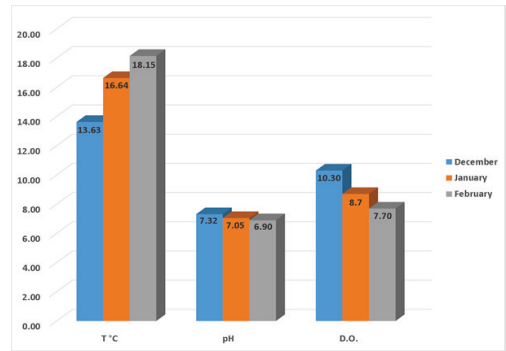


Figure 14. Temperature, pH, and DO values in 1-4 Tanks, Dec-Feb 2019

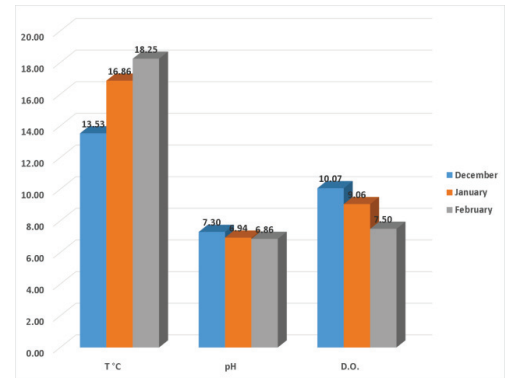


Figure 15. Temperature, pH, and DO values in 5- 8 Tanks, Dec-Feb 2019

From Figure 14 and Figure 15, it can be observed a constant pH value, an increasing water temperature and a decreasing value of DO.

To adjust water parameters in optimum value, micro greenhouse temperature was adjust too.

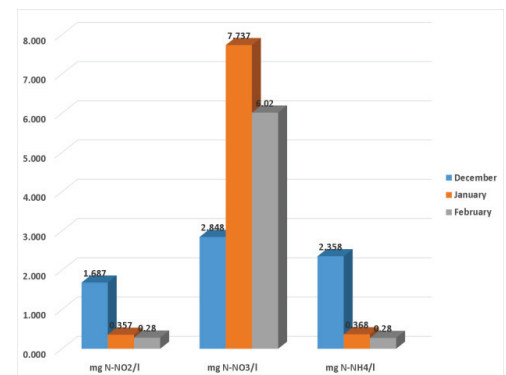


Figure 16. Nitrite and nitrate values in 1-4 Tanks, Dec-Feb 2019

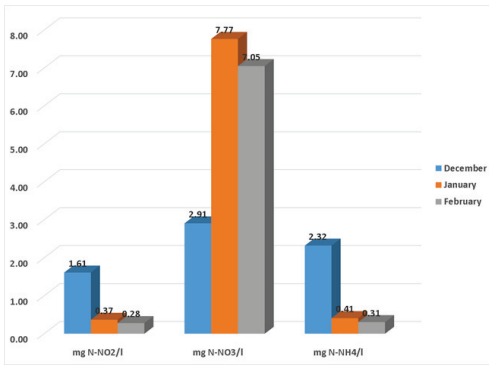


Figure 17. Nitrite and nitrate values in 5-8 Tanks, Dec-Feb 2019

During analyzed period nitrate values exceeded the maximum in January and February and nitrite values exceeded the maximum in December and January all do to fish feeding with to large quantity of food and water temperature value increasing (Figures 16, 17).

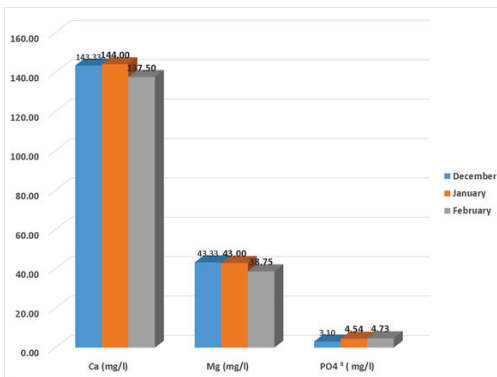


Figure 18. Ca²⁺, Mg²⁺, and PO₄ values in 1-4 Tanks, Dec-Feb 2019

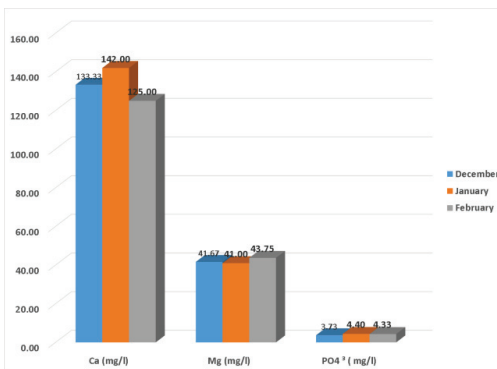


Figure 19. Ca²⁺, Mg²⁺, and PO₄ values in 5-8 Tanks, Dec-Feb 2019

During all studied period only PO₄ had increased values. All increased water physico-chemical parameters do not had negative influence on fish population which registered a good grow rate (Figures 18, 19).

CONCLUSIONS

Aquaponia represents an important technical solution for obtaining in the same time high quality animal and vegetal food products in controlled systems.

The monitoring of water physico-chemical parameters is a very important measure to be performed in aquaponic systems.

Both cultures, carp and lettuce, seem to be propitious with good results in aquaponic systems.

The experimental aquaponic system was built in low inputs energy and only controlled food ratio for fishes show as it efficiency.

REFERENCES

- Adler P.R., Harper J.K., Wade E.M., Takeda F., and Summerfelt S. T. (2000). Economic Analysis of an Aquaponic System for the Integrated Production of Rainbow Trout and Plants, *International journal of recirculating aquaculture*.
- Coche, A.G. (1967). Fish culture in rice fields a world-wide synthesis. *Hydrobiologia*, 30, 1–44.
- James E. Rakocy, R. Charlie Shultz, Donald S. Bailey and Eric S. Thoman (2004). Aquaponic Production of Tilapia and Basil: Comparing a Batch and Staggered Cropping System, *Agricultural Experiment Station University of the Virgin Islands RR 2, Box 10,000, Kingshill, VI 00850, USA*.
- Liang, J.Y., Chien, Y.H. (2013). Effects of feeding frequency and photoperiod on water quality and crop production in a tilapia-water spinach raft aquaponics system. *Int. Biodeterior. Biodegrad.* 85, 693–700. <https://doi.org/10.1016/j.ibiod.2013.03.029>.
- Masser P. Michael. (2006). Recirculating aquaculture tank production systems: Aquaponics-Integrating fish and plant culture, <https://www.researchgate.net/publication/284496499>.
- Mchunu, N., Odindo, A., Muchaonyerwa, P. (2018). The effects of urine and urine-separated plant nutrient sources on growth and dry matter production of perennial ryegrass (*Lolium perenne* L). *Agric. Water Manage.* 207, 37–43. <https://doi.org/10.1016/j.agwat.2018.05.023>.
- Petcu Carmen, C. Savu, Iuliana Neagu, Dana Tăpăloagă, Cristina Manta (2008). Features of some preliminary programmes in a fish processins unit, Simpozion internațional “Progrese și Perspective în Medicina Veterinară”, Universitatea de Științe Agricole și

- Medicină Veterinară "Ion Ionescu de la Brad", Vol. 51(10)- II, pag. 872-878 - Iași , ISSN 1454-7406.
- Petcu Carmen (2013). *Obținerea, ambalarea și controlul sanitar veterinar al peștelui și al produselor din pește*, Editura Granada. București, ISBN 978-606-8254-36-4.
- Rakocy, J.E.; Masser, M.P.; Losordo, T.M. (2006). *Recirculating Aquaculture Tank Production Systems: Aquaponics - Integrating Fish and Plant Culture*; Southern Regional Aquaculture Center: Stoneville, MS, USA; pp. 1–16.
- Renee Elisha, Spirn Anne Whiston (2011). *Aquaponics: community and economic development*, Massachusetts Institute of Technology.
- Resh, H.M. (1995). *Hydroponic food production*. Woodbridge Press Publishing Company, Santa Barbara, California.
- Turcios, A.E.; Papenbrock, J. (2014). Sustainable Treatment of Aquaculture Effluents-What Can We Learn from the Past for the Future? *Sustainability* , 6, 836–856., www.theaquaponicsource.com

OBSERVATIONS ON GROWTH PERFORMANCES OF RAINBOW CONSUMPTION TROUT

Andrei MARMANDIU¹, Andreea TRONARU¹, Ion CUSTURĂ²,
Ion RĂDUCUȚĂ², Ileana PĂUNESCU¹

¹University of Agronomic Sciences and Veterinary Medicine of Bucharest, Faculty of Veterinary Medicine, 105 Splaiul Independenței, District 5, 050097, Bucharest, Romania

²Faculty of Animal Sciences Bucharest, 59 Mărăști Blvd, District 1, 011464, Bucharest, Romania

Corresponding author email: marmandiua@yahoo.com

Abstract

In the present study, the productive performance of the rainbow trout for consumption (one year and a summer trout – P₁₊, two-year trout – P₂, two-year and one summer trout – P₂₊) was analyzed, grew up in a fishing unit in south-eastern part of country. At the control fishing made bi-monthly, by weighing 100 fish of each pond and age category, the body weight was assessed, and based on it, the total and daily average gain in growth was established. Also, by sampling, the main body measurements were made and the body indices were calculated for the two summer trout. The primary somatometric data were processed statistically. The one year and a summer trout (P₁₊) registered a good growth dynamic, resulting in a total average gain in growth of 150 g / fish starting from pond population to the autumn inventory and an average daily gain of 0.83 g / fish. In spring-autumn growth, body weight grew by about 4.33 times (from 45 g / fish in July to 195 g / fish on autumn stock). In the October-March growth period, the two-year rainbow trout (P₂) recorded a total average gain of 138 g / fish and a daily average gain of 0.92 g / fish, and the two-year and one summer trout (P₂₊) achieved a total average gain of 102 g / fish and a daily average gain of 0.85 g / fish. The economicity of body mass accumulation was good (specific consumption of 1.18-1.20 kg of combined fodder). The main somatometric characteristics of two-year rainbow trout (P₂), demonstrates the proper body development and correctness of the body conformation of this age group, and the low variability coefficients (below 10%) highlight the high homogeneity of trout in pond. The two-summer rainbow trout showed optimal body indices values: fattening index = 1.67%, profile index = 3.61, quality index = 1.63, thickness index = 20.07%, carnosity index = 18.81%.

Key words: rainbow trout, body weight, growth rate, body dimensions, body indices.

INTRODUCTION

Salmoniculture occupies an important place in fish farming, position which in Romania is justified both on the environmental conditions favorable for this physiological requirements of salmonids fish (especially trout) and the physico-chemical and organoleptic special properties posed by the meat of the salmonids obtained by converting with maximum efficiency the poor quality food (animal and vegetable flour, slaughterhouse waste etc.).

In fish farms in our country, rainbow trout (*Oncorhynchus mykiss*) is of increasing importance due to its valuable biological and productive characteristics. The rainbow trout displays great adaptability, being less prudent to environmental conditions, tolerating lower oxygen content in water, wide variations in temperature and water transparency. It also shows increased resistance to diseases, intense

growth rate and high efficiency of natural biomass and additional food capitalization (Bud et al., 2007).

The growth of rainbow trout in intensive system, enables strictly monitoring of the physico-chemical parameters of the water from the pools, of the feeding and consumption of food, assessment the behavior and general condition (body condition) of the fish and observing signs of illness, aspects leading to increased productivity and profit in a trout farm.

MATERIALS AND METHODS

Research done on a salmonids farm in the south-eastern part of the country aimed the assessment of the productive performances of the rainbow trout fitting for consumption (one year and a summer trout – P₁₊, two-year trout – P₂, two-year and one summer trout – P₂₊).

During the growth of the age groups mentioned above, twice a month was conducted control fishing, to monitor the state of maintenance (body condition) and the health condition of the fish and for establishing the rhythm of growth by weighing each 100 fish of each basin and age group. Also, daily observations were made about the behavior of the fish, the appetite expressed during feeding and the appearance of illness symptoms, which affects the growth process and causes number and economic losses.

Due to the fact that in the farm analyzed the greatest benefits are obtained by selling trout two years old (P₂), on 50 fish taken from different places in the water pools, gravimetric and corporal measurements were made: body length - total, standard, regulatory, commercial; the maximum and minimum height of the body; the large and small perimeter of the body; the length of the caudal peduncle (Lustun, 1985; Bud & Vlădău, 2004; Turliu, 2008). The obtained values were statistically processed (average was calculated, standard error of the average, variance, standard deviation, coefficient of variability) (Tacu, 1968; Sandu, 1995; Neagu, 2005), and the results were interpreted as absolute values and on their basis were calculated body indices (fattening index, profile index, quality index, thickness index, carnosity index) (Bud & Vlădău, 2004).

RESULTS AND DISCUSSION

The **body weight** parameter, determined by control weights, recorded the following dynamics in the analyzed age categories:

- the rainbow trout of one year and one summer (P₁₊) showed at the beginning of the growth period the **average weight** of 45 g / fish, then in June it doubled its body mass and in the period July-September it registered a intensive rhythm of growth, reaching the weight of 157 g / fish. This intensive growth dynamics in the warm season is because of the water that reaches temperatures of 14-18°C values corresponding to thermal optimum feeding favoring the maximum intensity of the trout. In the harvest inventory in autumn, the average weight per fish reached 195 grams (Table 1) and the average length of 24 cm.

- the rainbow trout two years old (P₂) started the growing and fattening period in order to be ready for marketing with the **average weight** of 195 g / fish, and in the spring of 2014 reached the average weight of 333 g per fish (Table 1) and average length of 30 cm.

- the rainbow trout two years and a summer old (P₂₊) showed a very good productive performance, so that, in July 2014, has shown an average weight of 435 grams/fish (Table 1) and average length of 36 cm *versus* 333 g when the basin were populated.

Table 1. Dynamics weight of rainbow trout consumption

Age category	Weight at populating (g)	Control date and body weight (g)					Weight of harvesting (g)
		15/4/13	17/5/13	10/6/13	15/7/13	12/8/13	
P ₁₊	45	56	73	92	120	157	195
		15/10/13	10/11/13	15/12/13	09/1/14	15/2/14	
P ₂	195	240	274	289	300	310	333
		10/4/14	15/5/14	10/6/14	10/7/14	-	-
P ₂₊	333	360	382	420	435	-	435

The obtained results denote the efficiency of the rainbow trout breeding technology in the analyzed unit, with a clear relationship between the quality and biological value of the fish material and the conditions ensured throughout the evolution of the trout.

In order to achieve this good body weight at the end of the growing period of the rainbow trout intended for consumption, the essential

element, apart from maintaining the physico-chemical parameters of the water within the normal limits, is the feed system, since the food administered in optimal and rigorous quantities, but which are also qualitatively appropriate, by observing the percentage content of nutrients necessary for the correct functioning of the body, leads to the achievement of large body weights.

In good growth conditions (adequate feeding, optimal physico-chemical parameters of water), in some trout farms in Romania, the rainbow trout recorded at the age of 1.5 years the average weight of 310 g and at 2 years 435 g (Decei, 2001), values superior to those obtained in this study. Păsărin (2007) shows that the rainbow trout exhibits an intense growth rate and at the age of two years it reaches a weight of 250 g, a lower result the values currently set in this work.

Based on the initial weight of the biological material when first populating the pools and the final weight recorded at the end of the growth period, the growth rate of the rainbow trout was determined, namely: **the overall average growth rate** (final weight – initial weight) and **average daily gain** [(final weight - initial weight)/growth period]. The intensity of growth is of special importance, since it influences the growth duration of the trout and, implicitly, the spending over the entire evolutionary cycle of fish. The exploitation of trout aims at maximizing the accumulation of body mass, so that their valorization can be realized as early as possible, at a weight corresponding to the biological potential.

During the period of growth of the trout there were recorded average body weights values set in each controls fishing to highlight the dynamic of their growth (Table 1). The results presented in Table 1 show that all three categories of rainbow trout showed a very good growth rate, as follows:

- the rainbow trout one year and one summer old (P_{1+}) showed **the total average growth rate** of 150 g / fish since the pool population (July) to the autumn inventory and **the average daily increase** of 0.83 g / fish was achieved.

During the growth period (6 months), the trout increased their body mass of about 4.33 times, and the highest increase was found in the July-September period when the temperature of the water in the tanks has reached optimal values, corresponding to the maximum feeding intensity.

- the rainbow trout two years old (P_2) during the growing season from October to March, recorded **the total average increase** of 138 g /fish (the body weight increased about 1.71 times) and **average daily gain** of 0.92 g / fish. The better growth rhythm (+0.09 g / fish *versus*

P_1), is due to the aging of the biological material.

- the rainbow trout two years and a summer old (P_{2+}) showed **the total average increase** of 102 g / fish, and **the average daily gain** of 0.85 g / fish. At the end of the growth period, the body mass increased about 1.31 times the original weight.

The consumption indigenous trout a year and a summer old (P_{1+}) reaches the mean body weights of 40-80 g and at two years and a summer old (P_{2+}), which is commonly sold, the average weight reached 175-180 g (Păsărin, 2007).

The results of the study demonstrate that body weight and growth rate of the consumption rainbow trout it at different ages, are far superior values for indigenous trout, which is why, rainbow trout is the most widespread salmonid in trout in our country, which at the same time exhibits greater resistance to diseases, tolerance towards the heavier conditions of growth, prolificacy and high precocity.

The body weight and the good growth rate of the trout recorded in the analyzed unit were due to rational feeding with OPTILINE grain combined feed, the 2P recipe for one year and one summer old trout and 3P recipe to grow and fatten the trout for two years and for the two years and one summer one, the last one representing the last stage of the production cycle. Feed was administered manually, in equal portions of 3 times per day, at the water surface, in a daily amount of 1-2% of the total weight of P_{1+} trout and 1.0-1.6% of the total weight of trout P_2 and P_{2+} , depending on the temperature variations of water (maximum consumption registered at water temperature 14-18⁰C). Also, the positive result of the growth process was possible by providing an optimum level of physical and chemical parameters of the production environment (water flow about 0.1 l / m² / second, renewal of the water 4-5 times per day) and optimal growth density (150 fish P_{1+} and P_2 / m² pool spring, autumn, winter and 50-70 fish / m² during the summer).

Encouraged by the good quality of the biological material and the optimal provision of environmental conditions (food, growth density, water physic-chemical parameters,

prophylactic measures etc.), the high growth intensity allows the utilization of the rainbow trout for consumption at an age early production and thus ensure the profitability of fish production by reducing the cost of long-term maintenance of this age group in trout. The management applied effectively in the farm limited the losses, at only about 5-6% of total consumption trout.

The economic efficiency of trout breeding is influenced and conditioned by both the growth rate and the weight reached at the age of recovery as well as *the specific feed consumption* (the amount of feed needed to achieve a kilogram of growth).

The price of sale / purchase of the consumption trout increases or decreases depending on the costs incurred throughout the period of exploiting the fish, an important role in the structure of production costs starring amount of feed given during this period. The feed price depends on their nutritional quality given by the protein and energy value of the recipe, as well as the vitamin and mineral content indispensable to fish life.

In the trout farm analyzed, by calculating the total amount of feed given to the rate of increase achieved, relative to the total amount of recovered fish (trout about 25 tons per year

P_{2+}) there was determined the *coefficient of conversion* of feed of about 1.18-1.20 kg, meaning that, to obtain a kilogram of trout, 1.18-1.20 kg of granular combined fodder is needed.

To improve feed conversion, it was necessary to permanently monitor the physico-chemical parameters of water in growing pools (especially temperature, oxygen content and pH of water), manual feeding for better fish behavior monitoring during their feeding, their appetite and their state of health, the observance of the population density of the basins, in order to eliminate stress in case of overcrowding.

Phenotypic characterization of the biological material analysis was conducted by somatometria, which involved carrying out the main *body measurements* in order to assess development of the body's overall trout two years old (P_2), the ratio of different body regions, the evolution of the growth and maintenance status. At the same time, the *weighing* of the analyzed fish was carried out. Subsequently, the primary data obtained were statistically processed and the values of the statistics and the measurements are presented in Table 2.

Table 2. The values of the main body dimensions of two-year rainbow trout (P_2)

Analyzed feature	Media (X)	Standard error ($S_{\bar{X}}$)	Variance (S^2)	Standard deviation (S)	Coefficient of variation (CV%)
Total length trunk (cm)	30.32	0.20	2.17	1.47	4.84
Standard length trunk (cm)	27.10	0.13	0.95	0.97	3.57
Length statutory (cm)	28.35	0.11	0.61	0.78	2.75
Commercial length (cm)	23.10	0.06	0.21	0.45	1.94
Maximum height trunk (cm)	7.50	0.05	0.16	0.40	5.33
Minimum height trunk (cm)	3.20	0.04	0.10	0.31	9.68
Large perimeter trunk (cm)	16.60	0.07	0.27	0.51	3.07
Small perimeter trunk (cm)	7.45	0.06	0.19	0.43	5.77
Thick trunk (cm)	5.44	0.06	0.22	0.46	8.45
Caudal peduncle length (cm)	4.12	0.04	0.12	0.34	8.25
Head length (cm)	5.10	0.05	0.14	0.37	7.25
Body weight (g)	333	0.12	0.74	0.86	25

Total body length was determined by measuring the distance from the tip of the muzzle fish to the imaginary line joining the caudal fin lobes and showing the average value of 30.32 cm. As a result of the statistical calculations, it appears that this characteristic has a small variability coefficient (4.84%),

which means that, the biological material analyzed has very good uniformity of this parameter.

Standard length of body of trout for two years is given by the distance measured from the tip of the muzzle to the end of the salve shell and for the 50 analyzed samples presented the

average value of 27.10 cm with a coefficient of small variability (3.57%).

Values obtained for *the regulatory length* (the distance measured from the middle of the eye to the tip of the caudal fin) and *the commercial length* (distance measured from the middle of the eye to the back base of the anal fin) were 28.35 cm, 23.10 cm respectively, with coefficient of variation of the field lying in the minimum variability. The regular length is about 1.07 times the total length of the body and the commercial length is about 1.31 times.

To assess the degree of depth of the trunk was determined by *the maximum height and the minimum height of the body*, given the distance measured from the edge of the dorsal to the ventral where the trunk is the highest, or where the depth is the lowest, more precisely the stems caudal. The average values obtained were 7.50 cm, 3.20 cm respectively, and therefore, the maximum height is in the range of 4.04 times the total length and the minimum about 9.48 times. The coefficient of variation has little value for the first attribute, and for the minimum height coefficient slightly increases at the boundary between the small and medium (9.68%).

The big perimeter and the small perimeter which define the circumference of the body measured by surrounding the trunk with the centimeter where the height a is maximum or

minimum, recorded the average value of 16.60 cm and 7.45 cm respectively and the low values of the coefficient of variability indicate good homogeneity of the analyzed fish population. The small perimeter encompasses in the large perimeter about 2.23 times, and it is included in the total average body length of 1.83 times.

Thickness of trunk (bicostal diameter) is the distance measured where the body is the maximum convexity and helps shape the overall body conformation of the trout. This attribute showed the average value of 5.44 cm and the variability of about 8.5%. **The body weight** determined by weighing 50 rainbow trout two years old, showed an average of 333 g per fish and a high coefficient of variability. The body weight is good and exceeds the minimum weight at which the rainbow trout can be sold, that is, the commercial weight, which has an average value of 200 grams.

The results of the measurements suggest that the fish analyzed showed good fish body development for age and good homogeneity of characters somatic (coefficient of variation less than 10%), except the body weight.

To assess overall body development trout and determining the proportionality of various body regions, with somatometric results were calculated **indices body** (Table 3).

Table 3. The values of the main body indices of two-year rainbow trout (P₂)

Body index	Number of individuals measured	Body index value
Fattening Index	50	1.67%
Profile Index	50	3.61
Quality Index	50	1.63
Thickness Index	50	20.07%
Carnosity Index	50	18.81%

The fattening index = [Body Weight / (Standard length trunk)³] x 100 = [333 / (27.10)³] x 100 = 1.67%

Profile Index (format) = Standard length trunk/ Maximum height trunk = 27.10 / 7.50 = 3.61

Quality Index = Standard length trunk/ Large perimeter trunk = 27.10 / 16.60 = 1.63

Thickness Index = (Thick trunk / Standard length trunk) x 100 = (5.44 / 27.10) x 100 = 20.07%

Carnosity Index = (Head Length/Standard length trunk) x 100 = (5.10/27.10) x 100 = 18.81%.

CONCLUSIONS

The rainbow trout one year and a summer old (P₁₊) showed good growth dynamics, materialized in a total average increase of 150 g / fish from basin populations to autumn inventory and the average daily of 0.83 g / fish. In the spring-autumn growth period, body weight increased by about 4.33 times (from 45 g / fish in July, to 195 g / fish inventory in the autumn).

In the October-March increase period, the rainbow trout two years old (P₂) recorded a

total average increase of 138 g / fish and a daily average gain of 0.92 g / fish, and rainbow trout for two years and a summer (P₂₊) achieved a total average increase of 102 g / fish and a daily average gain of 0.85 g / fish. Therefore, from the beginning to the end of the growth, the body weight of P₂ rainbow trout increased by about 1.71 times (195 g / fish *versus* 333 g / fish), and the weight of rainbow trout P₂₊ increased about 1.1 times (333 g / fish *versus* 435 g / fish).

Proper technological management in trout farming (rational feeding of trout with superior quality and optimum feed, optimal provision of physico-chemical parameters of water etc.), allowed to get a good coefficient of feed conversion (specific consumption) of 1.18-1.20 kg of combined fodder.

The main characteristics of the rainbow trout somatic two years (P₂) (total length trunk = 30.32 cm, standard length trunk = 27.1 cm, maximum height trunk = 7.5 cm, large perimeter trunk = 16.6 cm, thickness trunk = 5.44 cm etc.), demonstrates the proper development and correctness of the body conformation of this age group, and the low variability coefficients (under 10%) highlights the high homogeneity of trout in trout farming.

The body index values (fattening index = 1.67%, profile index = 3.61, quality index = 1.63, thickness index = 20.07%, carnosity index = 18.81%) denotes the harmony of body development, good body proportionality and high growth dynamics.

REFERENCES

- Bud I., Vlădău V., Ștefan R. (2007). *Peștii răpitori. Creștere, înmulțire, valorificare*. Editura Ceres, București.
- Bud I., Ionescu O., Vlădău V., Pop S.N. (2007). *Peștii din apele reci - Păstrăvii*. Editura RISOPRINT, Cluj-Napoca.
- Bud I., Vlădău V. (2004). *Ghid de lucrări practice în piscicultură*. Editura Risoprint, Cluj-Napoca.
- Decei P. (2001). *Creșterea salmonidelor*. Editura TERRA DESIGN, Gura Humorului.
- Lustun L. (1985). *Lucrări practice de piscicultură*. Institutul Agronomic „Nicolae Bălcescu”, Facultatea de Zootehnie, București.
- Neagu Iuliana, Crivineanu Carmen (2005). *Creșterea animalelor*. Editura Printech, București.
- Păsărin B. (2007). *Salmonicultură practică*. Editura Alfa, Iași.
- Sandu Gh. (1995). *Modele experimentale în zootehnie*. Editura Coral-Sanivet, București.
- Tacu A. (1968). *Metode statistice în zootehnie și medicină veterinară*. Editura Agrosilvică, București.
- Turliu N. Gh. (2008). *Piscicultura practică*. Editura Ceres, București.

A STUDY CONCERNING QUALITY ASSESSMENT AND PROCESSING PARTICULARITIES IN CERTAIN DAIRY PRODUCTS

Diana Oana OPREA, Carmen Daniela PETCU, Emilia CIOBOTARU-PÎRVU

University of Agronomic Sciences and Veterinary Medicine of Bucharest, Faculty of Veterinary Medicine, 105 Independenței Spl, District 5, 050097, Bucharest, Romania

Corresponding author email: oprea_diana2008@yahoo.com

Abstract

Featured by the so-called "nutritional value" and being highly beneficial for the young mammals, the milk is an important alimentary component. Milk and dairy products undergo a large number of analyzes, aiming to establish chemical composition, assessing of nutritional value, identifying falsifications, and adhering to manufacturing prescriptions. Through analyzes changes due to non-compliance with hygiene rules during milking or transport, can be identified and highlighted. The quality of raw milk is crucial in order to obtain dairy products that meet the applicable legal requirements. Standard laboratory analyzes have been used in this study in order to assess physical and chemical parameters of raw milk, such as: density, acidity, fat content, protein and dry matter. A total of 201 samples, consisting of milk samples for consumption and acidic dairy products, harvested from a processing plant from the south of the country were analyzed. Laboratory analyzes were carried out to identify the quality of raw milk and any differences in the nutritional values of the acidic dairy products. The results proved that parameters taken into consideration (fat, density, acidity) were within the admitted limits for all analyzed products. The density of the milk falls within the limits of the assortment, with values ranging between 1,028 g/cm³ and 1,030 g/cm³. Acidity is within admissible parameters, with an average of 15.06°T for drinking milk, 84.75°T for yogurt, 82.76°T for sour-batter milk and an average of 67.60°T for sour cream. As a technological particular step of obtaining dairy products, the high pasteurization method is used in the study unit, which guarantees a longer shelf-life. In conclusion, the products under study were within the admissibility parameters set by the manufacturing unit in accordance with the legal provisions.

Key words: milk, dairy product, nutritional value, pasteurization.

INTRODUCTION

Milk is an important food component. Raw milk is characterized by so-called "nutritional value", especially for young mammals, because it meets the body requirements in energy, plastic and biostimulating substances, positively influencing the health of consumers. This is an important source of protein, vitamins and minerals. Cow's milk is a major source of calcium. (Worsley et al., 2003; Usturoi M.G., 2007; Claeys et al., 2013; Claeys et al., 2014; Ladokun et al., 2014).

Food quality is an increasing area of study, food currently exceeding the feed limit. People need not only food in adequate amounts but also high-quality food (Visoescu et al., 2015).

It is considered that a liter of milk feeds the human body in the same way as (Figure 1): 750 g calf meat, 500 g of fish, 400 g pork, 8-9 eggs, 125 g of bread, 1400 g apples, 2600 g cabbage (Usturoi M. G., 2007).

Normally, foods should not contain physical traces (metal or plastic pieces, hair, nails), chemical compounds (substances used in sanitation, toxic compounds) or hazardous biotic agents (pathogenic bacteria, parasites). Although, many of the chemicals, such as preservatives and food colorants, flavor enhancers have become indispensable for the normal development throughout people's lives (Savu C., Petcu C. D., 2002; Verraes et al., 2015).

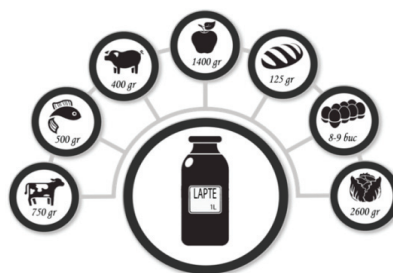


Figure 1. Comparative nutritional value of one liter of milk

Excessive chemical overdosage and environmental pollution through the multitude of human activities, as well as intentional addition of substances with various roles (stabilizers, preservatives, dyes etc.) resulted in unsafe foodstuff.

MATERIALS AND METHODS

Milk and dairy products are subject to a large number of analyzes before being placed on the market. Therefore, a foodstuff should be tested for assessing of chemical composition, evaluation of nutritive value, identification of falsifications, framing this way the product into the standard category.

The dairy processing unit taken into study is located in Southern Romania and it is supplied with milk from authorized sanitary veterinary farms, frequency of supply depending on the performance of animals and quantity of milk obtained from them (Tăpăloagă et al., 2018).

Raw milk is chilled in cooling tanks, then taken over in the company's tanks and transported to processing plant, where is analyzed and further processed. A number of qualitative parameters are tested in the laboratory at the reception of milk, for assessing whether the characteristics of the milk have changed due to non-compliance with the rules of hygiene during milking, transport or if any falsifications have been made (Varraes et al., 2015).

Laboratory analyzes used for this research aimed assessing of physical and chemical parameters of raw milk such as: density (areometric method), acidity (Thorner method), fat content, protein and dry matter (butirometric method or by using the Funke Gerber[®]LactoStar dairy analyzer) Butler et al., 2011). Samples were harvested between April 2017 and April 2018.

In order to identify the differences between some dairy production technologies, the corresponding technological flows have been followed in a dairy processing unit. Subsequently, 201 samples of milk for consumption and acidic dairy products were analyzed in the unit's own laboratory.

The main purpose of the analyzes was to identify the quality of raw materials and the technologies for obtaining dairy products, as well as to identify quality differences between categories of dairy products.

RESULTS AND DISCUSSIONS

Previous studies had shown that there is a direct correlation between the quality of the milk used in the preparation of acidic dairy products and that of the finished products obtained from it (Sala C.C., 2008; Murphy et al., 2016). That means only fresh milk with a lower contamination and a normal composition (excluding milk containing colostrum, counterfeit milk, milk from antibiotic-treated animals, milk from cows with mastitis, etc.).

The milk is refrigerated and stored at 2-4°C immediately after milking, to avoid altering of organoleptic characteristics, rapid bacterial growth, as well as increasing of acidity (Stancu et al., 2001; Tremonte et al., 2014).

Analyzing the results obtained from the laboratory determinations, it was found that considered parameters (fat, density, acidity) are within the permissible limits, according to the sanitary veterinary in force provisions.

Results and discussions on laboratory analysis of raw milk

A batch of 31 samples of raw milk were taken into study, of which ten samples for production of 0.1% fat skim milk, ten samples for 1.5% fat pasteurized milk and eleven samples for 1.8% fat pasteurized milk.

No significant variations were observed in physical and chemical parameter for the aforementioned categories of raw milk.

Determination of the fat content of finished dairy products has revealed different values of fat content, the percentage of fat being specific to each product.

The density of the analyzed milk samples corresponds to the values established by the company standards.

The density of the milk falls within the limits of the analyzed assortment, the lowest value being 1,028 g/cm³ and the highest value reaching the level 1,030 g/cm³.

The highest values of acidity are recorded in the warm season, with a maximum of 16^oT, in the cold season the acidity value being minimal, with an average of 15.06^oT.

The results obtained from the physico-chemical determinations of the milk samples are presented in Table 1 and Table 2.

Table 1. Results obtained from the biochemical analysis of 0.1% fat skim milk samples

PRODUCT	No.	Fat %	Density g/cm ³	Acidity °T
SKIM MILK 0.1% fat	1.	0.1	1,030	16
	2.	0.1	1,029	15
	3.	0.1	1,029	15
	4.	0.1	1,029	15
	5.	0.1	1,029	15
	6.	0.1	1,029	15
	7.	0.1	1,029	15
	8.	0.1	1,029	15
	9.	0.1	1,029	15
	10.	0.1	1,029	15

Table 2. Results obtained from the biochemical analysis of 1.5% fat drinking milk samples

PRODUCT	No.	Fat %	Density g/cm ³	Acidity °T
PASTEURIZED MILK 1.5% fat	1.	1.5	1,029	16
	2.	1.5	1,028	15
	3.	1.5	1,028	15
	4.	1.5	1,028	15
	5.	1.5	1,028	15
	6.	1.5	1,028	15
	7.	1.5	1,028	15
	8.	1.5	1,028	15
	9.	1.5	1,028	15
	10	1.5	1,028	15

Results and discussions on laboratory analysis of yoghurt

A total of 32 yoghurt samples were analyzed in the study unit laboratory, including 13 samples of 0.1% fat yoghurt, eight samples of 2% fat yoghurt and eleven samples of 2.8% fat yogurt. Laboratory analysis proved that different percentages of fat correspond to each assortment of acidic dairy product.

The minimum value of acidity allowed for yoghurt is 75°T and the maximum limit is 140°T, increasing steadily during production.

The results obtained from the physico-chemical determinations of yoghurt samples are presented in Table 3, Table 4 and Table 5.

Table 3. Results obtained from the biochemical analysis of 0.1% fat yogurt samples

PRODUCT	No.	Acidity at inoculation °T	Fat %	Acidity on delivery °T
DIET YOGURT 0.1% Fat	1.	15	0.1	85
	2.	15	0.1	86
	3.	15	0.1	88
	4.	16	0.1	90
	5.	15	0.1	86
	6.	15	0.1	84
	7.	15	0.1	88
	8.	15	0.1	90
	9.	15	0.1	88
	10.	15	0.1	86
	11.	15	0.1	85
	12.	16	0.1	86
	13.	15	0.1	85

Table 4. Results obtained from the biochemical analysis of 2% fat yogurt samples

PRODUCT	No.	Acidity at inoculation °T	Fat %	Acidity on delivery °T
YOGURT 2% Fat	1.	15	2	80
	2.	15	2	82
	3.	15	2	82
	4.	15	2	77
	5.	15	2	86
	6.	15	2	78
	7.	15	2	82
	8.	15	2	84

Table 5. Results obtained from the biochemical analysis of 2.8% fat yogurt samples

PRODUCT	No.	Acidity at inoculation °T	Fat %	Acidity on delivery °T
YOGURT 2.8% Fat	1.	15	2.8	83
	2.	15	2.8	84
	3.	15	2.8	84
	4.	16	2.8	90
	5.	15	2.8	82
	6.	15	2.8	82
	7.	15	2.8	84
	8.	15	2.8	88
	9.	15	2.8	88
	10.	16	2.8	81
	11.	15	2.8	88

It is noted that values have ranged between 77-90°T, with an average of 84.75°T, concluding that there are no irregularities in its freshness.

Results and discussions on laboratory analysis of sour-batter milk

A number of 13 samples of 2% fat sour-batter milk were analyzed. Taking into account that the maximum allowed acidity for milk is 120°T, following the results obtained from the physico-chemical determinations of the sour-batter milk samples presented in Table 6, it is found that values range from 80-86°T, with an average of 82.76°T, concluding that there are no irregularities in its freshness.

Table 6. Results obtained from the biochemical analysis of 2% fat sour-batter milk samples

PRODUCT	No.	Acidity at inoculation °T	Fat %	Acidity on delivery °T
SOUR- BATTER MILK 2% Fat	1.	15	2	80
	2.	15	2	81
	3.	15	2	81
	4.	15	2	86
	5.	15	2	84
	6.	15	2	86
	7.	15	2	80
	8.	15	2	80
	9.	15	2	81
	10.	15	2	86
	11.	15	2	86
	12.	16	2	82
	13.	15	2	83

Results and discussions on laboratory analysis of sana product

A total of 12 samples of 3.6% fat sana product were analyzed in the dairy plant own laboratory. The maximum admitted acidity for the sana is 120°T. Following the results obtained from the physico-chemical determinations of the sana samples presented in Table 7, it is found that the values are in the range of 80-84°T with an average of 81.25°T. Thus, it has been concluded that no irregularities of freshness occurred in this product.

Table 7. Results obtained from the biochemical analysis of sana samples

PRODUCT	No.	Acidity at inoculation °T	Fat %	Acidity on delivery °T
SANA 3.6% Fat	1.	15	3.6	82
	2.	15	3.6	81
	3.	15	3.6	81
	4.	16	3.6	82
	5.	15	3.6	80
	6.	15	3.6	80
	7.	15	3.6	80
	8.	15	3.6	84
	9.	15	3.6	84
	10.	15	3.6	80
	11.	16	3.6	81
	12.	15	3.6	80

Results and discussions on laboratory analysis of kefir

A total of 8 kefir samples were analyzed, with an acidity between 76-84°T, falling within the limits of the assortment, thus achieving optimum freshness.

The results obtained from the physico-chemical determinations of the kefir samples are presented in Table 8.

Table 8. Results obtained from the biochemical analysis of kefir samples

PRODUCT	No.	Acidity at inoculation °T	Fat %	Acidity on delivery °T
KEFIR	1.	15	3.3	78
	2.	15	3.3	82
	3.	15	3.3	82
	4.	15	3.3	76
	5.	15	3.3	84
	6.	15	3.3	84
	7.	16	3.3	81
	8.	15	3.3	84

Results and discussions on laboratory analysis of fermented cream and sweet cream

A total of 36 samples of fermented cream were analyzed, of which 17 samples of 12% fat fermented cream, 12 samples of 18% fat fermented cream and 7 samples of 20% fat

fermented cream. The fat content values are in line with the sour cream recipes obtained in the study unit.

Unsignificant differences have been recorded in acidity of the sour cream, its values being in the range 65-72°T, but not exceeding the maximum allowed of 90°T.

The average acidity value for 12% fat fermented cream is 68°T, for 18% fat fermented cream it is around 67.17°T and for 20% fat fermented cream is 67.42°T.

The results obtained from the physico-chemical determinations of the fermented cream samples are shown in Table 9, Table 10 and Table 11.

Table 9. Results obtained from the biochemical analysis of 12% fat fermented cream samples

PRODUCT	No.	Acidity at inoculation °T	Fat %	Acidity on delivery °T
SOUR CREAM 12% Fat	1.	15	12	67
	2.	15	12	67
	3.	15	12	66
	4.	15	12	66
	5.	15	12	67
	6.	15	12	68
	7.	15	12	67
	8.	14	12	68
	9.	14	12	68
	10.	15	12	70
	11.	15	12	72
	12.	15	12	70
	13.	15	12	70
	14.	15	12	70
	15.	15	12	67
	16.	15	12	67
	17.	15	12	66

Table 10. Results obtained from the biochemical analysis of 18% fat fermented cream samples

PRODUCT	No.	Acidity at inoculation °T	Fat %	Acidity on delivery °T
SOUR CREAM 18% Fat	1.	15	18	65
	2.	15	18	68
	3.	15	18	67
	4.	15	18	65
	5.	15	18	66
	6.	15	18	66
	7.	14	18	67
	8.	15	18	70
	9.	15	18	70
	10.	15	18	68
	11.	16	18	66
	12.	15	18	68

Table 11. Results obtained from the biochemical analysis of 20% fat fermented cream samples

PRODUCT	No.	Acidity at inoculation °T	Fat %	Acidity on delivery °T
SOUR CREAM 20% Fat	1.	15	20	65
	2.	15	20	67
	3.	15	20	68
	4.	15	20	65
	5.	15	20	72
	6.	15	20	68
	7.	15	20	67

In the case of sweet cream samples, seven samples were analyzed in the dairy plant own laboratory, their average acidity being 17.14°T. The results obtained from the physico-chemical determinations of the sweet cream samples are shown in Table 12.

The organoleptic features of analyzed products did not show any nonconformities in appearance, consistency, color or smell during their shelf-life.

The results obtained from the summary statistics (mean values and standard deviation)

of milk samples collected from dairy plant are shown in Table 13.

Table 12. Results obtained from the biochemical analysis of sweet cream samples

PRODUCT	No.	Fat %	Acidity °T
SWEET CREAM	1.	32	16
	2.	32	18
	3.	32	18
	4.	32	16
	5.	32	16
	6.	32	18
	7.	32	18

Table 13. Summary statistics of milk samples collected from dairy plant (mean values and standard deviation)

Plant products	Measure	Density	Acidity at inoculation °T	Acidity on delivery °T	Total samples
0.1% fat skim milk		1.0291±0.000316		15.1±0.316228	10
1.5% fat drinking milk		1.0281±0.000316		15.1±0.316228	10
0.1% fat diet yogurt			15.1538±0.375534	86.6923±1.93152	13
2% fat yogurt			15±0	81.375±2.973094	8
2.8% fat yogurt			15.1818±0.40452	84.909±3.048099	11
2% fat sour-batter milk			15.0769±0.27735	82.769±2.521701	13
Sana			15.1667±0.389249	81.25±1.484771	12
Kefir			15.1250±0.353553	81.375±2.973094	8
12% fat fermented cream			14.8823±0.332106	68±1.767767	17
18% fat fermented cream			15.0833±0.288675	67.167±1.696699	12
20% fat fermented cream			15±0	67.428±2.370453	7
Sweet cream				17.143±1.069045	7

CONCLUSIONS

The results of the tests on milk and dairy samples have shown that organoleptic and physico-chemical parameters are respected, which means that raw material used in their manufacture meets the requirements of the standards, the hygiene conditions also being respected.

As a technological characteristic of obtaining dairy products, the high temperature pasteurization method is used in the dairy plant, which guarantees a longer shelf life.

The technological features of obtaining dairy products in the investigated plant fall within the general technologies applicable to the field of activity.

Moreover, responsible persons with food safety and quality have established and implemented self-control programs, performing assessments in both in-house or external laboratories.

REFERENCES

- Butler, G., Nielsen, J. H., Larsen M. K., Rehberger, B., Stergiadis, S., Canever, A., Leifert, C. (2011). The effects of dairy management and processing on quality characteristics of milk and dairy products. *NJAS – Wageningen Journal of Life Sciences*, 58, 97-102.
- Claeys, W. L., Cardoen, S., Daube, G., De Block, J., Dewettinck, K., Dierick, K., De Zutter, L., Huyghebaert, A., Imberechts, H., Thiange, P., Vandenas, Y., Herman, L. (2013). Raw or heated cow milk consumption: Review of risks and benefits. *Food Control*, 31, 251-262.
- Claeys, W. L., Verraes, C., Cardoen, S., De Block, J., Huyghebaert, A., Raes, K. (2014). Consumption of raw or heated milk from different species: an evaluation of the nutritional and potential health benefits. *Food Control*, 42, 188-201.
- Ladokun, O., Oni, S. (2014). Fermented Milk Products from Different Milk Types. *Food and Nutrition Sciences*, 5, 1228-1233.
- Murphy, S. C., Martin, N. H., Barbano, D. M., Wiedmann, M. (2016). Influence of raw milk quality on processed dairy products: How do raw milk quality test results relate to product quality and yield? *Journal of Dairy Science*, 99(12), 10128-10149.

- Sala, C. C. (2008). *Igiena, tehnologia și controlul laptelui și a produselor derivate*. Timișoara, RO: Editura Eurobit.
- Savu, C., Petcu, C. D. (2002). *Igiena și controlul produselor de origine animală*. București, RO:Editura Semne.
- Stancu, I., Tudor, L., Petcu, E. (2001). *Măsuri privind salubritatea produselor alimentare de origine animală*. București, RO:Editura Coral Sanivet.
- Tăpăloagă, D., Tăpăloagă P. (2018). Sexed semen and the reproductive management of a dairy farm. *Journal of Biotechnology*, 280, S4-S5.
- Tremonte, P., Tipaldi, L., Succi, M., Pannella, G., Falasca, L., Capilongo, V., Coppola, R., Sorrentino, E. (2014). Raw milk from vending machines: Effects of boiling, microwave treatment, and refrigeration on microbiological quality. *Journal of Dairy Science*, 97(6), 3314-3320.
- Usturoi, M. G. (2007). *Tehnologia laptelui și a produselor derivate*. Iași, RO:Editura Alfa.
- Verraes, C., Vlaemynck, G., Van Weyenberg, S., De Zutter, L., Daube, G., Sindic, M., Uyttendaele, M., Herman, L. (2015). A review of the microbiological hazard of dairy products made from raw milk. *International Dairy Journal*, 50, 32-44.
- Visoescu, I. D., Petcu, C. D., Tăpăloagă, D. (2015). Researches regarding the influence of packaging on the quality of some dairy products. *Journal of Biotechnology*, 208, S19.
- Worsley, A., AEM Bus (2003). Consumers sensory and nutritional perceptions of three types of milk. *Public Health Nutrition*, 6(2), 201-208.

A STUDY ON SENSORIAL ANALYSIS AND THE ASSESSMENT OF THE NUTRITIVE VALUES OF BREAD ASSORTMENTS

Carmen Daniela PETCU, Oana Diana OPREA, Laura STANCIU,
Oana Mărgărita GHIMPEȚEANU

University of Agronomic Sciences and Veterinary Medicine of Bucharest, Faculty of Veterinary
Medicine, 105 Independenței Spl, District 5, 050097, Bucharest, Romania

Corresponding author email: carmen28petcu@gmail.com

Abstract

Bread is a product that occupies an important place in the basic nutrition of consumers, obtained by the total or partial baking of a dough properly grown, made from flour, water and yeast, with or without added salt. In order to analyze the impact of various types of bread on consumers, 30 samples of sliced white bread produced by different producers - 6 samples from each assortment - were studied. The following analyzes were carried out: determination of sodium chloride content, determination of protein content, verification of the nutritional values present on the label and sensory analysis of the samples included in the research. The studies have taken place in a factory laboratory and in the laboratory of the Faculty of Veterinary Medicine in Bucharest. The sodium chloride content of the samples analyzed falls within the values indicated on the label and the protein content showed values within the declared production limits on the product labels. At the same time, a questionnaire was applied to 207 subjects aged between 21 and over 60 years. The purpose of this questionnaire was to obtain information from consumers about their preferences regarding bread consumption and the appreciation of the correspondence between what is written on the label and what is found in the bread. Analyzing the results, it is found that most people prefer to eat bread with both hot food and sandwiches, while others do not eat bread at all. Buyers put more emphasis on the freshness of the product, to the detriment of the ingredients used in manufacturing. As a result of the study conducted between 2017-2018, conclusions could be drawn on consumer's preferences regarding bread consumption and the price-quality balance of purchased products.

Key words: bread, salt, freshness.

INTRODUCTION

Bread is a product that occupies an important place in the basic nutrition of consumers, obtained by baking of dough properly grown, made from flour, water and yeast, with or without added salt (Hammes WP, Gänzle MG 1998; Sîrbu A., 2001; Sîrbu A., 2009; Mitrănescu E. et al., 2010).

Bread is a basic food that is consumed daily, and for this reason, the bakery industry occupies a significant place in the consumer goods market (Lascu D., 2008; Tăpăloagă D., 2012).

In the baking industry, in the production process, the following production phases take place: preparation of raw and auxiliary materials, dosing of raw and auxiliary materials, kneading of dough, fermentation, division, pre-modelling and initial rising, modelling, final rising, baking, cooling, packing and storing (Sîrbu A., 2009).

Because of the both the medium and the long term social effects of food and nutrition, nutritionists have set the criteria for a healthy diet and have proposed the "food pyramid", as a food guide, which highlights the main groups of foods and their weight in a balanced diet (Smith JP et al., 2004).

At the lower levels of the food pyramid are products derived from cereals. It is recommended that the cereal products, including bakery products, to be consumed daily and in moderate amounts (Willett et al., 1995; Banu C., 1998).

From nutritional point of view, bread mainly gives the nutritional value of the flour and other raw materials from which it is obtained (Bordei D., 2005; Ciesarova Z. et al., 2009; Marin M. et al., 2012).

MATERIALS AND METHODS

In order to analyze the impact of various types of bread on consumers, 30 samples of sliced

white bread produced by different producers, 6 samples from each assortment, were studied. The following analyzes were carried out: determination of sodium chloride content, determination of protein content, verification of the nutritional values present on the label and sensory analysis of the samples included in the research.

The studies took place in a factory laboratory and in the laboratory of the Faculty of Veterinary Medicine of Bucharest.

Sensory analysis

A questionnaire applied to 207 subjects was used to develop the research. The purpose of this questionnaire was to obtain information from consumers about their preferences regarding bread consumption and the appreciation of the consistency between what is written on the label and what is found in the bread. The study took place between 2017-2018.

Through the organoleptic method, the following were appreciated: the external appearance of the bread, the volume, the colour and structure of the crust, the elasticity and porosity of the crumb of the bread, the taste, the smell, the signs of alteration and the presence of the foreign bodies.

External appearance is determined by examining the entire bread. Symmetry is examined, noting the normal or incorrect shape and indicating the defects of the shape.

The sensory analysis was done by the score method (Table 1), the steps of appreciating the sensory quality of the white bread were determined by the total score obtained (Table 2) and based on this, the quality level of the product was determined (Mihaiu M. et al., 2013).

Sodium chloride analysis

The salt content dosing was performed according to SR 91:2007. The method is based on the extraction of chlorine ions in the aqueous extract and their determination by titration with silver nitrate in the presence of potassium chromate or ammonium chromate as an indicator (Mohr method).

Protein content analysis

Raw protein content is the total content of nitrogen compounds calculated by multiplying

the nitrogen content by a conventional factor. The method is based on mineralization of the bread sample with sulfuric acid in the presence of a catalyst, according to the Kjeldahl method, alkalisation of the mineralized, distillation and titration of released ammonia (SR 13013-3: 1994).

Table 1. Evaluation of the sensory quality of white bread by score method scale (Mihaiu M., 2013)

The sensory feature		
Form and volume of the product		
Score scale	Description of the characteristics of the product examined	Content points
0-4	Correct, symmetrical, aesthetic shape, proving the care with which the bread was made, non-flattened or with bulging bumps.	4
	The product has the established shape but is asymmetrical and the volume is increased enough.	2
	Bread has no established aspect, is anaesthetic, deformed, flattened.	0
The colour and appearance of the crust		
0-4	The product has a well-rounded crust, the surface of the crust is smooth, glossy without cracks; the crust of bread is crisp.	4
	The product has uneven baked crust, it is too brown or too pale, has rough surface, the crust is not crisp, but a little soft.	2
	The bread has a whitish crust, due to insufficient baking, especially in the sides, has the wrinkled surface or the dirty crust.	0
The degree of baking and the appearance of the crumb		
0-6	The bread is well baked, so that when biting into the bread crust, there is a clear, clean sound, characteristic of the baking product, has the elastic crumb and the crumb colour is uniform.	6
	The bread is baked enough, so that when biting into the crust there is a muffled sound, the crust is slightly soft, the bread core does not break.	3
	The bread presents half-baked remains dough, by the pressing of the core it becomes irreversibly deformed and it is easily crumbling when cut.	0

Table 2. Evaluation scale of results of sensory examination of white bread by score method (Mihaiu M., 2013)

Appreciation step	Total score	General description of the appreciation step
Very good product	24.1-30	Bread of exceptional quality, ideal.
Good product	18.1-24	Good quality bread.
Satisfactorily product	12.1-18	Bread with light defects, of proper quality.
Unsatisfactory product	6.1-12	Bread with pronounced defects, of poor quality.
Very unsatisfactory product	0.1-6	Altered bread, with great changes in the characteristics.

RESULTS AND DISCUSSIONS

Results obtained from the questionnaire interpretation

The subjects of this questionnaire were 207 persons. Question answers were statistically represented in graphical and tabular form. Following the interpretation of the results, it was concluded that more responses were provided by people living in urban areas and the number of female respondents to the questionnaire was higher compared to the number of male respondents. Most responses were provided by people aged 21-30 years, respectively 117 subjects out of a total of 207. Analysing the answer to the question "How often do you buy bread?", was noticed that 3.4% of people did not consume bread and a considerable percentage of 42% buy bread daily (Table 3, Figure 1).

Table 3. How often subjects buy bread?

Frequency	The number of people	Percentage value %
Every day	87	42.0
Once every two days	65	31.4
Once a week	48	23.2
Do not consume	7	3.4

Analysing the answer to the question, "How much bread do you eat per day?", it is noticed that more than half of the interviewed subjects,

namely 62.32% consumed less than a half a loaf of bread per day, and the opposite was a percentage of 6.28% consuming more than one bread per day (Table 4, Figure 2).

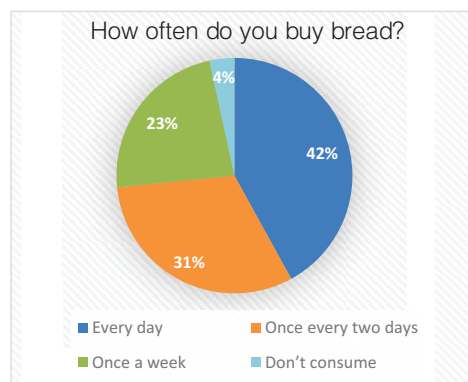

Figure 1 - Graphical representation of bread purchase frequency

Table 4. How much bread the subjects eat per day?

Quantity	The number of people	Percentage value %
Less than half	129	62.32
A half	28	13.53
A bread	37	17.87
More than one bread	13	6.28

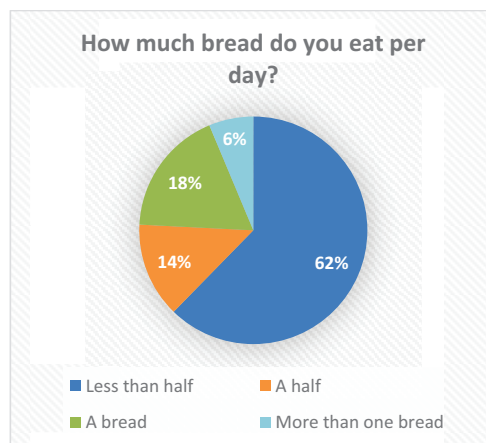


Figure 2 - Graphical representation of the amount of bread consumed daily

Analysing the answer to the question "At which meal do you eat bread?", it could be seen that most of the subjects consume bread at all meals (Table 5, Figure 3).

Table 5. At what meal the subjects eat bread?

Meals	The number of people	Percentage value %
At breakfast	57	27.53
At lunch	40	19.32
At dinner	9	4.35
At all meals	101	48.80

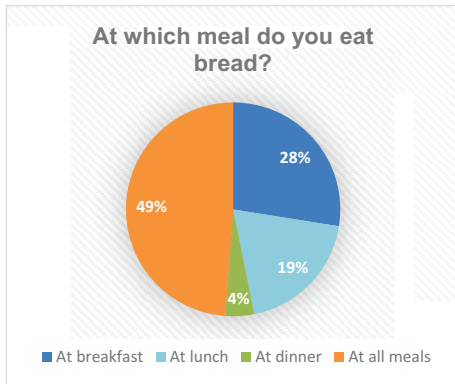


Figure 3 - Graphic representation of the meals to which the subjects eat bread

Within the question "How do you eat the bread?" could be given multiple answers and most people prefer to eat bread with both hot food and sandwiches. A smaller percentage of subjects said that they ate hard bread (Table 6, Figure 4).

Table 6. How do the subjects consume bread?

The way in which bread is consumed	The number of people	Percentage value %
With hot food	152	73.43
In the sandwich	147	71.01
Hard bread	18	8.70

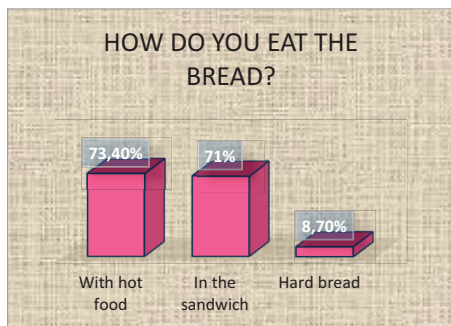


Figure 4 - Graphic representation of how the bread is consumed by the subjects

After analysing the answers to the question "Do you consider the bread as an important part of the meal from a nutritional point of view?", it appeared that approximately half of the interviewees consider the bread to be a significant part of the meal from a nutritional point of view (Table 7).

Table 7. Is bread considered nutritionally important?

Answer	The number of people	Percentage value %
Yes	101	48.80
No	106	51.20

To the question "What are the characteristics you follow when buying a bread?", the subjects offered multiple answers, and from the analysis of the results obtained, buyers put more emphasis on the freshness of the purchased product at the expense of the ingredients used (Table 8).

Table 8. Characteristics to be followed when buying bread

Characteristics	The number of people	Percentage value %
Freshness	151	72.95
Appearance (shape, volume, colour)	79	38.16
Taste and smell	85	41.06
Packaging	21	10.14
Ingredients used	95	45.89
Form of delivery (sliced / entire)	49	23.67

A very large percentage of buyers read the packaged bread label before purchasing it (Table 9).

Table 9. Is the label of packed bread read?

Answer	The number of people	Percentage value %
Yes	142	68.60
No	65	31.40

In the question "What information from the product label you are interested in?", the answers were multiple and the majority of buyers, namely 82.12%, were interested in the shelf life period (Table 10, Figure 5).

Table 10. Information sought on the label

Information	The number of people	Percentage value %
Shelf life	170	82.12
Nutritional values	110	53.14
Quantity	32	15.45

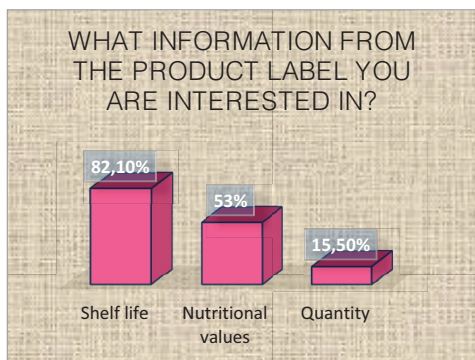


Figure 5 - Graphical representation of the information sought on the label by consumers

To the question: "Do you consider that the nutritional parameters on the label are sufficient to assess the quality of the bread?", 57% of consumers did not consider the nutritional parameters on the label to be sufficient (Table 11) and the question "Do you think that the nutritional values on the label really reflect the quality of the bread?", 72% of consumers believed that the information on the label did not show the true quality of the product (Table 12).

Table 11. Is it considered that the nutritional parameters on the label are sufficient to assess the quality of the bread?

Answer	The number of people	Percentage value %
Yes	89	43
No	118	57

Table 12. Is the nutritional value on the label actually reflecting the quality of the bread?

Answer	The number of people	Percentage value %
Yes	58	28
No	149	72

More than half from the interviewed people (62.80%), did not consider price a decisive factor in choosing bread (Table 13).

Table 13. Is the price a decisive factor in choosing the type of bread consumed?

Answer	The number of people	Percentage value %
Yes	77	37.20
No	130	62.80

A percentage of 51.70% of people interviewed believed that a higher price reflects a better quality of bread (Table 14).

Table 14. Do you think a higher price reflects a better quality of bread?

Answer	The number of people	Percentage value %
Yes	107	51.70
No	100	48.30

A sensorial analysis was performed by the score method, and the results were presented in Table 15.

Table 15. Results of sensory examination of sliced white bread

Sensory feature	Points sample 1	Points sample 2	Points sample 3	Points sample 4	Points sample 5
Form and volume	4	4	4	2	4
The colour and appearance of the crust	4	2	4	2	4
The degree of baking and the appearance of the bread core	3	3	3	3	3
core porosity and pore structure	6	4	6	6	4
Flavour	4	4	4	4	4
The taste	6	6	6	6	6
Total score	27	23	27	23	25

Samples 1 and 3 obtained the most points, respectively 27, and at the opposite pole were samples 2 and 4, which scored 23 points.

Results obtained after analysis of sodium chloride

Sodium chloride analysis was performed according to SR 91:2007, and the results are shown in Table 16.

Table 16. Sodium chloride values of the analysed samples

Sample number	Values	Mean value
Sample 1	1.15%	1.15%
	1.14%	
	1.16%	
Sample 2	1.13%	1.13%
	1.13%	
	1.15%	
Sample 3	1.26%	1.23%
	1.22%	
	1.23%	
Sample 4	1.18%	1.18%
	1.18%	
	1.20%	
Sample 5	1.25%	1.21%
	1.19%	
	1.21%	
Sample 6	1.20	1.19%
	1.18	
	1.19	

The highest value of sodium chloride was given by sample 3 (1.23%), followed by sample 5 (1.21%). The results obtained were consistent with the values written on the label.

The sodium chloride content of the samples used in the research was between 1.13% and 1.23%, results ranging from 1.10 to 1.30% on the label.

Results obtained from analysis of protein content

The results of the protein content analysis were shown in Table 17.

Table 17. Values of protein content

Sample number	Values	Mean value
Sample 1	12.80%	12.89%
	12.98%	
	12.90%	
Sample 2	12.63%	12.72%
	12.80%	
	12.75%	
Sample 3	12.74%	12.80%
	12.89%	
	12.77%	
Sample 4	12.85%	12.92%
	13.00%	
	12.92%	
Sample 5	12.26%	12.13%
	11.98%	
	12.15%	
Sample 6	12.84%	12.84%
	12.90%	
	12.78%	

The percentage of protein varied between 12.13% at sample 5 and 12.92% at sample 4. All samples corresponded to the values written on the label.

CONCLUSIONS

Following the organoleptic analysis, the samples were categorized as "very good product" and "good product", as there were no products in the "satisfactorily", "unsatisfactory" or "very unsatisfactory" categories.

The content of sodium chloride and the protein percentage of the analysed samples were within the values stated on the label and established by the technical specifications.

Most people preferred to eat bread with both hot food and sandwiches, while others did not eat bread at all. Buyers put more emphasis on the freshness of the product, to the detriment of the ingredients used in manufacturing.

After analysing all the results obtained, it was concluded that these bakery products fall within the quality standards imposed by the legislation and the results obtained were in accordance with the label values.

REFERENCES

- Banu, C., (1998). *Manualul inginerului de industrie alimentară, volum I*. București, RO: Editura Tehnica.
- Bordei, D. (2005). *Tehnologia modernă a panificației*. București, RO: Editura Agir.
- Ciesarova, Z., Kukurova, K., Bednarikova, A., Morales, J. F. (2009). Effect of heat treatment and dough formulation on the formation of Maillard reaction products in fine bakery products – benefits and weak points. *Journal of Food and Nutrition Research*, 48(1), 20-30.
- Hammes W.P., Gänzle M.G. (1998). Sourdough breads and related products. *Microbiology of Fermented Foods*, PP, 199-216.
- Lascu, D., (2008). *Enciclopedia alimentelor*. București, RO: Editura All.
- Marin, M., Drăgotoiu, D., Nicolae, C., Diniță, G., Tăpăloagă, P.R., Tăpăloagă, D., Isfan, N. (2012). The influence of using different proteolytic enzymatic produces over the characteristics of flour breading products. *Agrolife Scientific Journal*, 55, 276-280.
- Mihaiu, M., Necula, V., Babii, M., Marina, A. (2013). *Analiză senzorială*. Brașov, RO: Editura Universității Transilvania.
- Mitrănescu, E., Tudor, L., Furnaris, F., Ilie, L., Simion, V., Gonciarov, M. (2010). Researches concerning the quality of water used in a bread unit in Neamt County. *Scientific Papers Veterinary Medicine Timisoara*, 43(2), 166-169.

- Sîrbu, A. (2001). *Merceologie alimentară*. Pitești, RO: Editura Independența Economică.
- Sîrbu, A. (2009). *Merceologie alimentară. Pâinea și alte produse de panificație*. București, RO: Editura Agir.
- Smith, J.P., Daifas, D.P., El-Khoury, W., Koukoutsis, J., El-Khoury, A. (2004). Shelf life and safety concerns of bakery products--a review. *Critical Reviews in Food Science and Nutrition*, 44(1), 19-55.
- Tăpăloagă, D. (2012). A better start in bread quality-ultra fiber and other plant ingredients. *Agrolife Scientific Journal* ,315-320.
- Willett, W.C., Sacks, F., Trichopoulou, A., Drescher, G., Ferro-Luzzi, A., Helsing, E., Trichopoulos D. (1995). Mediterranean diet pyramid: a cultural model for healthy eating. *The American Journal of Clinical Nutrition*, 61(6), 1402S–1406S.
- SR 13013-3:1994 - Cereal, milled cereal and panification products, biscuits and flour pastes. Raw protein determination
- SR 91:2007 - Bread and fresh bakery products. Methods of analysis.

EXPERIMENTAL MEDICINE

EVALUATION OF ALTERNATIVE ROUTES OF INTRAVENOUS ADMINISTRATION TO THE METHOD OF ADMINISTRATION SUBSTANCES BY PENILE VEIN IN THE *IN VIVO* ANTIGENICITY TEST IN GUINEA PIGS

Cristin COMAN¹, Teodoru SOARE², Diana ISTRATE³, Andrei STOIAN¹,
Diana ANCUȚA¹, Jasmina MANOLESCU¹

¹"Cantacuzino" National Medico-Military Institute for Research and Development, Preclinical Testing Unit, Splaiul Independentei 103, Bucharest, Romania

²University of Agronomic Sciences and Veterinary Medicine of Bucharest, Faculty of Veterinary Medicine, Splaiul Independentei 105, Bucharest, Romania

³Histovet Laboratory, Doctor Paleologu 30A Street, Bucharest, Romania

Corresponding author email: comancristin@yahoo.com

Abstract

Guinea pigs are rodents still used for scientific purposes in experimental models for tuberculosis, diphtheria, vitamin C deficiency, etc. One of the tests to which the guinea pig is widely used is the in vivo test of antigenicity. In this test, the substances are inoculated intravenously onto a previously sensitized guinea pig and analyzed whether the products tested cause anaphylactic shock. Intravenous inoculation is done, according to procedures, 2 times at 7 days in the intravenous penile vein, therefore only males are used. The purpose of the study was to evaluate intravenous inoculation methodology and welfare of guinea pigs by assessing the reaction produced after 3-way intravenous injection, penile vein, auricular vein and safenous vein, in the antigenicity test. The article describes the intravenous inoculation methodology for each route, the clinical health status assessment and the histological evaluation of the inoculated veins. The results obtained show that the safenous vein represents a safe way of intravenous inoculation, both as a technique and as side effects and histopathological lesions, and can be an alternative to the current method.

Key words: guinea pigs, histological evaluation, intravenous inoculation, inoculation technique.

INTRODUCTION

Guinea pigs are a rodent, still used in experimental studies, due in particular to their ability to replicate infectious diseases (Padilla-Carlin et al., 2008). Of that is used as an experimental model in tuberculosis and diphtheria in particular (McMurray, 1994). From their guinea pigs that do not synthesize vitamin C are used in metabolic studies respect in deficiency or excess of this vitamin (Frikke-Schmidt et al., 2011). The guinea pigs are used in toxicological studies of antigenicity by verifying that the products tested produce anaphylactic shock (Kouchi et al., 1989; Kawano et al., 1990) and also the guinea pigs has been the animal of choice for predictive sensitization tests for several decades (International Organization for Standardization, 2010).

Guinea pigs also becoming a loved and increasingly popular pet due to the fact that he

is small, easy to care and docile (Meredith, 2015). So the morphology of these veins must be known by clinicians (Stan, 2014).

In the tests listed above, but also in some cases of administration of different treatments, intravenous injections are required. This type of injections is quite difficult to do on guinea-pigs because the veins are superficial and fragile. If innovation has made many treatments to be administered subcutaneously, remain the antigenicity tests which test substances is administered intravenously and is the standard with no alternatives at this moment. The most useful method is injection into the penile vein, therefore only the male are used in this test (Takahashi et al., 1986). Other inoculation techniques described in the literature are inoculation into the auricular, saphenous and tarsian vein (Decad & Birnbaum, 1981; Hochman & Blanchard, 1983; Carraway & Gray, 1989). However, there is no analysis of the effects of inoculation on these veins and on

animals, more frequently describing techniques for blood collection from these mentioned or others veins (Hem at al., 1998; Williams & Kendall, 2015; Rodrigues et al., 2017).

This study aims was to simulate the antigenicity test by performing 2 repeated inoculations of the penile, auricular and saphenous veins of a substance undergoing the antigenicity test and the normal saline solution. The effect of inoculations was monitored by assessing animal health status, body weight evolution, necropsy examinations of animals and histopathology of inoculated veins.

MATERIALS AND METHODS

Etics statement

The study was performed in animal facility of Cantacuzino Institute, a veterinary authority accredited facility, in accordance with:

- a. Protocol study approved by the Institutional Ethics Committee of the Cantacuzino Institute and the Bucharest Veterinary Authority.
- b. Law no. 43 of 11 April 2014 on protection animals used on scientific purposes (Romanian Parliament, 2014).
- c. International Standard ISO 10993 Second Edition: 2006-07-15, "Biological Evaluation of Medical Devices - Part 2: Animal Welfare Requirements". Reference Number: ISO 10993-2: 2006 (E) (International Organization for Standardization, 2006).

Animals

Guinea pigs (*Cavia porcellus*), Dunkin Hartley strain, was provided from the animal farm of Cantacuzino Institute. 30 guinea-pigs, males and females were used, youth adult, 10–11 weeks old, weight at study initiation was between 310–335 grams. Animal identification has been marked with a permanent marker on animal fur. Animals were housed under standard laboratory conditions in an environmentally-controlled, air-conditioned room with adequate air supply (12 to 15 air changes per hour), room temperature 19°C to 22°C and relative humidity 45% to 65% with 12 hours of fluorescent light and 12 hours of dark cycle. The temperature and relative humidity were recorded once a day. Animals were housed individually in a standard polypropylene cage with a stainless steel mesh top grill having facilities for holding pelleted

feed and drinking water in a water bottle fitted with a stainless steel sipper tube. Clean wood shavings were provided as bedding material.

Guinea pigs were fed with pellet diets manufactured by Cantacuzino Institute. Food was provided *ad libitum* throughout the acclimatization and experimental period. Water was delivered in plastic water bottles with stainless steel sipper tubes *ad libitum* throughout the acclimatization and experimental period.

Acclimatization

Healthy young adult animals were acclimatized for a period of 6 days to laboratory conditions prior to beginning study and were observed for clinical signs once daily. Veterinary examination of all the animals was performed on the day of receipt and on 5th day of acclimatization.

Grouping

The animals were weighed and arranged in ascending order of their body weight. These weight-stratified guinea pigs were distributed to all experimental groups using the Microsoft Excel Spreadsheet, so that the body weight variation of the animals selected for the experiment did not exceed $\pm 20\%$ ($+ 2.96\%$ to 2.29%) of the mean body weight. The grouping was done 2 days before the initiation of study. The body weights of the animals were analyzed statistically for mean body weight to exclude the statistically significant difference between the groups. There were formed 6 groups, 2 consisting of male and 4 of female, each group consisting of 5 animals.

Study Design

The study was composed of 6 groups, G1, G2, G3, G4, G5 and G6 as it is shown in Table 1.

The study included an intravenous injection on day 1 and then on day 8. The dose was 0.2 ml / per animal/per injection. The solvent 0.9% w/v sodium chloride for injection (normal saline) was from Helvetica Profarm SA and control substance was AFLUTOP from Biotehnos Company, substance that have include in his production the antigenicity in the control test. The purpose of the study was to evaluate the intravenous inoculation methodology in guinea pigs and the welfare of the guinea pigs by assessing the reaction produced after 3-way intravenous injection by successive doses at 7 days. The reason for using both test substance and physiological serum was to quantify the lesions produced by the substance separately

from those determined by the inoculation technique and the chosen vein.

Table 1. Study groups

Groups no	Sex	Injected Substance	Intravenous veins
1	Male	Control substances	Penile vein
2	Male	Normal saline	Penile vein
3	Female	Control substances	Ear vein
4	Female	Normal saline	Ear vein
5	Female	Control substances	Saphenous vein
6	Female	Normal saline	Saphenous vein

Preparation of Animals

Intravenous injection was performed on an awake and total anesthetized animal. For anesthesia it was used a cocktail of 45 mg/kg Ketamine (Romvac Company) and 5 mg/kg Acepromazine (Romvac Company) by intra-peritoneal injection because on intramuscular injection necrosis occurs on muscular masses.

Techniques of inoculation

The following inoculation techniques were used:

The guinea pigs in lot 1 and 2 were inoculated intravenously into the penile vein as follows:

- The operator's support keeps the guinea pig upright and presses gently over the genital area to reveal the penis, thus ensuring the stasis;
- The veterinarian pulls the penis out of the foreskin and highlights the lateral penis vein;
- Inserted the needle into the vein and aspirate a little;
- Inoculated the solution.
- After inoculation, removed the needle completely and make a hemostasis for at least 15 seconds;
- The needles and syringes that were used were 27G;

The guinea pigs in lots 3 and 4 were inoculated intravenously into the auricular vein, as follows:

- The auricular vein is approached by pulling hair from the side or central ear vein;
- Local anesthesia was applied by applying an anesthetic spray (Lidocaine 10%, 1 shot, Egis Pharmaceuticals LTD);

- Applied an alcohol swab and warm the ear;
- Inserted the needle, aspirate a little, and then inject the substance;
- After inoculation needle is withdrawn completely and make hemostasis for at least 45 seconds;
- The needles and syringes that were used were 27G.

The guinea pigs in lots 5 and 6 were inoculated in the saphenous vena as follows:

- Stretched the leg and approach the saphenous vein by trimming and raised the external and internal area of the foot;
- Disinfected the place of inoculation with alcohol-soaked cotton wool and apply a stasis with a garage or hand over the place of inoculation;
- Disinfected the place of inoculation with alcohol-soaked cotton wool;
- Inserted the needle into the vein and aspire a little;
- Stacked up and inoculated;
- After inoculation, removed the needle completely and make a hemostasis for at least 45 seconds;
- The needles and syringes that were used were 27G;

Monitoring and evaluation

All animals were observed once daily for clinical signs of toxicity and twice daily for mortality. Body weight was recorded prior to initiation of the study (day 1) and at termination. After the completion of the 3 day observation period after the last inoculation, all animals were sacrificed under excessive anesthesia and subjected to necropsy and complete histopathological examination of the inoculated veins.

Histopathological examination was performed on the vein collected from all animals. The veins were collected, trimmed off any adherent tissue, as appropriate. All the mentioned veins below, all from animals, were preserved in 10% v / v Neutral Buffered formalin and embedded in paraffin wax, sectioned at 4 to 5 micrometers, stained with haematoxylin and eosin and further subjected for histopathological examination. The biological response of

inoculation, which were assessed and recorded as appropriate:

- The extent of fibrosis/fibrous capsule (layer in micrometers) and inflammation;
- The degeneration as determined by changes in tissue morphology;
- The number and distribution of the inflammatory cell types namely polymorph nuclear neutrophil leucocytes, lymphocytes, plasma cells, eosinophils, macrophages and multinucleated cells;
- The presence, extent and type of necrosis;
- Other tissue alterations such as vascularization, fatty infiltration and granuloma formation;

Statistics

Data was subjected to statistical analysis. The computer printout of the data (in the form of appendix) was verified with the original raw data. After verification, the data was subjected to statistical analysis using SPSS Software version 22.

Body weight and percent change in body weight were subjected to statistical analysis. Comparison of means between test item treatment group and predicate sample group was done using 't' test. All analysis and comparisons were evaluated at the 95% level of confidence ($P < 0.05$).

RESULTS AND DISCUSSIONS

Inoculation method

Inoculation was performed on each animal corresponding vein group. The inoculation was performed by 3 people, beginner on experiment with animals but experienced in the pet clinic. Inoculation was first performed on vigilant animals, which were then total anesthetized. For inoculation, the lateral veins of the penis, both ears and medial and lateral saphenous veins on both legs from each animal were used. The results show that the inoculation technique was learned by each practitioner after 2-3 inoculations, irrespective of the vein. Total inoculation of the inoculums was 100% in the anesthetized animal, regardless of the vein.

As inoculation features we can say:

Inoculation in the penile vein is the easiest. The vein is turgid and has a large volume. Anesthesia ensure prolapsing penis and

inoculation is easy. No lesions were observed at 7 days.

Inoculation in the auricular vein is the most complicated. The vein is on the surface, fragile, breaks gently, and the inoculated substance can penetrate subcutaneously.

As a rule, per vascular tissue is persistent. Inoculation is easier on white ear guinea-pigs, with the vein grazing slightly, but it can also be done with colored ear specimens if the hair from the ear is well removed.

The veins are not completely restored in 7 days and the alternative use of the ears is recommended.

Inoculation in saphenous vena was done in the medial and lateral vein after hair trimming and shaving of the animal's leg. The vein gets harder, even if given with alcohol.

After identifying the vein, the inoculation should take into account that the skin in the foot area is thickened and puncture the needle can penetrate the vein and a hematoma appears. Inoculation can also be done subcutaneously if it does not penetrate the vein that is sinuous.

At 7 days no injuries to the inoculated vein were observed, and the inoculation could be repeated in the same foot.

After Day 1 inoculation, hematomas were observed in the inoculated areas in 45% of guinea pigs inoculated in the auricular vein and 15% in the guinea pigs in the saphenous vena, and at day 8, 40% in the ear vein and 5% in the saphenous ven.

Figures 1-4 exemplify the above mentioned inoculation techniques.

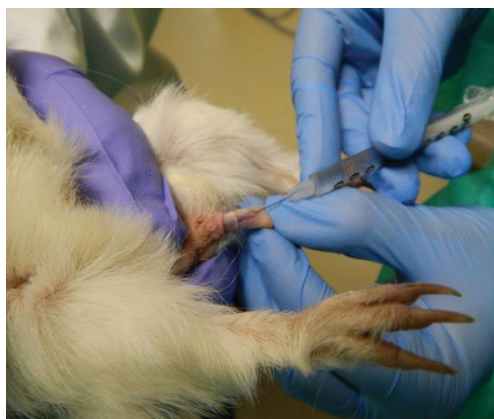

Figure 1. Guinea pig inoculated in penile vein (original photo)

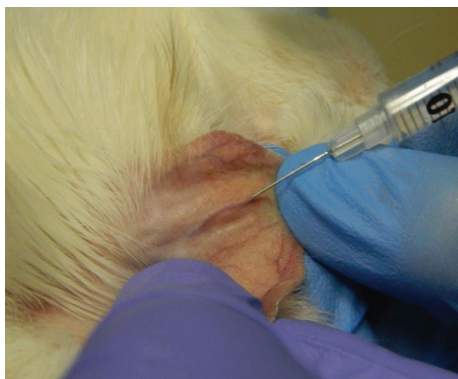

Figure 2. Guinea pig inoculated in ear vein (original photo)

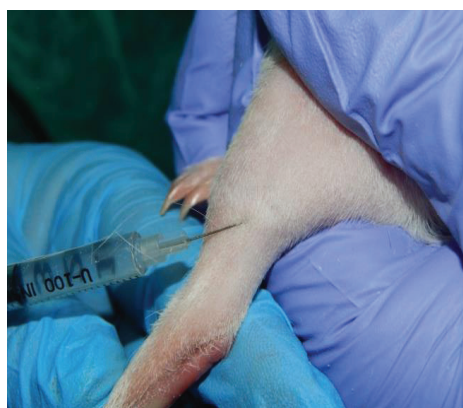

Figure 3. Guinea pig inoculated in lateral saphenous vein (original photo)

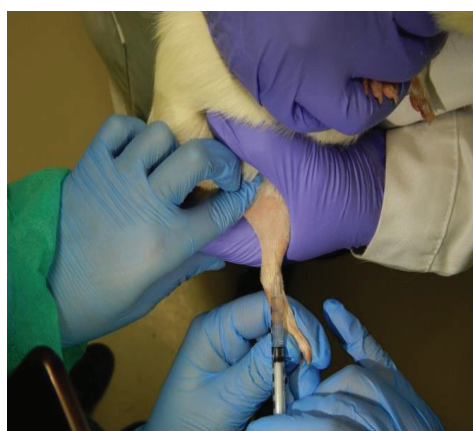


Figure 4. Guinea pig inoculated in medial saphenous vein (original photo)

Clinical Signs of Toxicity and Mortality

No clinical signs of toxicity and mortality were observed in any of the animals in all groups.

Body Weight

No inoculation related changes in body weight and percentage change in body weight with respect to day 1 were observed. All animals showed a normal physiological increase in body weights (Table 2).

Table 2 - Body weight

Group, Sex & Treatment	Injected vein	Body Weight (g) on Days		Percent Change in Body Weight with Respect to Day 1 to 7
		1	8	
		Mean	Mean	
		± SD	± SD	
G1, Male & Control substances	Penile vein	339.04	375.07	10.62
		5.93	4.14	2.05
G2, Male & normal saline	Penile vein	343.09	378.16	10.22
		4.22	0.96	4.50
G3, Female & Control substances	Ear vein	340.13	369.28	8.57
		4.50	4.22	0.96
G4, Female & Normal saline	Ear vein	333.56	368.27	11.04
		3.45	3.23	3.29
G5, Female & Control substances	Saphen vein	339.77	376.12	10.69
		5.05	5.59	0.85
G6, Female & Normal saline	Saphen vein	342.80	389.93	11.37
		4.29	5.10	0.56

Necropsy

There were no gross pathological changes observed in any of the animals.

Histological observation

The histopathological findings are presented in Table 4 and exemplified in Figures 5-10.

The lesions produced in groups 1, 3 and 5 shows that the lesions are a consequence of the action of the substance that is irritating to the veins. If the physiological serum is inoculated only in the ear veins, histopathological lesions

of inflammatory and hemorrhagic nature have been observed, which means that the auricular vein is too thin for inoculation or that the inoculation should be done with a much smaller needle. But then the inoculation time will increase.

Table 4 - Histological observation

Group, Sex & Treatment	Inoculated vein	Lesion	Animal no
G1, Male & Control substances	Penile vein	Hyperemia with inflammatory reaction	3
		Crystals in the blood vessels	1
		Presence of crystals and perivascular reaction with mixed cellularity	1
G2, Male & normal saline	Penile vein	No lesion	5
G3, Female & Control substances	Ear vein	Hyperemia with inflammatory reaction	4
		Crystals in the blood vessels	2
G4, Female & Normal saline	Ear vein	Hemorrhage , inflammatory type reactive , vessels wall interrupted	4
G5, Female & Control substances	Saphene vein	Hyperemia with inflammatory reaction	2
G6, Female & Normal saline	Saphene vein	No lesion	5

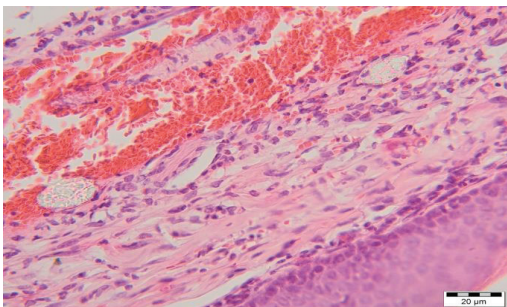


Figure 5 - Penis; guinea pig inoculated in penile vein with test substance; necrosis, secondary infection, altered vessel, perivascular inflammatory, eosinophilic, allergic reactive cells, crystals in the vessel (400×, HE)

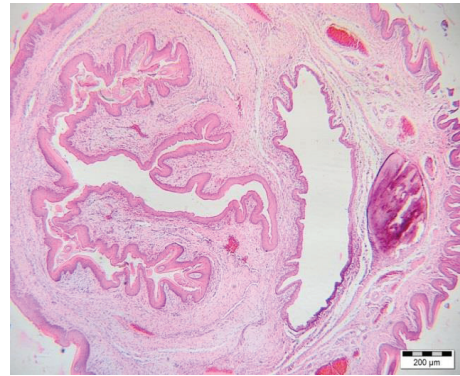


Figure 6 - Penis; guinea pig inoculated in penile vein with normal saline solution; no lesions (40×, HE)

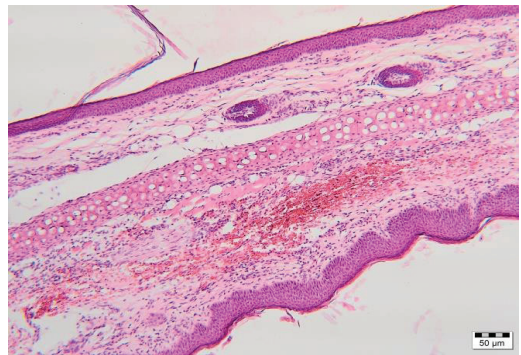


Figure 7 - Ear; Guinea pig inoculated in ear vein with normal saline solution; guinea pig inoculated in penile vein with test substance, perivascular haemorrhagic aspect with disruption of wall integrity (100×, HE)

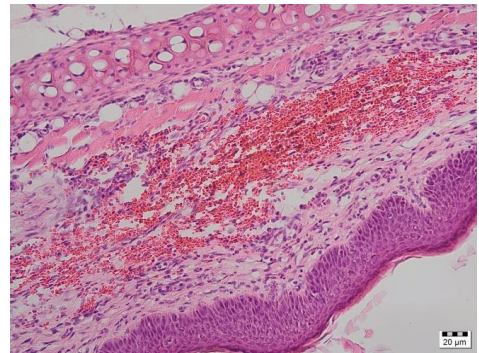


Figure 8 - Ear; Guinea pig inoculated in ear vein with test substance; broken-vessel vessel detail, hemorrhage and acute inflammatory reaction (neutrophil and active local macrophages) (200×, HE)

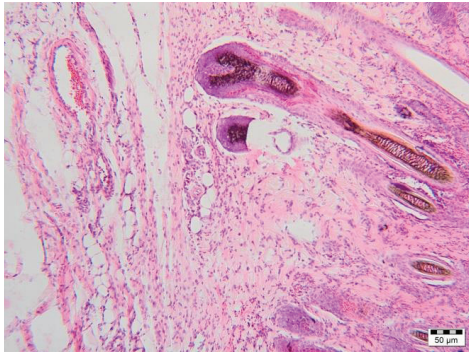


Figure 9 - Saphenous vein; Guinea pig inoculated in saphenous vein with normal saline solution; no lesions (100×, HE)

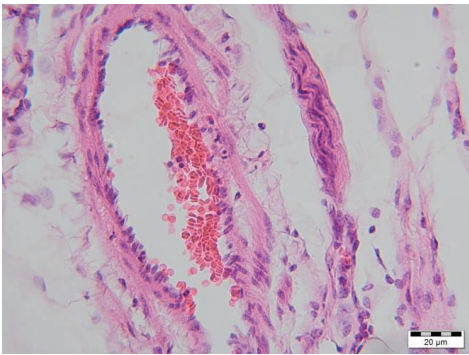


Figure 10 - Saphenous vein; Guinea pig inoculated in saphenous vein with test substance; no lesions (400×, HE)

The corroborated results show that intravenous inoculation technique in the veins accessible to guinea pigs (penile, auricular and saphenous) can be learned relatively easily. Inoculation is better for the anesthetized animal, but a firm contention can provide easy access to the inoculated veins in vigilante animal also. In case of repeated inoculations there were no changes in the weight evolution or pathological clinical signs, except for hematomas in the inoculated veins (auricular and saphenous.) Histologically, for the test substance, injuries to all veins were observed over time when inoculation with saline alone in the ear veins, lesions was observed.

Based on these results, we believe that the safenous vein may be an alternative to penile vein inoculation in antigenicity tests, so females can also be used, and animals can be relocated for other studies after the test. The safenous vena can also be used in the case of

guinea pigs used as pets for intravenous treatments.

CONCLUSIONS

In this study, clinical and histopathological effects were analyzed on 3 techniques of intravenous inoculation into the penile, auricular and saphenous vein, and the evaluation of these methods on the veins in an attempt to find an alternative to penile vein inoculation that is now practiced in the antigenicity tests.

The obtained results show that as technique and taking into account the lack of histological lesions, the saphenous vein may be an alternative to the penile vein. In this way, females can also be used in studies.

It remains that the saphenous inoculation method to be validated in the drug control laboratories to enter in the current testing.

REFERENCES

- Carraway, J. H., Gray, L. D. (1989). Blood collection and Intravenous Injection in the guinea pig via the medial saphenous vein. *Laboratory Animal Science*. 39(6), 623-4.
- Decad, G. M., Birnbaum, L. S. (1981). Noninvasive tehcnique for intravenous injection of guinea pigs. *Laboratory Animal Science*. 31 (1), 85-86.
- Frikke-Schmidt, H., Tveden-Nyborg, P., Birck, M.M., Lykkesfeldt, J. (2011). High dietary fat and cholesterol exacerbates chronic vitamin C deficiency in guinea pigs. *British Journal of Nutrition*. 105 (1), 54-61.
- Hem, A., Smith, A. J., Solberg, P. (1998). Saphenous vein puncture for blood sampling of the mouse, rat, hamster, gerbil, guinea pig, ferret and mink. *Laoratory Anima*. 32 (4), 364-368.
- Hochman, D., Blachard, J. (1983). Simplified Method for Intravenous Dosing and Serial Blood Sampling of Unanesthetized Guinea Pigs. *Journal of Pharmaceutical Science*. 72 (8), 975-976.
- International Organization for Standardization (2006). International Standard ISO 10993 Second Edition: 2006-07-15, "Biological Evaluation of Medical Devices - Part 2: Animal Welfare Requirements". *Reference Number: ISO 10993-2:2006(E)*.
- International Organization for Standardization (2010). International Standard ISO 10993 Third edition: 2010-08-01, "Biological Evaluation of Medical Devices Part 10: "Tests for Irritation and Skin Sensitization". *Reference Number: ISO 10993 - 10:2010(E)*.
- Kawano, S., Komura, H., Ohta, S., Takahashi, N. (1990). Antigenicity studies of Buspirone Hydrochloride in

- guinea-pigs and mice. *The Journal of Toxicological Sciences*, 15 (S1), 15–30.
- Kouchi, Y., Imamura, K., Izumi, K., Yoshida R. (1989). Antigenicity tests on Propiverine Hydrochloride in guinea-pigs and mice. *The Journal of Toxicological Sciences*, 14, 143–151.
- Meredith, A. (2015). Guinea pigs: common things are common. *Veterinary Record*, 177(8), 15–16.
- McMurray, D. N. (1994). Guinea Pig model of tuberculosis. In B. R. Bloom (ed.) *Tuberculosis: Pathogenesis, protection and control* (pp 67–89). Washington DC, USA: American Society for Microbiology.
- Padilla-Carlin, D., McMurray, D., Hickey, A. (2008). The guinea pig as a model of infectious diseases. *Comparative Medicine*. 58, 324–340.
- Rodrigues, M. V., de Castro S. O., de Albuquerque C. Z., Mattaraia V. G. dM., Santoro M. L. (2017). The gingival vein as a minimally traumatic site for multiple blood sampling in guinea pigs and hamsters. *PLoS ONE* 12(5): e0177967.
- Romanian Parliament (2014). Law no.43 of 2014 on protection for animals used in scientific purposes. *Official Journal*. 326, 16 – 74.
- Stan, F. (2015). Anatomical Particularities of Male Reproductive System of Guinea Pigs (*Cavia porcellus*). *Bulletin UASVM Veterinary Medicine* 72(2), 17–26.
- Takahashi, N., Kawano, S., Komura, H., Ishikawa, K. (1986). Toxicity Studies of VP 16–213 (VI) – Antigenicity in guinea pigs. *The Journal of Toxicological Sciences*, 11 (S1), 163–176.
- William, W., Kendall, L. (2015). Blood collection in the guinea pig (*Cavia porcellus*). *Laboratory Animals*. 44(6), 207–208.

ANESTHESIA COMPLICATIONS RELATED TO SWINE EXPERIMENTAL INVASIVE SURGICAL PROCEDURES

Ruxandra COSTEA, Ruxandra TUDOR, Andra DEGAN¹, Gina GÎRDAN

University of Agronomic Sciences and Veterinary Medicine of Bucharest,
59 Marasti Blvd, District 1, Bucharest, Romania

Corresponding author email: costearux@gmail.com

Abstract

The choice of anesthesia protocols for swine must take into account, besides specific characteristics, the type of surgery and the experience of the anesthetist. The anesthesia protocol used for 64 cases ensured the premises of a good surgical performance in swine procedures, while adopting correct surgical and anesthetic techniques and a continuing monitoring of the patient. Main anesthetic complications related to anesthesia for swines, according to our research were: high sensibility regarding stress factors during contention, difficult vascular access and intubation, rapid installation of hypothermia, occurrence of malignant hyperthermia while using gaseous anesthetics, anaphylaxis, regurgitation and aspiration pneumonia. Complications occurred in 20.31% of cases, ranking this species in the category of patients with high anesthetic risk for invasive surgical procedure.

Key words: anesthesia, complications, surgery, swine.

INTRODUCTION

The swine (*Sus scrofa domesticus*), is a domesticated omnivore, even-toed ungulate used for experimental procedures in various fields of surgery. In experimental invasive surgery, anesthesia protocols have to be safe, and should not influence the final results.

The aim of this study is to present the main anesthetic complications related to anesthesia in swines regarding the protocols of anesthesia. These include the preoperative patient assessment and preparation for anesthesia including the main phases from premedication through induction and maintenance for experimental invasive surgical procedures.

MATERIALS AND METHODS

This study is based on our experience of anesthesia for 64 cases (male: female ratio 1: 6). The invasive surgical procedures included training sessions for laparoscopic surgery, urology, gynecology, traumatology, thoracic surgery and liver transplantation. All specimens admitted in the study were transported and housed in optimal hygiene conditions for this species minimum 48 hours prior to procedures in order to avoid stress related to transportation or accommodation. Pigs ranged in size from 11

to 32 kg, ideal to facilitate restrain and physical restraint. Large pigs may prove dangerous and difficult to handle.

To decrease the risk of regurgitation and aspiration pneumonia, patients required fasting for 6-12 hours, because stomach content is very acid (pH 1.5-2.5). A careful preanesthetic examination was performed. Premedication targeted sedation in order to facilitate contention and venous access is necessary for the anesthetic protocol. Intravenous drug administration in adult swine is difficult to perform due to inaccessible superficial veins and thick subcutaneous fat layers (Pairis-Garcia, 2014).

After preanesthetic examination in accordance to American Society of Anesthesiologists Classification (ASA Class) cases were assigned to score I and II.

Premedication using a combination of a dissociative anaesthetic- ketamine (20 mg/kg), a benzodiazepine-midazolam 0.2 mg/kg and an α_2 agonist-xylazine (2 mg/kg) was achieved, administered intramuscularly with 20 G needles. After 20 minutes vascular access was possible and induction was achieved with Propofol (3.5 mg/kg) injected slowly intravenous (i.v.) and followed by endotracheal intubation. The anatomical particularities of the upper respiratory tract in pigs could represent a disadvantage when intubating a pig, comparing

to the other species and also comparing to human anatomy: the soft palate- *velum palatinum molle* is long and arrives to the bases of the epiglottis.

Swine intubation required experience due to anatomical features: shape of the head (dolichocephalic skull which is long and narrow), small larynx and undersized trachea are very sensible to excessive manipulation. A laryngoscope with a long, straight blade and a stilet were used to facilitate endotracheal tube passage (tube size 5, 5.5, 6, 6.5 F). The arytenoids were sprayed with 10% Lidocaine to decrease the risk of laryngeal spasm. Isoflurane in 100% oxygen was used to maintain anesthesia. The recommended minimum alveolar concentration (MAC) of 1.6-19.9 % (Malavasi et al.2008) was associated with a combination given by i.v. infusion in order to maintain anesthesia and to provide analgesia during the invasive surgical procedures: ketamine 0.5 mg/kg/h + fentanyl 3 µg/kg/h + lidocaine 0.5 mg/kg/h. Crystalloid fluids at a rate of 5-10 ml/kg/h were provided throughout the surgical procedures. Monitoring anesthesia included vital signs, evaluation of muscle relaxation, arterial blood pressure measurement, capnography, pulseoximetry, blood pH, gases and electrolytes, while swines were subject to complex interdisciplinary procedures.

RESULTS AND DISCUSSIONS

The anesthesia protocol used was the same for 64 cases of swine (*Sus scrofa domestica*) during invasive surgical experimental procedures: laparoscopic surgery (urology, gynecology, digestive procedures) - 52 cases (81.25%), conventional open techniques (classic surgery - traumatology, thoracic surgery, liver transplantation) - 12 cases (18.75%). The complications related to anesthesia, according to our study developed in 13 cases (20.31%), (laparoscopic or classic surgery) with no direct correlation with the type of the procedure (for the laparoscopic procedures - 11 incidents related to anesthesia complications and 2 for the classic procedures). In the preanesthetic period all the specimens presented sensibility during contention for clinical examination and administration of the

premedication, manifested by agitation and vocalization.

Vascular access, at the level of the auricular vein or external saphenous vein, was possible for all the cases except 2 cases for which a jugular catheter was inserted (Figure 1).

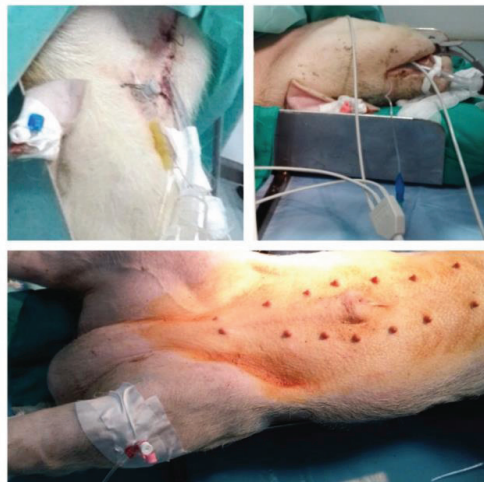

Figure 1. Vascular access: external jugular vein, auricular vein access, external saphenous access

During induction with propofol 1% lipid emulsion (3.5 mg/kg, slowly i.v.), we reported 1 case of anaphylaxis (Figure 2).

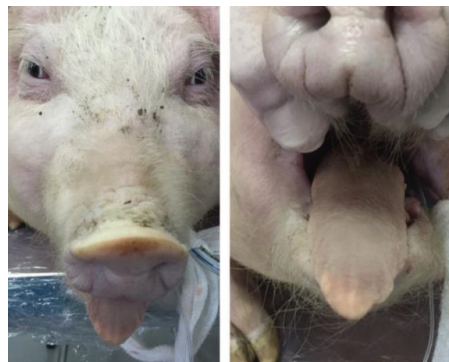

Figure 2. Anaphylaxis, 5 minutes after administration slowly i.v. of Propofol 1% lipid solution

For humans, since the propofol formulation contains both egg lecithin and soybean oil, its use is contraindicated in patients with hypersensitivities to these components. Clinicians should consider the potential for adverse drug events in patients with select food allergies (Hofer, 2003). This immediate

anaphylactic reaction after propofol i.v. administration was associated with head edema, generalised erythema, lingual edema, laryngeal edema, bradycardia and hypotension. The major difficulty during orotracheal intubation is visualisation of the swine larynx due to anatomy particularities. Pigs have thick tongues and long, narrow oropharyngeal spaces (Malavasi 2015).

The successful endotracheal intubation of pigs using the standard orotracheal method is challenging and technically difficult, because of the pig's oral anatomy and the presence of excess in tissue in the oropharyngeal region (Janiszewski, 2014).

The anesthetist, requires a good practical training in order to perform endotracheal intubation in pigs.

Some techniques are described for guiding the tube in the trachea: using a vascular catheter (Janiszewski, 2014), urinary catheter or a rigid stilet through the tube (Malavasi 2015). We used a rigid semiflexible intubating stilet (10Fr, ϕ 3.3 mm), adapted manually to secure it in the endotracheal tube during intubation (Figure 3).

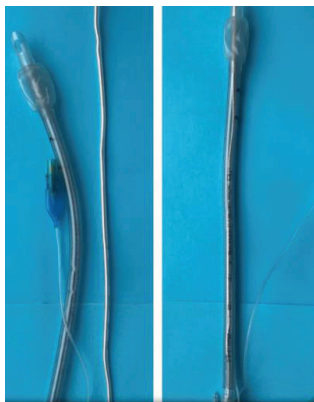


Figure 3. Rigid semiflexible intubating stilet, manually bent at one end

The laryngoscope should be introduced until the base of epiglottis, pressing the tongue. The soft palate should be lifted from the epiglottis usually with the tip of the tube or the tip of the stilet and the tube inserted under direct visualization of the larynx and vocal cords. The stilet can be first advanced in the trachea and the tube follow over it. If the tube stops at the entrance of the trachea, head and neck can be

flexed and the tube rotated around its longitudinal axis. The use of this type of guiding stilet shortened the length of the procedure and reduced the risks associated with a prolonged manipulation in the area, without any injuries.

Difficult intubation was encountered in 9 cases (14.06%), for 4 (6.25%) of them emergency tracheotomy was performed (Figure 4).

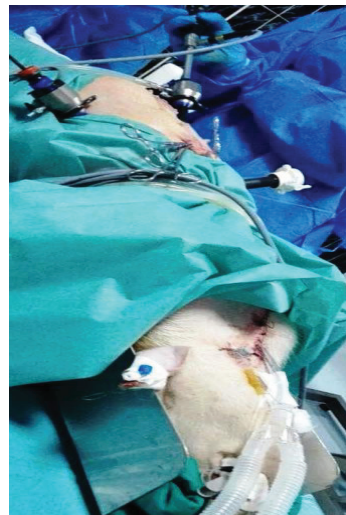

Figure 4. Emergency tracheotomy

Malignant hyperthermia is a genetic hypermetabolic syndrome in humans and pigs, being also diagnosed in other species, including dogs, horses, cats, birds, deer, and other wild animals (Malavasi 2015). Malignant hyperthermia (MH) can be triggered in swine either by stress or by certain anesthetic agents. In humans, MH commonly occurs in patients previously exposed uneventfully to triggering anesthetics. This variability in expressivity of the MH syndrome is a combination of unknown genetic and environmental factors (Nelson, 1990).

All commonly used volatile inhalational anesthetics and depolarizing skeletal muscle relaxants will initiate the MH syndrome in genetically susceptible humans and swine, but hypothermia causes a graded reduction in the potential for triggering and reduces the incidence of MH (Iaizzo, 1996).

Considering this facts during maintenance of anesthesia with isoflurane, no additional warmer devices were used and we reported 1 single case of MH (incidence of MH in this

study 1.56%). While basic and advanced monitoring was used for all the swine experimental invasive surgical procedures there were no significant variations that we can catalog as specific swine anesthesia complications. All variations were consistent with the type of anesthesia, procedure, and clinical condition of the patients.

Table 1. Complications related to anesthesia

Complications	Number of cases	Procedure's type		(%)
		Laparoscopic 52	Classic 12	
Difficult vascular access	2	2	-	3.13%
Difficult intubation/ Emergency tracheostomy	9/4	7/4	2/0	14.06 %/ 6.25%
Anaphylaxis	1	-	1	1.56%
Malignant hyperthermia	1	1	-	1.56%
TOTAL	13/64	10/52	2/12	20.31 %

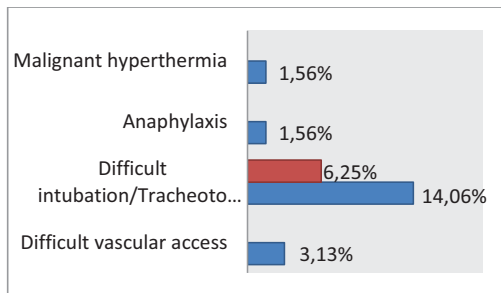


Figure 5. Distribution of complications

CONCLUSIONS

Complications occurred in 20.31% of cases, ranking this species in the category of patients

with high anesthetic risk for invasive surgical procedure.

All the specific complications occurred during the anesthesia, we did not encounter any late complications following the implementation of this protocol.

Most of the anesthetic complications were related to intubation (14.06%) and determined the modification of the anesthetic technique by carrying out the emergency tracheotomy (6.25%) and maintaining the anesthesia via the endotracheal tube connected to this level.

Complications associated with anesthesia during swine experimental invasive surgical procedures are mainly life-threatening, requiring rapid stabilization measures.

REFERENCES

- Hofer, K. N., McCarthy, M. W., Buck, M. L., & Hendrick, A. E. (2003). Possible anaphylaxis after propofol in a child with food allergy. *Annals of Pharmacotherapy*, 37(3), 398-401.
- Iaizzo, P. A., Kehler, C. H., Carr, R. J., Sessler, D. I., & Belani, K. G. (1996). Prior hypothermia attenuates malignant hyperthermia in susceptible swine. *Anesthesia & Analgesia*, 82(4), 803-809.
- Janiszewski, A., PASŁAWSKI, R., Skrzypczak, P., PASŁAWSKA, U., Szuba, A., & NICPOŃ, J. (2014). The use of a plastic guide improves the safety and reduces the duration of endotracheal intubation in the pig. *Journal of Veterinary Medical Science*, 76(10), 1317-1320.
- Malavasi, L. M. (2015). Swine. *Veterinary anesthesia and analgesia: the fifth edition of Lumb and Jones*, 928-940.
- Nelson, T. E. (1990). Porcine malignant hyperthermia: critical temperatures for in vivo and in vitro responses. *Anesthesiology*, 73(3), 449-454.
- Pairis-Garcia, M. D., Johnson, A. K., Bates, J. L., Stock, M. L., Barth, L. A., Brommel, A. S., ... & Karriker, L. A. (2014). Development and refinement of a technique for short-term intravascular auricular vein catheter placement in mature sows. *Laboratory animals*, 48(1), 78-81.

RESEARCH REGARDING THE EFFECT OF SOME SYNTHETIC GLUCOCORTICOID HORMONES ON LEUKOCYTES, IN RATS

Gavrilă ZAGRAI¹, Cristian BELU¹, Cerasela VASILESCU¹, Diana LICSandRU¹,
Aurel DAMIAN², Ana Maria ZAGRAI (MAIEREAN)², Livia PĂUN¹

¹Faculty of Veterinary Medicine, University of Agronomic Sciences and Veterinary Medicine of Bucharest, Romania

²Faculty of Veterinary Medicine, University of Agricultural Sciences and Veterinary Medicine of Cluj-Napoca, Romania

Corresponding author email: gavrilazag@yahoo.com

Abstract

In this paper, the assessment is to investigate the effect of some synthetic glucocorticoid hormones (used frequently in therapy) on leukocytes (WBC and leukocyte formula), in rats. It is mentioned that the hormones used in this study (Prednisone, Dexamethasone and Betamethasone) have a large utilization in therapy due to the anti-inflammatory effect, overlooking in many cases the immunosuppressive effect. The determinations regarding the number of leukocytes and the leukocyte formula have been made using the IDEEX Analyzer, at the beginning and at the end of the experiment. As a result of the analysis it was revealed that the WBC%, at the end of the experiment, was higher, for all the experimental groups, comparing with the control group. After the interpretation of the obtained results regarding to the values of the leukocyte formula in the case of the experimental groups, it was shown increases of the percentages of neutrophils and basophils, decreases of percentages of eosinophils, lymphocytes and monocytes, comparing to the values obtained for the control group.

Key words: leukocytes, glucocorticoid hormones, rat, leukocyte formula.

INTRODUCTION

This research paper aims to elucidate the effects produced on leukocytes of some solutions that have synthetic glucocorticoid hormones as active substance. Currently, these preparations are used extensively in veterinary medicine, often without taking into account the adverse effects. In our study, we had in view the effect of these hormones on both the total leucocyte count and the different leukocyte categories (effect observed by changes in leukocyte formula).

By studying the literature in the field (Cotor G. et al., 2014; Codreanu I., 2018), we noticed that treatments with such products may increase the present chronic diseases, thus limiting the chances of success in some cases.

It is also known that the synthesis of glucocorticoid hormones intensifies in all stress states (Cotor G. et al., 2012), which is an aggravating factor in the subsequent evolution of the pathologic process. Thus, the emphasis on symptomatic medication has the immunosuppressive effect (Cotor G. et al,

2006), as main disadvantage and also the possible systemic effects of synthetic glucocorticoid hormones.

The present paper aims to demonstrate the effects of these hormones in blood in rats, one of the most used species regarding the researches (Codreanu I., 2011).

We consider our study to be important because the hormones we take into account have a wide use in the clinic (often their use is exaggerated) and the doctors do not give importance to the effect on the leukocytes. These effects may have serious repercussions on animal health, mainly due to the immunosuppressive effect (Cotor G. et al., 2014).

MATERIALS AND METHODS

The materials used for this study were rats, blood analyzer, drugs, syringes, needles, blood harvesting tubes, etc.

The biological material consisted of laboratory rats from the Wistar line, which were divided into 4 lots (10 rats per lot), a control group and three experimental lots.

In our study, we used several synthetic glucocorticoid hormones contained in the following drugs: Prednisol (1 ml contains: Prednisolon acetat 25 mg, Benzyl alcohol 9 mg., Sodium chloride 8 mg., Carboxymethylcellulose sodium 3 mg., Polysorbate 80 mg.), Colvasone (1 ml contains: Dexamethasone disodium phosphate 2 mg and Benzyl Alcohol - preservative 20 mg) and Diprophos (1 ml contains: Betamethasone dipropionate, the equivalent of 5 mg of betamethasone and Betamethasone sodium phosphate, the equivalent of 2 mg of betamethasone).

The rats have been administered for 7 days in this way: physiological serum (control group), Prednisol (1st experimental group), Colvasone (2nd experimental group), Diprophos (3rd experimental group).

After two weeks (the period time that rats required to adapt to new living conditions), the rats were weighed (average weight was about 250 grams) in order to calculate the amount of substance (glucocorticoid hormone) that would be administered.

The rats have been administered for 7 days in this way: 0.3 ml physiological serum (control group), 1mg/kg Prednisolon - Prednisol (1st experimental group), 1 mg/kg Dexamethasone - Colvasone (2nd experimental group), 1 mg/kg Betamethasone - Diprophos (3rd experimental group). One day after the last administration, there were collected blood samples and were determined the leukocyte count and leukocyte formula.

RESULTS AND DISCUSSIONS

The results obtained (number of leukocytes and leukocyte formula) will be presented in the following tables (average values for each lot) and figures accompanied by explanatory comments.

The comparisons regarding the statistical relevance of the differences between the experimental groups were made using the t test (Student).

The results obtained by the point of view of white blood cell count for the control group and the experimental groups at the end of the experiment are presented in Table 1 and Figure 1.

Table 1. The mean WBC values for the control and the 3 experimental lots

Lot category	WBC (thousands/mm ³ blood)
Control group	10.18
1 st group	10.62
2 nd group	12.18*
3 rd group	12.94*

*P<0.05

Based on the statistical analysis it was found that between the WBC values recorded at the end of the experiment for the control group and for the 3 experimental groups there are the following significant differences (P<0.05):

- the discussed parameter is higher in the case of the Prednisolone group with 4.32% compared to the control group;
- the discussed parameter is higher for the Dexamethasone treated group with 19.64% compared to the control group;
- the discussed parameter is higher for the Betamethasone treated group with 27.11% compared to the control group.

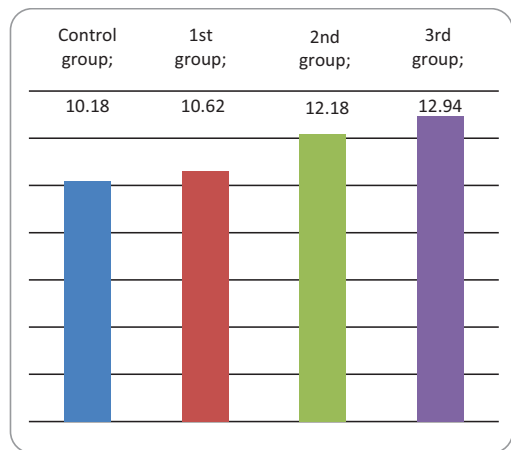


Figure 1. Comparative chart of the WBC for the control group and the 3 experimental groups

The data obtained by us falls within the values mentioned by the literature in the field (Cotor G. et al, 2014). Concerning the effect of synthetic glucocorticoid hormones on WBC, our results show an increase in this parameter, which is also highlighted by other researchers (Ghiță M. et al., 2015). This increase is attributed to neutrophils and basophils as follows. These results were reported by other

authors (Găjăilă G. et al., 2016; Medina-Martel M. et al., 2013).

The results obtained regarding the values of the leucocyte formula recorded in the rats in the control group and the rats in the 3 experimental groups at the end of the experiment are presented in Table 2 and Figure 2.

Table 2. Avarage weight of different leucocyte categories in the leucocyte formula in the control lot and experimental lot

Lot category	N (%)	E (%)	B (%)	L (%)	M (%)
Control group	33.4	2.8	0.4	59.8	3.6
1 st group	36.8*	2*	0.4	57.2*	3.6
2 nd group	38*	1.6*	0.6*	56.6*	3.2*
3 rd group	40.6*	1.6 *	0.6*	54*	3.2*

(N-neutrophils, E- eosinophils, B-basophils, L-lymphocytes, M-monocytes)

From the statistical analysis of the results obtained regarding the determination of the leucocyte formula for the groups treated with glucocorticoid hormones, compared to the control group, significant differences were observed which will be presented below for each category of leukocytes.

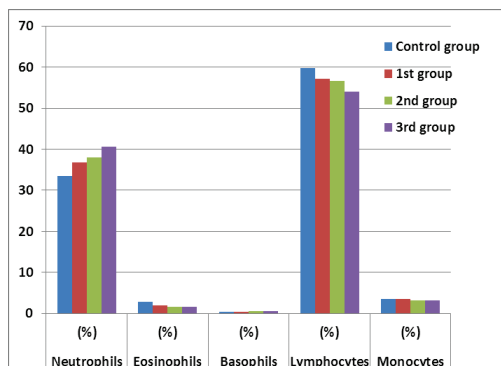


Figure 2. Comparative graph of each leukocyte group within the leucocyte formula for the control group and the 3 experimental groups

Concerning the leukocyte formula were found the following:

- the percentage of neutrophils was higher for all the experimental groups, the increases being of 10.17% (1st experimental group), 13.77% (2nd experimental group) and of 21.55% (3rd

experimental group), comparing to the control group.

- the percentage of the eosinophils was lower for all the experimental groups, the values being of 28.57% (1st experimental group) and of 42.85% (2nd experimental group *P<0.05 and the 3rd experimental group), comparing to the control group.

- the percentage of the basophils was increased by 50% comparing to the control group, for all the experimental groups.

- the percentage of the lymphocytes was decreased by 4.34% (1st experimental group) 3.67% (2nd experimental grope) and of 9.69% (3rd experimental group), comparing to the control group.

- the percentage of the monocytes was lowered by 11.11%, comparing to the control group, for all experimental groups.

Our obtained data confirms the results of other authors (Gotor G. et al., 2014; Ghiță M. et al., 2015; Găjăilă G. et al., 2014). A particular aspect of our study is that besides the neutrophils, in the leukocyte formula the basophils are also high. We also found a relationship of direct proportionality between the amount of changed leukocyte in the leukocyte formula and the hormone product retention in the animal body.

CONCLUSIONS

Following the statistical analysis of the results obtained, the following conclusions can be drawn:

1. Prednisolone caused a significant increase of WBC and neutrophil percentage and significant decrease of lymphocyte and eosinophil percentages compared to the control group.
2. Dexamethasone caused a significant increase of WBC, neutrophil count and basophil count and a significant decrease of eosinophil, lymphocyte and monocyte counts compared to the control group.
3. Betamethasone caused significant increase of WBC, neutrophil and basophil percentages and significant decrease of eosinophil, lymphocyte and monocyte counts compared to the control group.

REFERENCES

Codeleanu Iuliana (2011). Biologia animalelor de laborator, Ed. Printech, București

- Codreanu Iuliana (2018). Animal physiology, Ed. Printech, București
- Cotor G., Ghiță M. (2006). Biologia producțiilor animaliere cu relevanță alimentară, Ed. Cartea Universitară, București
- Cotor G., Ghiță M. (2012). Noțiuni teoretice și practice de biologie animală, Ed. Printech, București
- Cotor G., Ghiță M. (2014). Fiziopatologia specială a animalelor domestice, Ed. Printech, București
- Cotor G., Gajaila G., Dobrea M., Gajaila I. (2014). The effect of overpopulation on neutrophil/lymphocyte ratio and WBC values, in normal and propranolol treated rats. Bulletin of University of Agricultural Sciences and Veterinary Medicine Cluj-Napoca. Veterinary Medicine Vol.71 No.1
- Ghiță M., Cotor G., Vițălaru A., Brăslășu Daniela (2015). Comparative study on the effect of prednisone and dexamethasone on leukocytes, in rabbit. Journal of Biotechnology, 208, S92
- Găjăilă G., Găjăilă I., Cotor G., Ioniță L. (2016). Testing the killing ability of pig neutrophils after stimulation with an ethanolamine derivative, Journal of Biotechnology, 231, S71
- Găjăilă G., Cotor G., Găjăilă I. (2014). Evaluation of the level selection and functional maturation of the T cells in the blood of pigs, depending on age of the animal. Bulletin of University of Agricultural Sciences and Veterinary Medicine Cluj-Napoca, Volume 71, p.59-61
- Medina-Martel M, Urbina M, Fazzino F, Lima L. (2013). Serotonin transporter in lymphocytes of rats exposed to physical restraint stress. Neuroimmunomodulation. 2013; 20(6):361-7